

# EAHP2018

19<sup>th</sup> MEETING OF THE EUROPEAN ASSOCIATION FOR HAEMATOPATHOLOGY



Picture credit: © surangaw - Fotolia.com

**BOOK OF ABSTRACTS**

Edinburgh, Scotland, UK  
29 September – 4 October 2018

[www.eahp-sh2018.com](http://www.eahp-sh2018.com)

When abstracts are quoted the following information must be included:

Abstract title

Abstract number

Abstract author name(s)

Source: 19th Meeting of the European Association for Haematopathology -

EAHP 2018 - Abstracts - Edinburgh,

September 29 - October 4 2018

URN:

# EAHP2018

19<sup>th</sup> MEETING OF THE EUROPEAN ASSOCIATION FOR HAEMATOPATHOLOGY

## **BOOK OF ABSTRACTS**

Edinburgh, Scotland, UK  
29 September – 4 October 2018

[www.eahp-sh2018.com](http://www.eahp-sh2018.com)

# COMMITTEES

## Chair, Local Organizing Committee

John GOODLAD  
Department of Pathology, Level 3  
Laboratory Medicine Building  
Queen Elizabeth University Hospital  
1345 Govan Road | Glasgow, G51 4TF

## Executive Committee

Dan ARBER, United States  
Christiane COPIE-BERGMAN, France  
Daphne de JONG, The Netherlands  
Stephan DIRNHOFER, Switzerland  
Falko FEND, Germany  
John GOODLAD, United Kingdom  
Margarita GUENOVA, Bulgaria  
Marja-Liisa KARJALAINEN-LINDSBERG, Finland  
Santiago Montes MORENO, Spain  
German OTT, Germany  
Maurilio PONZONI, Italy  
Leticia QUINTANILLA DE FEND, Germany  
Birgitta SANDER, Sweden  
Andrew WOTHERSPOON, United Kingdom

## Lymphoma Workshop Panel Members

Maria CALAMINICI, United Kingdom  
Snjezana DOTLIC, Croatia  
Judith FERRY, United States  
John GOODLAD, United Kingdom  
Rebecca KING, United States  
Santiago Montes MORENO, Spain  
Ilske OSCHLIES, Germany  
German TTt, Germany  
Maurilio PONZONI, Italy  
Alexandra TRAVERSE-GLEHEN, France

## Bone Marrow Workshop Panel Members

Dan ARBER, United States  
Ayoma ATTYGALLE, United Kingdom  
Falko FEND, Germany  
Peter JOHNSTON, United Kingdom  
Camille LAURENT, France  
Alberto ZAMO, Italy

# CONTENTS

## Bone Marrow Symposium

### I. Oral Presentations (BMWS-O-1 – BMWS-O-4)

- 14 BMWS-O-1 Bone marrow infiltration of angioimmunoblastic T-cell lymphoma: morphologic patterns and ancillary phenotypic analyses
- 15 BMWS-O-2 The oncogenic role of IGF1R mutations in multiple myeloma
- 15 BMWS-O-3 RUNX1 mutations can lead to aberrant expression of CD79a and PAX5 in acute myelogenous leukemias: a potential diagnostic pitfall
- 16 BMWS-O-4 Myeloid Neoplasms Arising in Chronic Lymphocytic Leukemia or Other Indolent B-Cell lymphomas in Bone Marrow: An intrinsic Predisposition due to altered Microenvironment or a Therapy-Related direct genetic Insult?

### II. Poster Presentations (BMWS-P-1 – BMWS-P-21)

- 20 BMWS-P-1 Mixed-phenotype acute leukemia (B-/myeloid) with BCR-ABL1 like alteration
- 21 BMWS-P-2 Blastic Plasmacytoid Dendritic Cell Neoplasm: genomics mark epigenetic dysregulation as a primary therapeutic target
- 21 BMWS-P-3 Impact of Clinicopathologic Factors on Overall Survival in Bone Marrow Involvement by Diffuse Large B Cell Lymphoma: Indian Scenario
- 22 BMWS-P-4 Primary bone marrow large B cell lymphoma is more often associated with hemophagocytic syndrome, cytogenetic abnormalities and less 1-year-survival rate than the diffuse large B cell lymphoma with secondary marrow involvement
- 23 BMWS-P-5 CD56 expression in myeloid neoplasias with excess of blasts is accompanied by significant numeric underestimation of blasts on bone marrow aspirates compared to bone marrow biopsies
- 24 BMWS-P-6 Primary Bone Marrow Burkitt Leukemia
- 25 BMWS-P-7 Hodgkin lymphoma with marrow involvement as presenting feature
- 26 BMWS-P-8 Clinical and Laboratory Characteristics of IgA Plasma Cell Neoplasms
- 26 BMWS-P-9 Bone Marrow Involvement by Different Lymphomas
- 28 BMWS-P-10 Bone marrow presentation of T-cell lymphoma in two patients with chronic lymphocytic leukemia
- 28 BMWS-P-11 Finding the incidence of Mucormycosis in Hodgkin Lymphoma Patients with undergoing Bone Marrow Transplantation
- 29 BMWS-P-12 The bone marrow involvement in classic Hodgkin lymphoma – a five-year study in a single institute

- 30 BMWS-P-13 Differences in the Hodgkin lymphoma microenvironment between lymph node and bone marrow
- 31 BMWS-P-14 Lymphoplasmocytic lymphoma and polycythemia vera: a case of rare co-occurrence, both contributing to clinical hyperviscosity syndrome
- 32 BMWS-P-15 Bone marrow biopsy as the only specimen for diagnosis of transformation of splenic marginal zone lymphoma to Burkitt lymphoma
- 33 BMWS-P-16 Bone marrow presentation of T-cell/ histiocytic large B-cell lymphoma
- 34 BMWS-P-17 A challenging case of Hodgkin lymphoma with primary presentation as bone marrow infiltrates
- 35 BMWS-P-18 Monoclonal plasmacytosis in bone marrow biopsy as a initial presentation of acute myeloid leukaemia
- 36 BMWS-P-19 Diffuse large B-cell lymphoma with primary involvement of the bone marrow presenting with cold agglutinin disease. A case report.
- 37 BMWS-P-20 Ki-67 in primary myelofibrosis: proliferative activity of megakaryocytes
- 37 BMWS-P-21 Necrotizing lymphadenopathy with prominent Azzopradi effect in autoimmune disorder possible

## Lymphoma Symposium

### I. Oral Presentations (LYS-O-1-1 – LYS-O-7-4)

- 42 LYS-O-1-1 Novel GPR34 and CCR6 mutation and distinct genetic profiles in MALT lymphomas of different
- 43 LYS-O-1-2 High-throughput sequencing of nodal marginal zone lymphomas identifies recurrent BRAF mutations
- 44 LYS-O-1-3 Clonality assessment of disseminated malt lymphoma.
- 45 LYS-O-1-4 Primary CNS Small B-cell Neoplasms
- 46 LYS-O-2-1 DLBcl: microenvironmental signature along with coo identifies different risk groups
- 47 LYS-O-2-2 PDL1 and PDL2 expression in primary diffuse large B cell lymphoma (DLBCL) of the CNS
- 49 LYS-O-2-3 The tumor microenvironment in Primary Central Nervous System Lymphoma
- 49 LYS-O-2-4 The microenvironmental landscape of extranodal natural killer/T-cell lymphoma
- 50 LYS-O-3-1 Mutational landscape of extranodal NK/T-cell lymphoma, nasal type from Latin America.
- 52 LYS-O-3-2 NKp46 is a useful diagnostic biomarker in gastrointestinal T-cell lymphoproliferative diseases and constitutes a therapeutic target. A CELAC network study.
- 53 LYS-O-3-3 Angioimmunoblastic T-cell lymphoma contains multiple clonal T-cell populations derived from a common TET2 mutant progenitor cell
- 54 LYS-O-3-4 Angio-Immunoblastic T-cell Lymphoma and Chronic Myelomonocytic Leukemia: a non-fortuitous association arising from precursor hematopoietic cells with acquired TET2 mutations

- 55 LYS-O-4-1 Gene Expression Profile distinguishes Breast Implant-Associated Anaplastic Large Cell Lymphoma from other Peripheral T-cell Lymphomas
- 56 LYS-O-4-2 The role of PD-1 and PD-L1 in T-cell immune suppression in patients with primary testicular diffuse large B-cell lymphoma (PT-DLBCL)
- 57 LYS-O-4-3 Next generation sequencing of vitreoretinal B-cell lymphoma reveals a mutational landscape similar to primary central nervous system lymphoma and facilitates diagnosis
- 58 LYS-O-5-1 Localized low-stage follicular lymphomas exhibit distinct biological/genetic features
- 59 LYS-O-5-2 Frequency of potential N-glycosylation sites in t (14;18)-positive and negative low and high stage follicular lymphoma
- 60 LYS-O-5-3 Reproducibility of MYC protein expression scoring and impact on the prognosis of aggressive B-cell lymphoma patients
- 61 LYS-O-5-4 Mutations analysis as an aid to separate diffuse large B-cell lymphoma subgroups according to the cell of origin
- 62 LYS-O-5-5 Engagement of RelA, cRel or RelB NF- $\kappa$ B subunit activation impacts on classification and prognosis of diffuse Large B-cell lymphoma
- 63 LYS-O-6-1 THRLBCL immune transcriptomic profile displays high expression of inhibitory receptors and tolerogenic molecules
- 64 LYS-O-6-2 JUNB, DUSP2, SGK1, CREBBP and SOCS1 are frequently mutated in T-cell/histiocyte rich large B-cell lymphoma
- 64 LYS-O-6-3 FBXO11 is a frequently mutated oncosuppressor in Burkitt Lymphoma
- 65 LYS-O-6-4 Burkitt-like lymphoma with 11q aberration: A germinal center derived lymphoma without ID3-TCF3-CCND3 pathway deregulation
- 66 LYS-O-7-1 Simultaneous analysis of mutations, translocations and copy number aberrations in B-cell Non-Hodgkin Lymphomas using an "All-in-One Next-Generation Sequencing Assay"
- 67 LYS-O-7-2 Use of T cell-specific RNA in situ hybridisation as a novel test to distinguish malignant (lymphomatous) and benign (inflammatory) T cell infiltrates
- 68 LYS-O-7-3 MiR-146a target gene CD147 regulates energy metabolism and promotes tumor growth, angiogenesis and invasion of ALK+ ALCL
- 69 LYS-O-7-4 Genetic evolution of clonally related in situ follicular neoplasia to diffuse large B-cell lymphoma of germinal center subtype

## II. Poster Presentations (LYS-P-2 – LYS-P-98)

- 74 LYS-P-2 Epstein - Barr virus leaves its mark: new evidence for „hit and run“ hypothesis from non-conventional methods
- 75 LYS-P-3 Screening for prognostic molecular signatures in symptomatic follicular lymphoma patients treated without chemotherapy
- 76 LYS-P-4 Validation of the MCL35 gene expression proliferation assay in randomized trials of the European Mantle Cell Lymphoma Network

- 77 LYS-P-5 MYC translocation positive diffuse large B-cell lymphoma has a distinct mutational spectrum
- 78 LYS-P-6 Myc-related micrnas signatures in non-hodgkin b-cell lymphomas and their relationships with core cellular pathways
- 79 LYS-P-7 CDKN2A alteration in PTCL with a TFH phenotype: a recurrent event that could confer a sensitivity to MDM2 inhibitors
- 80 LYS-P-8 Histiocytic neoplasms with myeloid neoplasm-associated genetic alterations suggest hematopoietic stem cells as a cell of origin
- 82 LYS-P-9 TP53 mutations are enriched in Mantle cell lymphoma with negative and low SOX11 expression demonstrated by in situ hybridization assay for quantification of SOX11 mRNA expression
- 83 LYS-P-10 Post-transcriptional modifications of small RNAs as prediction signatures for response to R-CHOP treatment in Diffuse Large B-cell Lymphoma
- 84 LYS-P-11 MHC class II transactivator (CIITA) abnormalities are frequent in B-cell lineage lymphomas and are associated with loss of MHC Class II (MHCII) expression.
- 85 LYS-P-12 In situ follicular neoplasia lacks activation-induced cytidine deaminase
- 86 LYS-P-13 Mutation screening using formalin-fixed paraffin-embedded tissues: a stratified approach according to DNA quality
- 87 LYS-P-14 The immune landscape of Burkitt lymphoma: dysfunctional T-cells phenotype and M2-macrophages polarization
- 88 LYS-P-15 RNA-SEQ studies in primary intestinal T-cell lymphomas.
- 89 LYS-P-16 Epstein Barr virus positive mucocutaneous ulcer and classical Hodgkin Lymphoma share similar immune microenvironmental features.
- 90 LYS-P-17 Combined effects of MYC and EBV on lipid metabolism in aggressive B-cell lymphomas
- 91 LYS-P-18 Prognostic impact of MYC, BCL2 and/or BCL6 rearrangements status in large B cell lymphoma
- 92 LYS-P-19 Targeted deep sequencing of gastric marginal zone lymphoma identified alterations of TRAF3 and TNFAIP3 that were mutually exclusive for MALT1 rearrangement
- 93 LYS-P-20 DNA methylation analysis on paraffin embedded tissue as a new tool for the differential diagnosis between T-Lymphoblastic Lymphoma (T-LBL) and lymphocyte-rich thymoma
- 94 LYS-P-21 Clinico-pathological and molecular heterogeneity of breast-implant lymphomas
- 95 LYS-P-22 Integrated analysis of signal transducers and activators of transcription 3 (STAT3) associated factors in diffuse large B-cell lymphoma
- 96 LYS-P-23 Activated signal transducers and activators of transcription (STAT3) in adult T cell leukemia/lymphoma and its association with disease subtypes and clinical findings
- 97 LYS-P-24 Engineered bioluminescent 3D lymphoma avatars for targeted therapy
- 98 LYS-P-25 Transformation of follicular lymphoma to Epstein Barr virus positive diffuse large b-cell lymphoma: a case report and review of the literature
- 99 LYS-P-26 Comprehensive analysis of Follicular Lymphoma evolution based on immunoglobulin variable region gene sequences reveal acquisition of N-glycosylation motifs is an early and stable event in pathology
- 100 LYS-P-27 Clinicopathologic Features of Lymphoma in Spinal Epidural Space

- 101 LYS-P-28 MYC gene alterations and not BRAF and MAPK mutations are common features in dendritic cell neoplasms
- 102 LYS-P-29 Double hit lymphoma identification and characterization in routine practice
- 103 LYS-P-30 Clinicopathologic characteristics and novel biomarkers of aggressive B-cell lymphomas in the nasopharynx
- 103 LYS-P-31 Burkitt-like lymphoma with 11q aberration is not uncommon in children
- 104 LYS-P-32 Impact of Sox11 overexpression in Ba/F3 cells
- 105 LYS-P-33 Expression of P63 and absence of GATA3 are useful surrogate markers to differentiate primary mediastinal large B-cell lymphoma from classic Hodgkin lymphoma
- 106 LYS-P-34 Contribution of immunoglobulin lambda light chain gene rearrangement analysis in the diagnosis of lymphoproliferative disorders
- 108 LYS-P-35 Tumor Microenvironment in Anaplastic Large Cell Lymphoma: The role of CD8+, FOXP3 regulatory T cells, CD8/FOXP3 ratio and PD-L1 expression
- 109 LYS-P-36 The spectrum of findings in patients presenting with extranodal marginal zone B cell lymphoid proliferations of mucosa associated lymphoid tissue (MALT) in the recto-colonic mucosa
- 110 LYS-P-37 Mycosis Fungoides in Taiwan shows a relatively high frequency of large cell transformation and CD56 expression
- 110 LYS-P-38 Diagnostic yield of nerve biopsy in neurolymphomatosis: pathology and PCR-based clonality testing. A serie of 15 cases.
- 111 LYS-P-39 WHO Classification of Malignant lymphomas in Korea: Report of the 4th nationwide study
- 112 LYS-P-40 Hypoxia and the immune microenvironment of DLBCL: HIF1a, HIF2a, and PDL1 immunohistochemical expression and clinical outcome analysis
- 113 LYS-P-41 Cutaneous B-Cell Lymphoma: A Retrospective Clinicopathological Evaluation of 92 Cases
- 114 LYS-P-42 Frequency of high-grade B cell lymphomas with diffuse large B cell morphology detected by FISH study (MYC,BCL2,BCL6) with relevance of double-expressor or non double-expressor phenotype. A clinical-pathological correlation in 210 Mexican cases
- 115 LYS-P-43 Mutational analysis using NGS shows frequent targetable mutations in double-hit and triple-hit high grade B cell lymphoma (HGBL) and detects tfnfp3 mutations in transformed cases
- 116 LYS-P-44 Incidence of Hodgkin and non-Hodgkin lymphoma in HIV positive patients. High incidence of Epstein Barr virus coinfection in a Mexican population.
- 118 LYS-P-45 Diagnostic Utility of LMO2 and CD38 as an Immunohistochemical Panel in Distinguishing Burkitt lymphoma from other aggressive B cell lymphomas.
- 118 LYS-P-46 Comparison of the Lymph2Cx assay and Hans algorithm in determining the Cell-Of-Origin of diffuse large B-cell lymphomas
- 119 LYS-P-47 CD30-expression in neoplastic T cells of follicular T-cell lymphoma is a helpful diagnostic tool in the differential diagnosis to Hodgkin lymphoma
- 120 LYS-P-48 Primary gastrointestinal lymphomas: A four year study of 152 cases from a tertiary cancer centre in South India
- 121 LYS-P-49 The Contribution and Role of Clonality Studies in the Diagnosis of Lymphoproliferative Disorders – A Tertiary-Centre’s Experience

- 122 LYS-P-50 Leukemic presentation of small cell variant of ALK+ALCL with a novel partner PABPC1, responding to single-agent crizotinib treatment.
- 123 LYS-P-51 Peripheral T-cell lymphoma, NOS: Prognostic value of the association with infection EBV in Peruvian Poblacion
- 124 LYS-P-52 PD-1 and PD-L1 expression in a small series of cases within the spectrum of CD30 positive cutaneous lymphoproliferative disorders
- 125 LYS-P-53 Prognostic value of PD-L1 expression and EBV association in patients with primary intestinal diffuse large B-cell lymphoma
- 126 LYS-P-54 The role of activated stromal cells in onset of inflammation associated lymphoma: a case report
- 127 LYS-P-55 Adaptation to hypoxia is marked by carbonic anhydrase IX expression in Hodgkin-Reed-Sternberg-cells and is associated with unfavourable response to therapy in classical Hodgkin's lymphoma
- 128 LYS-P-56 Cytokeratin-positive fibroblastic reticular cell tumor with focal follicular dendritic cell features: A case report
- 128 LYS-P-57 Primary extranodal lymphomas in Kerala, South India
- 129 LYS-P-58 Lymphomas of the gut: 18 years' experience on 103 cases
- 130 LYS-P-59 Myc expression in primary central nervous system lymphoma
- 131 LYS-P-60 Clinicopathologic comparison of initial versus secondary hematology lymphoid malignant diagnosis made on effusion samples
- 132 LYS-P-61 Identifying the nature of Perforation in patients diagnosed with Gastrointestinal Lymphoma. Do we need early interventions?
- 132 LYS-P-62 Primary classical Hodgkin lymphoma of the skin, a case report
- 133 LYS-P-63 Primary extranodal non-Hodgkin lymphoma in the North-Western region of Romania: clinicopathological features and survival.
- 134 LYS-P-64 Clinicopathologic analysis of splenic lymphoma: Three year experience
- 135 LYS-P-65 Primary classic Hodgkin Lymphoma in unusual sites
- 136 LYS-P-66 Risk of malignant neoplasms of blood and lymphatic system of liquidators of the Chernobyl accident in Belarus
- 137 LYS-P-67 Identifying the types of Non-hodgkin Lymphoma
- 137 LYS-P-68 NFATc1 and tumor micro environment in diffuse large B cell lymphoma
- 138 LYS-P-69 Presence of Epstein-Barr Virus and Lack of Existence of Simian Virus 40 Deoxyribonucleic Acid Sequences in Paraffin Embedded Tissue of Diffuse Large B cell Lymphoma Cases in Yogyakarta Indonesia
- 139 LYS-P-70 Gluteal-implant associated anaplastic large cell lymphoma: a case report and proposal for a new terminology
- 140 LYS-P-71 Cyclin D1 expression in lymphoproliferative neoplasms by flow cytometry and immunohistochemistry
- 140 LYS-P-72 Evaluation of the Role of Interleukin-6 and Hcpidin in Anemia in Patients with Lymphoma
- 141 LYS-P-73 The expression of Human Telomerase Reverse Transcriptase gene and its activity in patients with B-Cell chronic lymphocytic leukemia and its impact on clinical staging.
- 142 LYS-P-74 Enhancer of zeste homolog 2 (EZH2) expression and its association with MYC regulation in follicular lymphoma as a prognostic biomarker.

- 143 LYS-P-75 Plasmablastic lymphoma, a single center experience on 22 cases
- 144 LYS-P-76 A case of primary central nervous system histiocytic sarcoma with prominent proliferation of histiocytic cells between the trabeculae of reactive glial cells
- 144 LYS-P-77 The brain and the lymphoma – not so uncommon friendship
- 145 LYS-P-78 Prognostic role of MAPK/ERK signal pathway alterations in patients with Langerhans Cell Histiocytosis: Update results
- 146 LYS-P-79 Unusual presentation of indolent T-cell lymphoproliferative disorder of the gastrointestinal tract involving full thickness of the colon
- 147 LYS-P-80 A case of primary pulmonary extranodal marginal zone lymphoma of mucosa-associated lymphoid tissue with amyloidosis
- 147 LYS-P-81 Transfusion associated complications during bone marrow transplantation in Diffuse Large B – Cell Lymphoma patients
- 149 LYS-P-82 Prolonged clinical remission after rituximab treatment in cases of acquired angioedema
- 150 LYS-P-83 Extranodal NK/T-cell lymphoma of the small intestine in a pediatric patient
- 151 LYS-P-84 Leukemic presentation of Anaplastic large cell lymphoma, ALK-positive: report of a case and brief review of literature.
- 152 LYS-P-85 Non-Hodgkin lymphoma secondary to Hodgkin lymphoma in an Adult Patient with Nijmegen Breakage Syndrome
- 153 LYS-P-86 Clinico-histomorphological correlation of Epstein Barr Virus in Hodgkin's Lymphoma
- 154 LYS-P-87 EBV-positive NK/T-cell lymphoma, associated with chronic active EBV infection: A case report
- 155 LYS-P-88 A Case Report of Myeloproliferative Neoplasms Following Treatment of Myeloid Sarcoma Presenting as Spleen and Splenic lymph node tumors.
- 156 LYS-P-89 Non-Hodgkin lymphoma simulating carcinoma of the vulvar region: Report of two cases
- 156 LYS-P-90 Solitary extramedullary plasmacytoma of the liver in a 26-years old woman
- 157 LYS-P-91 Sex privileged or site privileged lymphomas, a gender comparison
- 158 LYS-P-92 A potential pitfall in lymph node biopsy and cytology: CD30+ ALK- large B-cell "sticky" lymphoma mimicking metastatic carcinoma
- 159 LYS-P-93 Autoimmune Lymphoproliferative Syndrome: suspected diagnosis from the lymph node biopsy of a child with generalized lymphadenopathy
- 160 LYS-P-94 Nodular lymphocyte predominance Hodgkin lymphoma (NLPHL) or T cell rich B cell lymphoma (TCRBCL), a diagnostic challenge.
- 160 LYS-P-95 Flow cytometric Immunophenotyping of Peripheral T cell Neoplasms in Yemen
- 161 LYS-P-96 Intravascular large B-cell lymphoma with relapsing postchemotherapy, treated by stem cell transplant
- 162 LYS-P-97 Primary CD5-positive diffuse large B-cell lymphoma of the brain: case report
- 162 LYS-P-98 Grey zone lymphoma



# **Bone Marrow Symposium**

---

Oral Presentations (BMWS-O-1 – BMWS-O-4)

## Bone Marrow Symposium

### Oral Presentations (BMWS-O-1 – BMWS-O-4)

BMWS-O-1

### Bone marrow infiltration of angioimmunoblastic T-cell lymphoma: morphologic patterns and ancillary phenotypic analyses

Magdalena M. Gerlach<sup>\*1</sup>, Darius Juskevicius<sup>1</sup>, Stefan Dirnhofer<sup>1</sup>, Alexandar Tzankov<sup>1</sup>

<sup>1</sup>*Institute of Pathology, University Hospital Basel, Basel, Switzerland*

**Background:** Angioimmunoblastic T-cell lymphoma (AITL) accounts for 20% of all non-cutaneous T-cell lymphomas. It is characterized by lymphadenopathy and paraneoplastic symptoms due to an unrestrained immunological crosstalk between the neoplastic T-cells and the host, which is explained by its histogenesis from T-follicular-helper cells (TFH), and lymphoma cells express TFH markers. Though evident in the majority of cases, objectification of bone marrow (BM) involvement can provide difficulties, as there is lack of reliable morphologic and phenotypic indicators. Further, only little is known about the distribution of TFH in healthy or otherwise effected BM, making a distinction between AITL spread and its differential diagnoses at occasions problematic.

**Principals/Methodology:** We aimed to establish a reliable approach to identify BM infiltrates of AITL. Besides conventional stainings, we analyzed TFH typical markers (BCL6, CD10, CXCL13, ICOS, PD1) in matching pairs of lymph nodes (LN) and BM of AITL patients with (n=28) and without (n=12) suspected BM involvement. We investigated the dissemination of TFH in healthy BM (n=5) and BM samples with reactive changes (n=13) as well as in BM infiltrated by other lymphoid neoplasm (n=40).

**Results:** There were 3 BM infiltration patterns of AITL: (i) interstitial/micronodular with eosinophils (17/28); (ii) interstitial/micronodular without eosinophils (8/28); (iii) diffuse with eosinophils (3/28). TFH marker expression was generally weaker in the BM than in the LN. PD1 proved to be consistently positive, followed by BCL6. In contrast, the majority of AITL patients without BM involvement had no PD1 or BCL6 stainable cells in the biopsies. Disregarding the frequent but weak BCL6 positivity of the myelopoiesis, there was no or only single-cell-expression of PD1 or BCL6 in healthy and reactive BM. With the exception of mycosis fungoides, BM infiltrates of other lymphoid neoplasms of differential diagnostic importance (e.g. multiple myeloma, peripheral T-cell lymphoma) had no or only barely detectable PD1 or BCL6 positivity, or contained only small reactive PD1+ lymphocytes (e.g. Hodgkin lymphoma).

**Conclusion:** BM involvement by AITL shows 3 different patterns and is often accompanied by eosinophilia. The expression of TFH markers in BM is weaker than in the LN, however PD1 and BCL6 are most reliable for detection of even subtle AITL infiltrates. Nonetheless, awareness of the expression of these two markers in other BM conditions can help avoiding misinterpretations.



BMWS-O-2

## The oncogenic role of IGF1R mutations in multiple myeloma

Sarah Keppler<sup>1</sup>, Marlene Schwarzfischer<sup>1</sup>, Hanna Starz<sup>1</sup>, Kathyrene Issac<sup>1</sup>, Severin Fink<sup>2</sup>, Hermann Einsele<sup>3</sup>, Ralf Bargou<sup>2</sup>, Andreas Rosenwald<sup>1</sup>, Thorsten Stühmer<sup>2</sup>, Ellen Leich-Zbat<sup>\*1</sup>

<sup>1</sup>Institute of Pathology, University of Würzburg, <sup>2</sup>Comprehensive Cancer Center Mainfranken, <sup>3</sup>Department of Internal Medicine II, University Hospital Würzburg, Würzburg, Germany

**Background:** Multiple myeloma (MM), an incurable plasma cell malignancy, is characterized by a very heterogeneous genetic background. Whole exome re-sequencing, however, revealed a network composed of receptor-tyrosine kinases (RTKs), adhesion molecules and their downstream effectors that was affected by mutations in almost all MM cases. Moreover, sequencing the coding regions of six RTKs in MM samples of a clinical study cohort revealed that mutations in RTKs, specifically rare RTK-SNPs, are significantly associated with worse survival. IGF1R was among the most frequently mutated RTKs.

**Principals/Methodology:** Thus, we aimed to investigate the functional role of IGF1R mutations (here: of a mutation detected in the cell line L363 and of a mutation detected in a MM patient) using different cell line models. We established stable CRISPR/Cas9-mediated IGF1R knockdown in L363 cells (L363-IGF1R-KD) and also generated stable sublines overexpressing either wild-type or mutant IGF1Rs from the MM cell lines AMO1 and JJN3, and from the non-tumor cell line HEK293FT, using the transposon-based Sleeping Beauty system. Additionally, wild-type or mutant IGF1Rs were stably expressed in L363-IGF1R-KD cells.

**Results:** In HEK and L363-IGF1R-KD cells, overexpression of IGF1R-WT led to increased levels of phospho-MEK1/2 and phospho-ERK1/2, indicating increased activity of this pathway. This effect was even more prominent upon expression of the two IGF1R mutants, and preliminary assessments of these different L363 cell line models also showed higher rates of proliferation compared to normal L363 cells. In contrast, MEK-ERK signaling was not affected by WT or mutant IGF1R in JJN3 or AMO1 cells, and, accordingly, in these models the proliferation rate was not significantly changed either.

**Conclusion:** In conclusion, we show that the overexpression of WT IGF1R and specifically the overexpression of mutant IGF1R activates MEK-ERK signaling. However, downstream signaling was affected in different ways between the three MM cell lines, highlighting the functional heterogeneity of oncogenic signaling in MM. Future functional approaches using these cell line models will further evaluate the influence of WT and mutant IGF1R on proliferation in independent assays and finally focus on detailed in vitro drug screens using IGF1R-inhibitors alone or in combination with inhibitors that target potential downstream effectors of IGF1R.

BMWS-O-3

## RUNX1 mutations can lead to aberrant expression of CD79a and PAX5 in acute myelogenous leukemias: a potential diagnostic pitfall

Thomas Menter<sup>1</sup>, Pontus Lundberg<sup>2</sup>, Stefan Dirnhofer<sup>1</sup>, Alexander Tzankov<sup>\*1</sup>

<sup>1</sup>Pathology, <sup>2</sup>Hematology, University Hospital Basel, Basel, Switzerland

**Background:** RUNX1 is a crucial transcription factor for hematopoietic stem cells and plays an oncogenic role in acute leukemias (AL), both lymphoblastic (ALL) and myelogenous (AML). Besides the t(8;21) leading to RUNX1-RUNX1T1-fusion, different types of RUNX1 somatic mutations have been discovered in myeloid malignancies. In addition, it has been described that AML with t(8;21) can aberrantly express B-cell markers, especially CD19, CD79a and PAX5.

**Principals/Methodology:** Three bone marrow trephine biopsies with CD79a and/or PAX5+, MPO- AL were investigated by immunohistochemistry, karyotyping and NGS-based panel sequencing and compared to a historical collective of AML (n=42) stained for the B-cell markers CD19, CD20, CD79a and PAX5, as well as 27 AML diagnosed at our institution between 06/17 and 04/18.

**Results:** These three AL cases with an equivocal immunophenotype sharing negativity for MPO, CD19 and CD20 but expressing CD79a and PAX5 were preliminary histopathologically classified as ALL. All were positive for CD34 and TdT but negative for the additional myeloid markers CD11c, CD14 and CD117 by immunohistochemistry. On flow cytometry (FCM), the blasts of the three cases were positive for the myeloid markers CD13 ( $\pm$ ), CD33 and CD117 ( $\pm$  and dim) as well as CD15 (2/3 cases) and negative for CD19, CD20, CD22 and CD79a; thus FCM favored AML. Mutational analysis revealed deleterious (frameshift and nonsense) or expected deleterious double- or single mutations of RUNX1 (G165fs and E86fs, R166\*, and R166Q and D160E), and additional mutations typical of AML such as DNMT3A in two instances, and NRAS, SRSF2 and TET2 in one each. All cases were devoid of t(8;21). In our historical collective only 2/42 CD19 and PAX5+ AML, both harboring t(8;21), were observed, and neither CD79a nor PAX5 positive cases have been detected in the 27 RUNX1 mutation- and t(8;21)-negative newly diagnosed AML cases of the last 9 months.

**Conclusion:** Aberrant CD79a and PAX5 expression can be found in AML with RUNX1 mutations even without the translocation t(8;21). This B-cell marker expression in MPO- RUNX1 mutant AML is a potential pitfall with the diagnosis of ALL, and shows the importance of including FCM and genetic data in the integrative diagnosis of AL. Our observation suggests that, in addition to AML cases with t(8;21) leading to RUNX1-inactivating RUNX1-RUNX1T1-fusions, deleterious point mutations of RUNX1 can, analogously to the former, promote PAX5-mediated activation of B-cell marker expression in neoplastic myeloid blasts.

BMWS-O-4

## Myeloid Neoplasms Arising in Chronic Lymphocytic Leukemia or Other Indolent B-Cell lymphomas in Bone Marrow: An intrinsic Predisposition Due to Altered Microenvironment or A Therapy-Related Direct Genetic Insult?

Lianhe Yang<sup>1</sup>, Catherine Luedke<sup>2</sup>, Rachel Jug<sup>2</sup>, Jonathan Galeotti<sup>3</sup>, Moe Takeda<sup>4</sup>, Imran Siddiqi<sup>4</sup>, Jerald Gong<sup>5</sup>, Mark C. Lu<sup>6</sup>, Endi Wang<sup>2</sup>

<sup>1</sup>Pathology, The first affiliated hospital and college of basic medical science, Chian Medical University, Shenyang, China, <sup>2</sup>pathology, Department of Pathology, Duke University Medical Center, Durham, <sup>3</sup>Pathology, Department of Pathology, University of North Carolina, Chapel Hill, <sup>4</sup>Pathology, Department of Pathology, University of Southern California, Los Angeles, <sup>5</sup>Pathology, Thomas Jefferson University, Philadelphia, <sup>6</sup>Department of Laboratory Medicine, University of California San Francisco, San Francisco, United States

**Background:** While myeloid neoplasms (MN) are sometimes associated with chronic lymphocytic leukemia/alike neoplasm (CLL), the myeloid leukemogenesis in this setting is unclear.

**Principals/Methodology:** We identified 57 cases of MNs with preceding or concurrent CLL, which were retrospectively analyzed.

**Results:** Of 57 cases, 28 had preceding CLL that was treated before diagnosis of MN, and 29 had concurrent CLL. The median age was 60.5 (32-78) for the former at CLL diagnosis, and 73 (51-91) for the latter. For cases with preceding CLL, the median interval between the diagnoses was 72 months (3-276), while that between the treatment and development of MN was 56 months (6-204). The CLL treatment involved variable combinations of regimens. The types of MNs included myelodysplastic syndrome (MDS) in 14,



acute myeloid leukemia (AML) in 10, myeloproliferative neoplasm (MPN) in 2 and MDS/MPN in 2 cases, for the group with preceding CLL, while for the other with concurrent CLL, included MDS in 10, AML in 8, MPN in 10 and MDS/MPN in 1 case(s). Cytogenetics were performed in 50 cases. Of the cases with preceding CLL, 92% (23/25) showed clonal abnormalities, including 68% (17/25) with -7/7q-, 5q- or complex changes, whereas those with concurrent CLL exhibited clonal abnormalities in 60% (15/25) of the cases (OR=7.6, p=0.018), including 36% (9/25) with -7/7q-, 5q- or complex changes (OR=3.78, p= 0.046). Follow-up information was available in 28 and 26 cases, respectively, with median follow-up of 12 months (1-149). Median overall survival for patients with preceding CLL was 9.5 months, compared to 27 months for those with concurrent CLL. When adjusted for age and types of MN, the difference between the two groups was statistically significant with the hazard ratio=3.15 (P=0.01) against the former group.

**Conclusion:** The spectrum of MN is different between the two groups, with MNs with concurrent CLL showing more MPNs; the latency between CLL treatment and MN is ~5 years, similar to that for MN associated with alkylating agents; higher rates of cytogenetic abnormalities and adverse changes in the group with chemotherapy than the other implies distinct leukemogenesis in setting of CLL (damaged soil versus cytotoxic effect); the survivals in the two groups seem comparable to therapy-related MN and de novo MN, respectively. While chemotherapy may play a role in development of MN in setting of CLL, the degree of intrinsic predisposition for certain MN remains to be studied.



# Bone Marrow Symposium

---

Poster Presentations (BMS-P-1 – BMS-P-21)

## Bone Marrow Symposium

### Poster Presentations (BMS-P-1 – BMS-P-26)

BMWS-P-1

### Mixed-phenotype acute leukemia (B-/myeloid) with BCR-ABL1 like alteration.

John KSS Philip<sup>1</sup>, Sandeep Gurbuxani<sup>1</sup>, Andrew Artz<sup>2</sup>, Jeremy Segal<sup>1</sup>, Michelle Le Beau<sup>2</sup>,  
Madina Sukhanova<sup>2</sup>, Y. Lynn Wang<sup>2</sup>, Elizabeth Hyjek<sup>1</sup>, Girish Venkataraman<sup>1</sup>

<sup>1</sup>Pathology, <sup>2</sup>Medicine, University of Chicago, Chicago, United States

**Background:** BCR-ABL1-like (Ph-like) B acute lymphoblastic leukemia (B-ALL) is a provisional entity in World Health Organization 2016 updated classification. This Ph-like alteration has not been described in other acute leukemias, including mixed phenotype acute leukemias.

**Principals/Methodology:** A 68-year-old man presented to our hospital with Ph-like B- ALL. He was status post 2 cycles of hyper CVAD, inotuzumab, 1 cycle blinatumomab (anti CD19), vincristine, rituximab, dexamethasone and was on dasatinib. Seven months after initial diagnosis, his blasts showed immunophenotype consistent with B-/ myeloid mixed-phenotype acute leukemia (MPAL) with persistent cytogenetic findings. Flow cytometric, cytogenetic and molecular findings will be discussed.

**Results:** Initial flow cytometry on peripheral blood detected blasts that expressed CD34, TdT, CD19, CD10, and CD33 without CD117. Karyotyping showed dic (7;17)(p11.2;p11.2). FISH testing revealed abnormalities at 5q32 (PDGFRB or CSF1R; could not be differentiated in view of their close proximity) with TP53 deletion without CRLF2 rearrangement and BCR-ABL1 fusion. Next-generation sequencing detected IKZF1 deletion. The findings are consistent with Ph-like B- ALL. Bone marrow biopsy after cytoreductive chemotherapy revealed 10-30% cellularity with 69% blasts with similar immunophenotype as described above. After a month of dasatinib therapy, the blasts showed a mixed (B-/myeloid) phenotype with persistent cytogenetic findings. Bone marrow biopsy showed 90% cellularity with 86% blasts that were positive for CD19, CD10, CD34, TdT, CD58, MPO (fraction) with heterogeneous expression of CD33 and CD22. Myeloperoxidase (MPO) was positive on 10% and 20% of blasts by cytochemical and immunohistochemical staining respectively. Double immunostaining demonstrated 5% of blasts with dual positivity for MPO and PAX5.

**Conclusion:** MPALs are aggressive leukemias. Ph-like acute leukemias are described in B- ALL. Their significance in other acute leukemias including MPALs is not known. This patient had an aggressive clinical course in spite of Dasatinib therapy. To our knowledge, there is only one other reported case of an MPAL with Ph-like alteration. The evolution to MPAL is intriguing and it's unclear if this is an evolution from a preexisting clone, expanding under the influence of anti CD19 or other therapy.

**References:** Choi SM et. al. Am J Clin Pathol. 2017 Nov 20;148(6):523-528.



BMWS-P-2

## Blastic Plasmacytoid Dendritic Cell Neoplasm: genomics mark epigenetic dysregulation as a primary therapeutic target

Maria Rosaria Sapienza\*<sup>1</sup>

<sup>1</sup>Department of Experimental, Diagnostic, and Specialty Medicine, University of Bologna, Bologna, Italy

**Background:** Blastic plasmacytoid dendritic cell neoplasm (BPDCN) is a rare hematologic malignancy that typically presents in the form of skin manifestations with or without lymph node and bone marrow involvement. To date, no standardized therapy has been established and the optimal treatment remains to be defined. Recent studies suggested new therapeutic options mainly derived from the investigation of the BPDCN transcriptome. On the contrary, the BPDCN DNA features were scarcely evaluated. We aimed to design the first therapeutic strategy derived from the mutational profile of the BPDCN exome

**Principals/Methodology:** We analyzed by whole-exome sequencing (WES) 14 BPDCN samples and the BPDCN patient-derived CAL-1 cell line. To evaluate the mutational impact at gene expression and epigenetic levels, we sequenced the entire BPDCN transcriptome and mapped the genome-wide distribution of H3K27me3 and H3K27Ac, two epigenetic marks of transcriptional repression and induction, respectively. Thanks to the integration of sequencing data we identified a new therapeutic approach that we tested in a preclinical BPDCN-mouse model.

**Results:** Twenty-five epigenetic modifier genes were mutated and the functional enrichment analysis of WES data, recognized the epigenetic process as the most undermined by mutational events (Fig. 1,2). Also, the gene expression analysis reported the significant deregulation of gene-signatures involved in the methylation process and potentially responsive to hypomethylating agents (Fig.3). As regard the BPDCN epigenetic profile, patients converged on the same H3K27-acetylated regions and displayed a set of cell-cycle genes aberrantly up-regulated and marked by promoter-acetylation (Fig.4). Globally, the presence of epigenetic aberrations at genetic and epigenetic levels suggested to adopt a therapy based on epigenetic drugs. We tested *in vivo* the efficacy of epigenetic agents FDA approved: 5'-Azacytine, Decitabine, Romidepsine and Bortezomib, alone and in combination. The combined use of 5'-Azacytine and Decitabine reached the best results by significantly arresting the *in vivo* BPDCN tumor growth (Fig.5,6).

**Conclusion:** We identified the deregulation of epigenetic program as a genetic hallmark of BPDCN and proposed a novel therapeutic approach based on the combination of two hypomethylating agents 5'-Azacytidine and Decitabine to be tested in future clinical trials.

BMWS-P-3

## Impact of Clinicopathologic Factors on Overall Survival in Bone Marrow Involvement by Diffuse Large B Cell Lymphoma: Indian Scenario

Pooja K. Gajaria\*<sup>1</sup>, Tanuja Shet<sup>1</sup>, Epari Sridhar<sup>1</sup>, Manju Sengar<sup>2</sup>

<sup>1</sup>Pathology, <sup>2</sup>Medical Oncology, Tata Memorial Hospital, Mumbai, India, Mumbai, India

**Background:** Bone Marrow Involvement (BMI) in Diffuse Large B Cell Lymphoma (DLBL) is reported to occur in 10-15% patients at diagnosis. Concordant BMI is known to confer poorer prognosis in these patients as compared to those with discordant disease. We hereby studied the various factors that influence prognosis in patients of DLBL with concordant BMI by large cells.

**Principals/Methodology:** All diagnosed cases of DLBL from the year 2008 to 2016 were screened and those with involvement of bone marrow by large cells were included for the analysis. Clinicopathologic details of all patients were extracted from the electronic medical records and studied for factors impacting their Overall Survival (OS) using the IBM SPSS Statistics version 24.

**Results:** A total of 144 cases with follow-up were included in the study. The age of the patients ranged from 14-74 years (Median age – 52yrs). A quarter of patients had died of the disease, while 23 (16%) had disease relapse. The factors that were associated with poor OS in these patients were age of the patient being  $\geq 60$  years ( $p = 0.053$ ), gender being female ( $p = 0.009$ ), performance status ECOG 4 ( $p = 0.001$ ), revised International Prognostic Index as poor ( $p = 0.001$ ), high lactate dehydrogenase levels ( $p = 0.021$ ) and extra-nodal site of disease involvement ( $p = 0.028$ ). Other factors such as serum  $\beta 2$ -microglobulin levels  $> 2.4$  mg/L ( $p=0.08$ ), pancytopenia at presentation ( $p=0.094$ ), lymphocytosis ( $p=0.0375$ ), Ki-67 index  $>50\%$  ( $p=0.322$ ), reactivity for viral markers ( $p=0.068$ ) did not have a significant impact on OS. Outcome assessment by Hans algorithm is being completed.

**Conclusion:** In cases of DLBL by large cell type, several other factors play an important role in determining prognosis of the patients and these must be taken into consideration to stratify patients for aggressive treatment regimens.

BMWS-P-4

## Primary bone marrow large B cell lymphoma is more often associated with hemophagocytic syndrome, cytogenetic abnormalities and less 1-year-survival rate than the diffuse large B cell lymphoma with secondary marrow involvement

Ching-Fen Yang<sup>1</sup>, Chih-Yi Hsu<sup>1</sup>

<sup>1</sup>Pathology and Laboratory Medicine, Taipei Veterans General Hospital, Taipei, Taiwan

**Background:** Diffuse large B-cell lymphoma (DLBCL) is the most common non-Hodgkin lymphoma. Secondary bone marrow (BM) involvement occurs in about 10% to 16% of patients with DLBCL, but BM is an unusual site to establish the initial diagnosis of DLBCL. Primary BM DLBCL has been reported to be a rare aggressive extranodal lymphoma. Due to the limited published references and more understanding the clinico-pathologic features of primary BM DLBCL, we collected and compared the clinico-pathologic features of 27 primary BM DLBCLs and 56 DLBCLs with secondary BM involvement.

**Principals/Methodology:** We studied bone marrow LBCLs by classifying them into those with no extramedullary mass (primary group, 27 cases) and those with extramedullary mass (secondary group, 56 cases). Compare the age, sex, IPI score, presence of hemophagocytic syndrome, and cytogenetic findings in both groups.

**Results:** The age ( $P=0.665$ ), sex ( $P=0.482$ ), and IPI score ( $P=0.545$ ) in both groups are not significant different. However, presence of hemophagocytic syndrome ( $P<0.001$ ), cytogenetic aberrations ( $p=0.005$ ) and atypical lymphocytes in peripheral blood ( $P=0.025$ ) are more frequent in primary group. One-year-survival rate is less in primary group ( $P=0.03$ ), but the 2-year-survival rate ( $P=0.263$ ) and survival time ( $P=0.297$ ) in both groups are not significant different.

**Conclusion:** Primary BM LBCLs are more clinically aggressive but treatable. Early recognition may be helpful to the patients.

### References:

1. Swerdlow SH, Campo E, Harris NL et al. WHO Classification of Tumours of Haematopoietic and Lymphoid Tissues. Revised 4th ed. Lyon, France: IARC Press, 2017.



2. D. Kajiura, Y. Yamashita, and N. Mori, "Diffuse large B-cell lymphoma initially manifesting in the bone marrow," *American Journal of Clinical Pathology*, vol. 127, no. 5, pp. 762–769, 2007.
3. P. Bhagat, M. U. S. Sachdeva, P. Sharma et al., "Primary bone marrow lymphoma is a rare neoplasm with poor outcome: Case series from single tertiary care centre and review of literature," *Hematological Oncology*, vol. 34, no. 1, pp. 42–48, 2016.
4. H. Chang, Y.-S. Hung, T.-L. Lin et al., "Primary bone marrow diffuse large B cell lymphoma: A case series and review," *Annals of Hematology*, vol. 90, no. 7, pp. 791–796, 2011.
5. Y.-M. Yeh, K.-C. Chang, Y.-P. Chen et al., "Large B cell lymphoma presenting initially in bone marrow, liver and spleen: An aggressive entity associated frequently with haemophagocytic syndrome," *Histopathology*, vol. 57, no. 6, pp. 785–795, 2010.

BMWS-P-5

## CD56 expression in myeloid neoplasias with excess of blasts is accompanied by significant numeric underestimation of blasts on bone marrow aspirates compared to bone marrow biopsies

Alexandar Tzankov<sup>1</sup>, Beatrice Drexler<sup>2</sup>, Maria Martinez<sup>2</sup>, Severin Baerlocher<sup>2</sup>, Jakob R. Passweg<sup>2</sup>, Stephan Dirnhofer<sup>2</sup>, Dimitrios Tsakiris<sup>2</sup>, Jan C. Dirks<sup>2</sup>

<sup>1</sup>Pathology, <sup>2</sup>Hematology, University Hospital Basel, Basel, Switzerland

**Background:** CD56 can be expressed on myeloid blasts. As an adhesion molecule, CD56 might lead to discrepancies between blast counts assessed on smears compared to biopsies. We investigated the impact of CD56-expression on blast counts on aspirates and bone marrow trephines.

**Principals/Methodology:** 37 CD56+ myeloid neoplasms (28 AML, 7 MDS-EB1&2 and 2 CMML-2) with available aspirate smears, flow-cytometry (FCM) data and bone marrow biopsies were studied. CD56+ was defined as  $\geq 10\%$  expression on FCM. Quantification of blasts was made by counting their percentage out of 500 cells on smears or counting CD34+ blast equivalents out of 500 cells on trephines. As a control cohort 39 CD56- myeloid neoplasms (30 AML and 9 MDS-EB1&2) were analyzed. Statistical comparison of blast counts was performed with the Wilcoxon matched pairs tests.

**Results:** CD56+ cases showed higher blast counts on histological compared to cytological specimens [median 63% (IQR 20-84) vs 40% (10-88),  $p=0.001$ ], which did not apply to CD56- cases. This difference was striking in the 20 cases with CD56-positivity in  $\geq 60\%$  of blasts, with a median of 68% (23-89) bone marrow blasts on histology vs 33% (9-80) on cytology ( $p<0.01$ ). In the 17 cases with low expression of CD56 (10-59%), and in CD56- cases such a difference was not observed [50% (15-75) vs 45% (11-90), and 30% (5-99) vs 30% (5-97), respectively] (Figure 1).

**Image:**

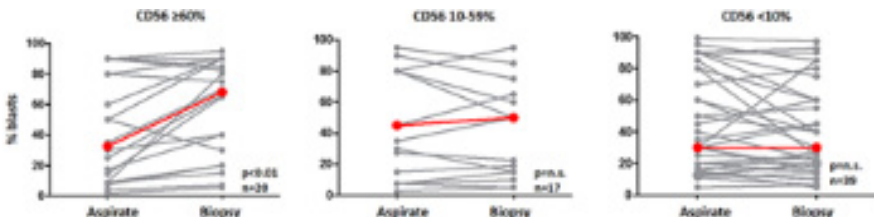


Figure 1: Significantly higher blast counts in bone marrow trephines compared to aspirate smears in patients with homogeneously CD56 expressing blasts

In a subgroup of 7 patients with homogeneously CD56-expressing blasts FCM data of the bone marrow and the peripheral blood were available and showed that CD56+ blast numbers were significantly lower in the periphery compared to the bone marrow [31% (20-48) vs 55% (43-61),  $p=0.016$ ]. The percentage of discrepant cases regarding blast counts was higher (30%) in the 20 homogeneously CD56 expressing cases, compared to 18% in cases with low or lacking expression of CD56. 5 MDS-EB cases in the first group were in need of reclassification as AML, based on the higher blast count assessed on trephines, while in the latter two groups, one case each was in need of reclassification, based on either method.

**Conclusion:** Blast counts in bone marrow aspirates of homogeneously CD56-expressing myeloid neoplasms are at median 33% lower than those in bone marrow biopsies. This might be related, as also suggested by our data on the preferential dissemination of CD56- blasts into the periphery, to the adhesive properties of CD56. CD56 may impair the aspirability of blasts and should be taken into consideration to obtain reliable blast counts.

BMWS-P-6

## Primary Bone Marrow Burkitt Leukemia

Shiraz Fidaï<sup>1</sup>, Madina Sukhanova<sup>2</sup>, Wendy Stock<sup>2</sup>, Girish Venkataraman<sup>1</sup>

<sup>1</sup>Pathology, <sup>2</sup>Medicine, The University of Chicago Medicine, Chicago, United States

**Background:** Pure Burkitt leukemia (PBL) in absence of a mass is uncommon as Burkitt lymphomas mostly present with bulky tumor masses that secondarily involve the bone marrow.

**Principals/Methodology:** We present a 34-year-old male with history of chronic back pain who presented with acute pain to emergency room. CBC showed severe thrombocytopenia (38 k/uL), anemia (11 g/dL), and circulating blasts (3%, WBC 6.3 K/uL with mild left shift including promyelocytes, metamyelocytes, and myelocytes). Lymphadenopathy was absent on both physical examination and whole-body CT scan. CSF evaluation was negative. Peripheral blood flow cytometry showed 5% mature B-cells CD34 and TdT negative with atypical partial CD10 in a subset and a myeloid blast population without abnormal markers. Light chains were not examined.

**Results:** Bone marrow biopsy showed hypercellular (90%) marrow, primarily replaced by medium to large atypical blast-like cells with areas of "starry sky" pattern. Atypical cells were positive for CD19, CD20 and CD10, BCL-6, c-MYC (95%), Ki-67 (95%) and negative for BCL-2, CD34 and TdT, most consistent with Burkitt leukemia isolated to bone marrow.

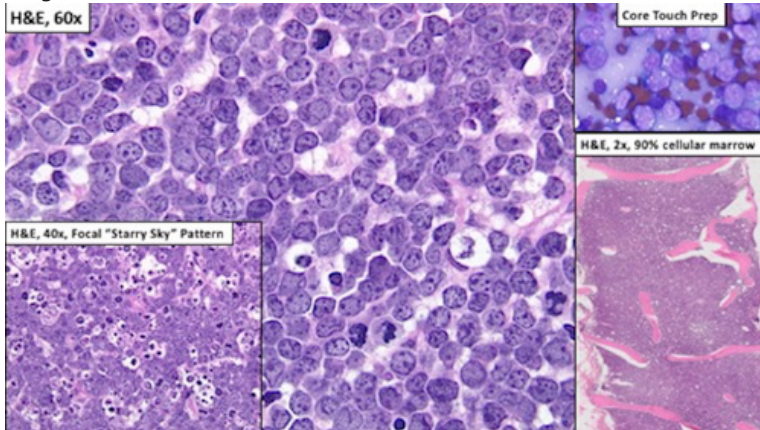
FISH performed on bone marrow was positive for MYC translocation and IGH translocation, and negative for BCL6 translocation and BCL2 translocation. An initial karyotype on peripheral blood showed abnormal mosaic male karyotype with tetraploid clone (92, XYY) without a MYC translocation. The patient received CALGB 10002 chemotherapy. Post-induction marrow biopsy showed variably cellular marrow with multilineage hematopoiesis and no evidence of lymphoma/leukemia by morphology, immunohistochemistry and flow cytometry.

**Conclusion:** 1. Burkitt lymphoma restricted to bone marrow is an uncommon primary presentation. Patients reportedly perform better compared to cases with extensive extramedullary involvement.

2. The presence of tetraploid clone without MYC translocation on peripheral blood karyotype is intriguing, although the cell of origin of this clone remains uncertain.



**Image:**



BMWS-P-7

## Hodgkin lymphoma with marrow involvement as presenting feature

Tanuja Shet\*<sup>1</sup>, Sridhar Epari<sup>1</sup>, Manju Sengar<sup>2</sup>, Hashmukh Jain<sup>2</sup>  
and Hematolymphoid disease management group

<sup>1</sup>Dept Of Pathology, <sup>2</sup>Medical Oncology, Tata Memorial Hospital, Mumbai, India

**Background:** Hodgkin lymphoma presenting with pancytopenia and marrow related symptoms is uncommon.

**Principals/Methodology:** We searched our archives for Hodgkin with marrow involvement and looked for cases which presented with hematological problems due to marrow involvement

**Results:** A total of 98 cases of Hodgkin with marrow involvement were evaluated of whom 14 had a primary presentation with hematological issues. Of these two patients were HIV positive and one HbSAg positive. Seven patients had no palpable peripheral lymphadenopathy and these were treated on basis of marrow report without node biopsy and these patients uniquely were in age group of 18 to 27 years. The presentation in 5 patients was pancytopenia, 2 thrombocytopenia and 7 presented with refractory anaemia. Spleen involvement was seen in all and only in two patients had liver and lung lesions. Two patterns of histological involvement as seen. Diffuse fibrosis with entrapped Reed Sternberg (RS) cells replacing entire marrow in 4 patients( all with no peripheral palpable nodes) and Lymphohistiocytic nodules without fibrosis with RS cells. EBVLMF1 was positive in 10/14 cases, 8/14 CD15 positive, and only 1/14 had CD20 expression. Hemophagocytic syndrome was seen in 7 patients and all these had a lymphohistiocytic type of involvement of marrow. The fibrotic type of involvement was mistaken for myelofibrosis in two patients. All were treated with ABVD like therapy and follow up was available in 12 patients. Three died from progressive HPS and infection during primary diagnosis. Seven patients are alive with no relapse and two are alive after relapse and bone marrow transplantation.

**Conclusion:** Hodgkin may present with upfront marrow involvement symptoms and though the prognosis remains good, there are some interesting site distribution patterns that are seen and awareness would help in avoiding misdiagnosis.

BMWS-P-8

## Clinical and Laboratory Characteristics of IgA Plasma Cell Neoplasms

Gabriel Habermehl<sup>1</sup>, Megan Nakashima<sup>\*1</sup>, Claudiu Cotta<sup>1</sup><sup>1</sup>Laboratory Medicine, Cleveland Clinic, Cleveland, United States

**Background:** IgA plasma cell neoplasms (PCN) are significantly less frequent than their IgG counterparts. This is one of the reasons why there are few studies focusing exclusively on their presentation, characteristics and clinical evolution. Moreover, even in articles in which IgA PCN are discussed together with IgG neoplasms, current classifications and diagnostic criteria are not used.

**Principals/Methodology:** To fill this knowledge gap, 18 cases of IgA plasma cell neoplasms were identified, their clinical, radiologic, laboratory characteristics at presentation and their clinical course were examined.

**Results:** 10 (of 18) patients had anemia, others bone lesions (50%, 3 or more in 7 cases), renal disease or decreased immune functions. M proteins were IgA kappa in 10 cases, IgA lambda in 8. In 16 cases immunoglobulins other than IgA were decreased. Calcium levels were normal in 16 of 17 cases. Creatinine and clearance rates were abnormal, associated with renal failure in 4 cases. Plasma cells in the bone marrow varied from less than 5% to over 90%. 16 of the 17 cases with conventional cytogenetics showed normal, diploid results. Fluorescence in-situ hybridization (FISH) performed in 13 case showed normal results in 7 and abnormalities involving TP53 in 2. As the main finding, IgA neoplasms were classified as MGUS (4 cases) in a much lower proportion than their IgG counterparts.

**Conclusion:** IgA PCN are more aggressive than IgG neoplasms, fewer cases meeting the diagnostic criteria for indolent entities such as MGUS or smoldering myeloma.

BMWS-P-9

## Bone Marrow Involvement by Different Lymphomas

Xiaohong Zhang<sup>\*1</sup><sup>1</sup>Pathology, Geisinger Health System, Wilkes-Barre, United States

**Background:** Evaluation of bone marrow involvement (BMI) by lymphoma is important for determining treatment options for the patients with most lymphomas except some fast-growing lymphomas. Different lymphomas have their unique distribution pattern and BMI frequency. This study aims to investigate the rate and characters of BMI by different lymphomas.

**Principals/Methodology:** Total of 964 cases of different lymphomas with bone marrow biopsy for staging were retrieved from Geisinger Health System from 2007 to 2017. These cases include 436 cases of diffuse large B cell lymphoma (DLBCL), 307 cases of other non-Hodgkin's lymphoma (NHL), 45 cases of T cell lymphoma, 21 cases of blast-looking lymphoma, and 155 cases of classical Hodgkin lymphoma (CHL).

**Results:** DLBCL showed BMI in 13.5% of cases. Most of the lymphoma cells in the bone marrow were low grade monotypic B cells; high grade large B lymphoma cells in BMI represented only 11.9% of BMI cases and among these cases DLBCL with activated B-cell type (ABC) represented 71.5%. Other NHL had different BMI rate. Lymphoplasmacytic lymphoma showed BMI rate of 87.5%, mantle cell lymphoma of 60.4%, marginal zone lymphoma of 43.2 and follicular lymphoma of 32.2%. Peripheral T cell lymphoma cases appeared with 25.9% of BMI and anaplastic large cell lymphoma with 6%. Among the blast-looking lymphomas, Burkitt lymphoma had one third of cases with BMI, B-lymphoblastic lymphoma showed 28.6% of BMI rate and T-lymphoblastic lymphoma had 60% of BMI rate. BMI rate in CHL was 6.5% (see table 1).



**Conclusion:** Most cases of DLBCL with BMI showed low grade B lymphoma cells in the bone marrow; most of the cases with high grade large B lymphoma cells in the BMI came from DLBCL with ABC type. NHL had higher BMI rate than DLBCL; lymphoplasmacytic lymphoma was the highest one. Blast-looking lymphomas also had higher BMI rate than DLBCL with highest BMI rate by T-lymphoblastic lymphoma. T-cell lymphomas showed similar pattern of BMI to the B-cell lymphoma with higher BMI rate in peripheral T-cell lymphoma than that in anaplastic large cell lymphoma. CHL had the lowest BMI rate among all lymphomas.

Lymphocytes	Positive BMI	Negative BMI
Diffuse large B cell lymphoma	59/436 (13.5%)*	377/436 (86.5%)
<b>Non-Hodgkin lymphomas</b>		
Lymphoplasmacytic lymphoma	7/8 (87.5%)	1/8 (12.5%)
Mantle cell lymphoma	29/48 (60.4%)	19/48 (39.6%)
Marginal zone lymphoma	32/74 (43.2%)	42/74 (56.8%)
Follicular lymphoma	57/177 (32.2%)	120/177 (67.8%)
<b>T-cell lymphomas</b>		
Peripheral T-cell lymphoma	7/27 (25.9%)	20/27 (74.1%)
Anaplastic large cell lymphoma	1/18 (6%)	17/18 (94%)
<b>Blast-looking lymphomas</b>		
Barkitt lymphoma	3/9 (33.3%)	6/9 (67.7%)
B-lymphoblastic lymphoma	2/7 (28.6%)	5/7 (71.4%)
T-lymphoblastic lymphoma	3/5 (60%)	2/5 (40%)
Classical Hodgkin lymphoma	10/155 (6.5%)	145/155 (93.5%)

\*7 cases were BMI by high grade large B lymphoma cells and all 5 of them were from ABC type.

Table 1. Bone marrow involvement by different lymphomas

BMWS-P-10

## Bone marrow presentation of T-cell lymphoma in two patients with chronic lymphocytic leukemia.

Dina Milowich<sup>1</sup>, Mounir Trimech<sup>1</sup>, Anne Cairoli<sup>2</sup>, Nicolas Ketterer<sup>3</sup>, Bettina Bisig<sup>1</sup>, Laurence de Leval<sup>1</sup><sup>1</sup>Institute of Pathology, <sup>2</sup>Department of Hematology, Lausanne University Hospital, <sup>3</sup>Center of Oncology, Clinique Bois-Cerf, Lausanne, Switzerland

**Background:** Patients with CLL/SLL have an increased risk of developing other types of malignancies, including T-cell lymphomas, an occurrence that remains overall rare. Less than 30 such cases are described. PTCL not otherwise specified with cytotoxic phenotype is the most common histotype, and bone marrow involvement is documented in a minority of the cases. We report two CLL patients who developed PTCL diagnosed on a bone marrow biopsy.

**Principals/Methodology:** Patients' histories were retrieved from clinical files and histological materials were reviewed.

**Results:** Patient 1 (79y, male) known for CLL and cutaneous lymphomatoid papulosis since 2016 presented in July 2017 with a clinical suspicion of Richter syndrome due to recent weight loss, asthenia and bicytopenia. PET-CT showed generalized lymphadenopathies and multiple bone and soft tissue lesions. Bone marrow biopsy showed focal infiltration by CLL/SLL, prominent eosinophilia and sheets of large cells with anaplastic morphology which were CD30+, MUM1+, CD43+, CD2-/+, negative for CD3, CD4, CD5, CD8, CD15, EMA, ALK, p63, and cytotoxic markers as well as for B cells markers. FISH for DUSP22 rearrangement was negative and clonality studies were not conclusive due to poor ADN quality. A diagnosis of ALK<sup>+</sup> anaplastic large cell lymphoma (ALCL) was rendered. The patient was treated by 4 courses of Brentuximab-Vedotin, BEAM and autologous stem cell transplantation in January 2018. PET-CT in April 2018 showed a complete metabolic response.

Patient 2 (65y, male), known for CLL/SLL, developed B symptoms and thrombocytopenia. Comparative imaging studies showed enlargement of lymphadenopathies and a Richter transformation was suspected. The bone marrow was 85% cellular, comprising about 30% infiltration by small lymphoid cells consistent with CLL and 5-10% admixed large atypical cells which were CD3+, CD2+, CD4+, CD7+/-, TIA-1+, perforin+, CD30-, EBER-. Molecular studies showed monoclonal rearrangements of IGH, IGK and TR genes. A diagnosis of CLL with cytotoxic CD4+ PTCL-NOS was made. The patient passed away shortly after the diagnosis due to pancytopenia and sepsis.

**Conclusion:** A diagnosis of PTCL should be considered when examining bone marrow samples from CLL patients with clinical suspicion of Richter syndrome. The diagnosis can be challenging when the T-cell neoplasm presents as a composite infiltrate admixed to the CLL, as exemplified in one of our cases.

BMWS-P-11

## Finding the incidence of Mucormycosis in Hodgkin Lymphoma Patients with undergoing Bone Marrow Transplantation

Arooj Fatima<sup>1</sup>, Syed Sammar Abbas Zaidi<sup>1,2</sup><sup>1</sup>SKMC & RC, <sup>2</sup>wecare medical centre, Lahore, Pakistan

**Background:** Mucormycosis is a fatal opportunistic fungal infection with high mortality rates. This infection can invade in many organs of the body including sinuses, orbit, brain, kidney, gastrointestinal tract, skin and subcutaneous tissues.



**Principals/Methodology:** The study aims to determine the frequency and outcome of fungal infection in Hodgkin Lymphoma patients undergoing allogeneic and autologous bone marrow transplantation.

**Results:** A retrospective study was done in Shaukat Khanum Cancer Hospital and Research Centre during the period 2010-2017. 150 patients underwent an allogeneic or autologous stem cell transplant with matched sibling/parent donor were included. 10% of the Hodgkin Lymphoma patients developed mucormycosis. 13 infections occur within the 90 days of transplant whereas 3 occurred at the time of autopsy. The nose and maxillary sinuses are frequently affected sites. Most commonly involved sinus was maxillary (87%) followed by ethmoid (71%), frontal (44%) and sphenoid (27) sinuses. All patients were treated with prolonged amphotericin B therapy. Surgical debridement was done in the 8 patients. Death from mucormycosis occurred 11/15 patients.

**Conclusion:** Early diagnosis of zygomycosis and meticulous broad spectrum antifungal therapy are necessary to avoid.

BMWS-P-12

## The bone marrow involvement in classic Hodgkin lymphoma - a five-year study in a single institute

Hsin-Ni Li<sup>1</sup>, Ren Ching Wang<sup>1</sup>

<sup>1</sup>Department of Pathology and Laboratory Medicine, Taichung Veterans General Hospital, Taichung City, Taiwan

**Background:** Classic Hodgkin lymphoma (CHL) is a monoclonal lymphoid neoplasm derived from B cells, characterised by the presence of mononuclear Hodgkin cells and multinucleated Reed-Sternberg cells in a background of a mixture of reactive immune cells. Four histological subtypes have been distinguished: nodular sclerosis CHL, mixed cellularity CHL, lymphocyte-rich CHL, and lymphocyte-depleted CHL. Although bone marrow biopsy is no longer indicated for the routine staging of Hodgkin lymphoma in the Lugano classification, it is still recommended to exclude false-positive uptake of fluorodeoxyglucose (FDG) in positron emission tomography/ computed tomography (PET/CT) staging and to confirm residual disease after therapies. This study aims to identify the morphologic features of bone marrow involvement in classic Hodgkin lymphoma, which may be vague and mimic other benign or malignant etiologies.

**Principals/Methodology:** Retrospectively, bone marrow biopsies of the 57 newly diagnosed patients with classic Hodgkin lymphoma between 2013 and 2017 were reviewed. Involved bone marrow was carefully evaluated to assess the diagnostic features. Biopsies of primary sites were also reviewed for the classification of subtypes. In situ hybridisation (ISH) of Epstein-Barr virus encoded ribonucleic acid (EBER) was applied to detect Epstein-Barr virus (EBV) infection in these tumors.

**Results:** Marrow involvement was seen in 8 cases (14%). The features of involvement could be further divided into two different patterns. The pattern 1 was to form ill-defined granulomata in which the aggregated histiocytes merged with hematopoietic cells and mixed variable inflammatory cells. The pattern 2 was to form space-occupying lesions displaying loose to fibrotic background with dilated sinusoids. Diagnostic Hodgkin cells and Reed-Sternberg cells could be scanty. Langhans giant cells were not commonly seen. Eosinophil infiltration was more prominent in the pattern 2. However, the difference of patterns was not related to the subtype of classic Hodgkin lymphoma, neither associated with EBV status.

**Conclusion:** Although the rate of bone marrow involvement by classic Hodgkin lymphoma is low, lymphoma cells in the bone marrow could be overlooked due to sparse diagnostic cells. Misdiagnosis as infection may also occur because of the presence of granulomata. Being familiar with the patterns of involvement is thus important for accurate diagnosis and staging to determine the following treatment.

BMWS-P-13

## Differences in the Hodgkin lymphoma microenvironment between lymph node and bone marrow

Triantafyllia Koletsas<sup>1</sup>, Sofia-Eleni Tzorakoleftheraki<sup>1</sup>, Maria Papaioannou<sup>2</sup>, Georgia Karayannopoulou<sup>1</sup>, Ioannis Kostopoulos<sup>1</sup>

<sup>1</sup>Pathology Department, Aristotle University of Thessaloniki, <sup>2</sup>Haematology Department, First Department of Internal Medicine, AHEPA University Hospital, Aristotle University of Thessaloniki, Thessaloniki, Greece

**Background:** Hodgkin lymphoma (HL) is characterized by small number of neoplastic cells surrounded by a dense immune microenvironment. Tumor microenvironment is the niche for tumor cell survival and growth. The consistency and the role of this microenvironment should be defined. The aim of this study was to evaluate the microenvironment consistency of HL in bone marrow and the corresponding involved lymph node, in a case series, and to clarify if it is site-dependent.

**Principals/Methodology:** Seven bone marrow (BM) specimens with HL infiltration (6 classical, cHL and 1 nodular lymphocyte predominant, NLPHL) were retrieved from the archives of our department among with the corresponding lymph node (LN) biopsies in five of them. The approximate number of neoplastic Hodgkin and Reed-Sternberg cells (HRS), the degree of fibrosis and the presence of eosinophils were evaluated on hematoxylin-eosin stain. whereas for the immune cells immunostains for CD3, CD8, CD56, CD57, CD68, TIA-1, GranzymeB, perforin, FOXP3 and PD-L1 (clone 22C3) were performed.

**Results:** In cHL cases fibrosis was more prominent and the neoplastic cells were fewer in BM than in LN. FOXP3+, CD56+ and perforin+ cells were absent or scarce. TIA-1 was more often expressed in LNs, with the exception of the NLPHL case, which presented more positive cells in BM. Only in the NLPHL case, which had a diffuse pattern of infiltration, CD8+ cells in BM outnumbered those observed in the LN, raising the necessity of a clear cut off for the distinction from LBCL. In one case of cHL the T- reactive cells presented activated features. CD68+ cells were in higher numbers in LNs than in BMs, and mainly in nodular sclerosis (NS) subtype. PD-L1 highlighted HRS cells, even when they were infrequent, and it was also expressed in the adjacent inflammatory cells. Satisfactory result for PD-L1 immunostain was considered only in two of the BM biopsies. In NLPHL case there were more PD-L1+ inflammatory cells in BM than in LN.

**Conclusion:** cHLs present fewer neoplastic cells, more fibrosis and less immune cells in BM than in LN. FOXP3+ cells are globally absent or scarce. TIA-1+ cells are more often found in NLPHL. Although the microenvironment of NLPHL is crucial to differentiate diffuse type from LBCL there isn't always a clear distinction. Apart from fibrosis, NS subtype exhibits more CD68+ cells. PD-L1 highlights HRS cells and could serve in defining BM involvement by HL but a validated protocol for BM biopsies is needed.

## Lymphoplasmocytic lymphoma and polycythemia vera: a case of rare co-occurrence, both contributing to clinical hyperviscosity syndrome

Tihomir Dikov<sup>1</sup>, Nikolay Stoyanov<sup>1</sup>, Gueorgui Balatzenko<sup>2</sup>, Branimir Spassov<sup>3</sup>, Margarita Guenova<sup>1</sup>

<sup>1</sup>Laboratory of Hematopathology and Immunology, <sup>2</sup>Laboratory of Cytogenetics and Molecular Biology,

<sup>3</sup>Hematology Clinic, National Specialised Hospital for Active Treatment of Hematological Diseases, Sofia, Bulgaria

**Background:** Lymphoplasmocytic lymphoma (LPL) is currently defined as expansion of small, mature B-cells with variable plasmocytoid differentiation. When exclusively bone marrow (BM) based and accompanied by IgM monoclonal protein, the historical eponym Waldenstrom macroglobulinemia (WM) is still used. Fewer than 20% of WM develop hyperviscosity syndrome. Simultaneous or consequent occurrence of LPL/WD and chronic myeloid neoplasm is only rarely described.

**Principals/Methodology:** A 55-year-old male was referred to our institution complaining of dizziness, tinnitus and fatigue while past medical history included episodes of rectal and duodenal ulcer bleeding.

**Results:** On admission, no lymphadenopathy and/or organomegaly was noted. Peripheral blood counts showed mild leucocytosis (11.8 G/l) with increased hemoglobin (185 g/l), platelets (627 G/l), elevated LDH (354 U/l) and ESR (88 mm/h). BM aspirate disclosed hypercellularity due to increased erythroblasts and megakaryocytes; red cell volume exceeded the predicted value by 30% (presumptive evidence of hyperviscosity). Polycythemia vera (PV) was diagnosed and treated accordingly. Without noticeable improvement of symptoms for 5 years, he was re-admitted and further tests revealed increased total protein (101.9 g/l) while maintaining Hb levels (135 g/l) and Plt (757 G/l). At that point, molecular genetics was BCR-ABL(-)/JAK2V617F (+). Since increased total protein is not a PV feature, immunochemistry was initiated to reveal 34.17 g/l IgM monoclonal protein. In blood smear, besides ruleaux formation, hypersegmented neutrophils were noted, the trephine biopsy revealed granulocytic proliferation and abnormal, large and clustered megakaryocytes in near-normal reticulin matrix together with predominantly nodular lymphoid infiltrates, composed of CD20(+) B-cells, CD138(+)plasmacytes and lymphoplasmocytic forms that upon further flow cytometry were identified as 4.5% CD45(+)CD19(+)CD20(+)CD38(±)CD138(-)cyKappa(+) and 0.4% CD45(+)CD19(+)CD20(+)CD38(+)CD138(+)cyKappa(+) clonal proliferation, thus suggesting concomitant LPL/WD and PV. Fludarabine-based therapy led to IgM reduction and stable disease.

**Conclusion:** Both LPL/WD and PV, though through different mechanisms, are known to underlie a hyperviscosity syndrome, generally defined on clinical background and including a variety of symptoms, attributable to circulatory disturbances. These could be either due to increased red cell mass in blood (as in PV) or IgM-mediated red blood cell aggregation (as seen in LPL/WD).

BMWS-P-15

## Bone marrow biopsy as the only specimen for diagnosis of transformation of splenic marginal zone lymphoma to Burkitt lymphoma

Tatjana Terzic<sup>1</sup>, Milica Radojkovic<sup>2</sup>, Sanja Cirovic<sup>1</sup>, Bojana Cikota Aleksic<sup>3</sup>, Slobodan Ristic<sup>2</sup>

<sup>1</sup>Institute of Pathology, Faculty of Medicine, University of Belgrade, <sup>2</sup>Clinic of Internal Medicine, CHC "Dr Dragisa Misovic-Dedinje", Belgrade, Serbia, <sup>3</sup>Department for Molecular Genetics, Military Medical Academy, Belgrade, Serbia, Belgrade, Serbia

**Background:** Bone marrow (BM) involvement usually represents the systemic dissemination of lymphoma. In cases of splenic marginal zone lymphoma (SMZL), after splenectomy BM examination is the only specimen for evaluation of possible transformation.

**Principals/Methodology:** A 72-year-old woman was admitted in November 2011 for investigation of moderate bicytopenia in the blood count (hemoglobin 89 g/l, MCV 90, the platelets 64x10<sup>9</sup>/L and white blood cells 4.1x10<sup>9</sup>/L), splenomegaly and retroperitoneal lymphadenopathy (up to 9cm), which are seen on ultrasound of the abdomen. The physical examination showed no peripheral lymphadenopathy and absence of hemorrhagic syndrome. The biochemical analysis showed slight elevated LDH (699 IU/l), immunoglobulin M (23.6 g/l) and IgG (20.5 g/l), and all other findings were within normal ranges.

**Results:** We performed a BM biopsy and diagnosis of SMZL was obtained (PAX-5+, CD79alpha+, CD20+, CD5-, CD23+, IgD+, bcl-2+, Ki67+ 30-40% of the cells). In December 2011 the treatment was started with chemotherapy protocol COP (cyclophosphamide, Oncovin, Pronison) and she received the VIII cycles. At the end of August 2012 the control BM biopsy was performed and scanty nodular lymphoid infiltration of bone marrow was present with underlying disease, but splenomegaly was still pronounced (23cm). Splenectomy was done in December 2012. The pathohistological findings in the spleen confirmed diagnosis SMZL. In February 2013, complete remission was achieved, with normal blood count, but the immunoelectrophoresis of serum proteins detected monoclonal IgM kappa type, with elevated  $\beta$ 2-microglobulin (4.76 mg/l). On May 2015, the patient has a pain in the lumbar spine, which was spreaded in the left leg. The pathological fracture of IV lumbar vertebra was registered on the x-ray of the spine. Then, a control BM biopsy was performed and the pathohistological finding reviewed in one half of medullar spaces infiltration by marginal zone lymphoma and the remaining part of the sample was diffuse infiltrated by Burkitt lymphoma (TdT-, PAX-5+, CD20+, CD5-, CD10+, bcl-2-, bcl-6-/+, c-myc+, CD43-, cyclin D1-, CD21-, CD23-, Ki67+ in 95% of tumor cells). In August 2015, the patient died in uraemic syndrome.

**Conclusion:** The literature describes rare cases of secondary Burkitt's lymphoma after follicular lymphoma, lymphoplasmacytic lymphoma and mantle cell lymphoma, but only one case with progression of SMZL in Burkitt's lymphoma have published by Heintel et al. (2003).

## Bone marrow presentation of T-cell/ histiocyte-rich large B-cell lymphoma

Jonathan Ben-Ezra<sup>\*1,2</sup>, Ohad Bentur<sup>3</sup>

<sup>1</sup>Department of Pathology, Tel Aviv Sourasky Medical Center, <sup>2</sup>Department of Pathology, Sackler School of Medicine of Tel Aviv University, <sup>3</sup>Department of Hematology, Tel Aviv Sourasky Medical Center, Tel Aviv, Israel

**Background:** T-cell/histiocyte rich large B-cell lymphoma (TCHRLBCL) is a lymphoma characterized by neoplastic large B cells scattered in a background of reactive T cells and histiocytes. It accounts for approximately 10% of diffuse large B-cell lymphomas, and is considered to be aggressive. TCHRLBCL mainly involves the lymph nodes, with variable involvement of the bone marrow (BM) at diagnosis.

**Principals/Methodology:** Records in Tel Aviv Sourasky Medical Center between the years of 2000-2017 were culled for cases with a diagnosis of TCHRLBCL. To be included in this study, the initial diagnosis of TCHRLBCL had to have been made from a bone marrow biopsy, and the BM biopsy had to be available for review for confirmation of the diagnosis. The study was approved by our institutional Helsinki ethical review panel.

**Results:** Four patients (2M, 2F: Age- 42-77) were found who fulfilled the inclusion criteria.

Two of the four cases presented with pancytopenia. Three of the four patients had lymphadenopathy, all four had splenomegaly, and two had involvement of other extranodal sites.

The bone marrow was chosen as the initial biopsy site in two of the patients because, at that initial point of the workup, no other sites of disease were known; in another patient, it was the most accessible biopsy site, and, in the fourth, it was chosen after biopsy of another site was nondiagnostic. In two of three patients in whom PET-CT scans were performed, no bone marrow involvement was detected. The bone marrow histology was similar in all four cases. The marrow was involved by a nodular infiltrate of predominantly small lymphoid cells. Within these nodules, scattered large cells were seen. Immunohistochemical studies showed that the small lymphoid cells were T cells, and that the large atypical cells were CD20-positive B cells. For the one patient in whom they were performed, flow cytometric and immunogenetic PCR studies demonstrated B-cell clonality. After the initial BM diagnosis of TCHRLBCL, two of the patients were discovered to have low grade extranodal marginal zone (MALT) lymphoma, and one was diagnosed with TCHRLBCL in a lymph node. The patient with nodal TCHRLBCL died four months after diagnosis, two of the other patients had survivals of 36 and 144 months, and one was lost to followup.

**Conclusion:** Although TCHRLBCL is generally thought to be a high grade lymphoma, this may not be the case when the disease is first diagnosed in the BM. A search for extramedullary disease, and particularly extranodal MALT lymphoma, should be made.

BMWS-P-17

## A challenging case of Hodgkin lymphoma with primary presentation as bone marrow infiltrates

Pragya Katoch\*<sup>1</sup>, Preben Johansen<sup>1</sup><sup>1</sup>Pathology, Aalborg Universitetshospital, Aalborg Universitetshospital, Aalborg, Denmark

**Background:** Classical Hodgkin Lymphoma (CHL) presenting primarily with extranodal involvement is rare. We present diagnostic challenges associated with one such case.

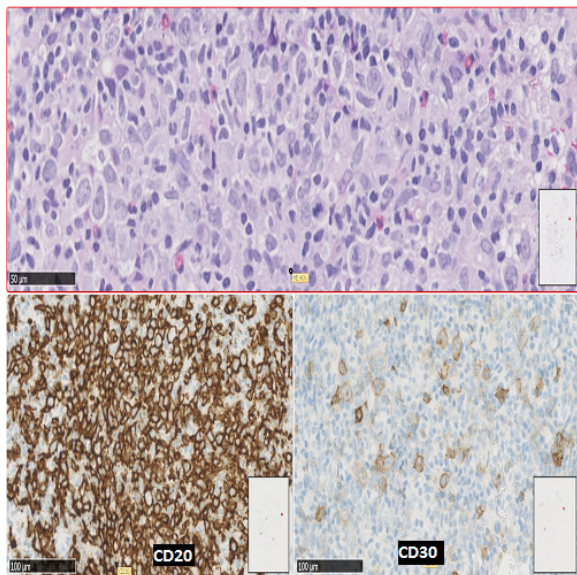
**Principals/Methodology: Case history:** 81 years old male with previous history of lung cancer (2012) was investigated with 3 bone marrow (BM) biopsies (1<sup>st</sup> BM in July 2017) & subsequently in Sep. 2017 a left axillary lymph node(LN) biopsy. July 2017-CT scanning showed splenomegaly, CBC's were unremarkable except for mild thrombocytopenia & mild monocytosis, LDH was normal.

**Results:** All 3 BM showed patchy, nodular lymphocytic infiltrates. The lymphocytic infiltrates were in a background of eosinophils, epithelioid cells & granuloma-like clusters. There were a many middle-sized to large lymphocytes, focally with distinct nucleoli & little cytoplasm. Classic Reed-Sternberg or Hodgkin cells (HRS) were not identified.

Immunohistochemistry (IHC): the large lymphocytes were CD45+, CD20 +, a few were also CD30+. CD15 & EBER -. Ki67 was positive in the majority of the large cells. CD21, CD23, CD5 & CD10- all negative. Flow cytometry was unremarkable with 3% polyclonal B-lymphocytes.

Lymph node biopsy from left axillary node was diagnosed as CHL, mixed cellularity. Many HRS cells were seen arranged in nodular areas separated by small lymphocytes & epithelioid cells, no eosinophils were noticed. IHC revealed the following phenotype in HRS cells: CD30+, CD15-, weak PAX5 & focal weak CD20 +, CD45+, MUM1+, OCT2+ & EBER-. No relation to follicular dendritic reticulum in CD 21 & CD23, CD5 & CD10-.

### Image:





**Conclusion:** The first presenting features of a CHL can be patchy, nodular BM infiltrates as demonstrated by this case. The BM infiltrates lacked morphologically typical HRS cells, there were only a few CD30+ cells & a overweight of CD20+ large lymphocytes. It was not possible to differentiate between a diffuse large cell B cell lymphoma, a mediastinal large B-cell lymphoma & CHL. Correct classification was only possible after the LN biopsy with identification of the typical HRS cells.

BMWS-P-18

## Monoclonal plasmacytosis in bone marrow biopsy as a initial presentation of acute myeloid leukaemia

Mirjana Prvanovic<sup>1</sup>, Natasa Stanisavljevic<sup>2</sup>, Olivera Markovic<sup>2</sup>, Tatjana Terzic<sup>1</sup>

<sup>1</sup>Institute of Pathology, Faculty of Medicine, University of Belgrade, <sup>2</sup>University Hospital Clinical Centre Bezanijaska Kosa, Belgrade, Serbia, Belgrade, Serbia

**Background:** We present a rare case of monoclonal plasmacytosis (MP) in bone marrow (BM) biopsy associated with acute myeloid leukaemia (AML). The simultaneous occurrence of MP and AML in BM biopsy in patient without previous exposure to chemotherapy is very rare.

**Principals/Methodology:** We reported the case of a 45-year-old woman who presented with fatigue, fever, maculopapular rash, weight loss and bone pain. She was admitted to the Haematology Department of UHCC Bezanijaska Kosa in November 2015.

**Results:** The first clinical presentation was very suspicious for multiple myeloma due to anaemia (haemoglobin 111gr/l), elevated creatinin level 93umol/l, uric acid 412umol/l, high LDH 876U/l, Beta2 microglobulin 3.16 µg/mL and sedimentation rate (50mm/h). Serum immunoelectrophoresis showed increased monoclonal IgA (IgA 9.98, IgM 2.29, IgG 10.1), kappa/lambda 0.84. Monoclonal heavy and light chains lambda type was detected in the urine by electrophoresis. But, there was no lytic lesions of skeleton. The BM aspiration revealed around 10% plasma cells and BM biopsy showed infiltration by 20% monoclonal plasma cells (kappa-/lambda+) with 30% infiltration by cells with monocytes differentiation (without excess of blasts). One month later complete blood count showed more prominent anaemia (haemoglobin 77gr/l), leukocytosis (white blood cell count 33x109/l) and thrombocytopenia (platelet count 34x109/l). Leukocytic formula of peripheral blood smear revealed: neutrophils 31%, myeloblasts 12%, monoblasts, promonocytes and monocytes 53%). Liquor immunophenotyping showed neuroleukaemia. Biopsy of skin lesion revealed myeloid sarcoma. Cytogenetic analysis detected normal karyotype with FLT3 and NPM mutation. The patient was diagnosed as AML-M5, administered with induction therapy (DA Cytosar) and consolidation therapy (HiDAC) and she was successfully treated with allogeneic stem cell transplantation. She achieved and maintained complete remission.

**Conclusion:** Monoclonal plasmacytosis of BM should be carefully examined due to possible association with other haematological malignancies.

BMWS-P-19

## Diffuse large B-cell lymphoma with primary involvement of the bone marrow presenting with cold agglutinin disease. A case report.

George Kanellis<sup>1</sup>, Ekaterini Xirokosta<sup>2</sup>, Leonidas Marinos<sup>1</sup>, Despoina Barbarousi<sup>2</sup>, Asimina Papanikolaou<sup>1</sup>  
*<sup>1</sup>Hematopathology Dpt, Evangelismos Hospital, <sup>2</sup>Hematology Dpt, Alexandras Hospital, Athens, Greece*

**Background:** Cold agglutinin disease (CAD) is a rare disorder accounting approximately for 15% of autoimmune hemolytic anemia (AIHA) cases. It is often resistant to treatment and may be associated with an underlying lymphoproliferative disorder-mostly small B-cell lymphomas. Herein we describe a case of diffuse large B-cell lymphoma (DLBCL,NOS) with primary involvement of the bone marrow presenting with CAD.

**Principals/Methodology:** An 83-year-old female was admitted with severe anemia (Hct~18%) and loss of consciousness. She was diagnosed with AIHA seven months prior and was treated with corticoids ever since. At admission, Direct Agglutinin Test (DAT) was positive for C3d only (IgG-), and cold agglutinin titer was 1:128 at 4°C. She had an unremarkable medical history. No lymphocytosis was present. The CT scans (chest, abdomen) were negative for lymphadenopathy and organomegaly. A bone marrow biopsy was performed (BMB).

**Results:** Histology: hypercellular marrow with excessive erythroid proliferation and a lymphomatous infiltration accounting for approximately 20% of the marrow cell population consisting of large B- [CD20+, CD79a+, PAX5+, MUM1+, bcl6+ (weak expression), bcl2+<20%, MYC<10%, CD30-, CD10-, CD5-, CD15-, CD3-, EBER-] cells with diffuse and paratrabecular pattern without bone trabeculae infiltration.

Diagnosis: DLBCL,NOS with primary involvement of the bone marrow.

Due to her advanced age, Rituximab plus chemotherapy was not initially considered, and she underwent therapy with 6 cycles of Rituximab and corticoids. Follow up: normalized blood indices; BMB and MRI is pending.

**Conclusion:** Bone marrow involvement by DLBCL,NOS as part of systemic dissemination is a common event. Nevertheless, bone marrow as the primary site of DLBCL,NOS presentation is rare. In this report, we present a case of primary bone marrow DLBCL, NOS which fulfills the recently defined criteria of primary bone marrow B- cell lymphomas. In addition, CAD was the presenting clinical manifestation. Cold agglutinin disease is often refractory to treatment and often linked to an underlying lymphoproliferative disorder mainly lymphoplasmacytic lymphoma. Only three cases of primary bone marrow DLBCL, NOS presenting with CAD have been reported in the literature, as separate case reports. Our case adds to the clinical presentation of primary bone marrow DLBCL, NOS, making thus BMB an important diagnostic tool in refractory CAD.



BMWS-P-20

## Ki-67 in primary myelofibrosis: proliferative activity of megakaryocytes

Dmitrii A. Diakonov<sup>1</sup>, Nadezhda Fedorovskaya<sup>1</sup>, Elena Fokina<sup>2</sup>

<sup>1</sup>*laboratory of pathomorphology, <sup>2</sup>hematology, Federal State Budgetary Institution of Science "Kirov Research Institute of Hematology and Blood Transfusion of Federal Medical and Biologic Agency", Kirov, Russian Federation*

**Background:** Ki-67 is a nuclear protein that present in mid G1, S, G2 and the entire M-phase of the cell cycle. Immune staining with this antibody is a widely accepted method for evaluating proliferative activity of cells in a variety neoplasia's. Given that primary myelofibrosis is a clonal disease with a change in the level of proliferation of hematopoiesis germs, our study was aimed at evaluating its activity.

**Principals/Methodology:** Histological sections of bone marrow from primary myelofibrosis patients were analyzed depending on the stage of disease. Studies carried out using a set of methods: histological and morphometric.

**Results:** Revealed that the proportion of Ki-67 positive megakaryocytes in patients is significantly higher in comparison with the norm:  $11.5 \pm 1.5\%$  and  $4.0 \pm 0.9\%$  respectively ( $p = 0.014$ ). A relationship was found between the increase in the number of these cells and the stage of the disease. With overt primary fibrosis the number of megakaryocytes with expression of Ki-67 was higher ( $9.8 \pm 2.2\%$ ) compared to initial pre-fibrotic/early stage ( $12.5 \pm 1.7\%$ ).

**Conclusion:** Probably, a higher content of Ki-67 positive megakaryocytes reflects an unfavorable prognosis of the pathological process. Nevertheless, further studies and studies on the possibility of combining the value of Ki-67 proliferative activity with existing prognostic factors are required to confirm the results.

BMWS-P-21

## Necrotizing lymphadenopathy with prominent Azzopardi effect in autoimmune disorder possible systemic lupus erythematosus fulminant.

Ruijun J. Su<sup>\*1</sup>, Mingyi Chen<sup>2</sup>

<sup>1</sup>*University of California at Davis, Sacramento, <sup>2</sup>UT Southwestern Medical Center, Dallas, United States*

**Background:** A 40-year-old female with a history of Reiter's syndrome was admitted due to episodic spiking fevers, erythematous, blanching rash, and profound hypotension requiring pressor support, leukocytosis, and arthralgia/arthritis. She was found to have non-painful enlarged bilateral cervical lymph nodes. Laboratory study: ANA 1:40 (speckled), elevated inflammatory markers (ESR > 100), elevated liver enzymes (AST: 230, ALT: 65, ALK: 280), profound microcytic anemia (MCV: 73). CT showed possible fibrosis at the bilateral lung bases. A clinical concern for systemic lupus erythematosus purpura fulminans versus macrophage activation syndrome was raised.

**Principals/Methodology:** Bone marrow, lymph node and skin H&E histology examination, Immunohistochemistry, Flow Cytometry and Cytogenetics.

**Results:** Sections of the lymph node show extensive necrosis in the paracortex. In the necrotic area, there are prominent basophilic hematoxylin bodies surrounding the small blood vessels. The residual viable lymphoid tissues show marked lymphoid depletion. Occasionally, the small blood vessels within a necrotic area exhibit Azzopardi type changes. No viral inclusion is identified. Special stains including AFB,

GMS, PAS, GRAM, Wathin-Starry for micro-organisms are also negative. Bone marrow culture for bacteria, fungi are negative. Mildly hypercellular marrow and slightly left shifted granulopoiesis. The increased immature myeloid precursors are highlighted by with CD117 (nearly 10%) immunohistochemistry. No overt dysplasia is detected. Increased reactive histiocytes with focal aggregates and focal fibrinoid vasculopathy are also noted. No vasculitis is seen in skin lesions. Dilated vascular spaces with fibrin deposition intraluminally, histologic differential diagnosis includes infection (i.e. sepsis) or coagulopathy. By bone marrow flow cytometry, no evidence of aberrant antigen expression, of abnormal T-cells, or of monoclonal B-cells. No increase immature myeloid precursors or blast is detected.

**Conclusion: Proposed Diagnosis:** Necrotizing reactive lymphadenopathy with prominent Azzopardi effect associated with autoimmune disorder possible systemic lupus erythematosus.

**Category For Workshop:** Bone marrow symposium, Non-neoplastic lymphoproliferative in the bone marrow by lymphoproliferative disorders related to autoimmunity, non-transplant iatrogenic conditions and aging.





# Lymphoma Symposium

---

Oral Presentations (LYS-O-1-1 – LYS-O-7-4)

## Lymphoma Symposium

### Oral Presentations (BMS-O-1 – BMS-O-4)

LYS-O-1-1

### Novel GPR34 and CCR6 mutation and distinct genetic profiles in MALT lymphomas of different sites

Sarah Moody<sup>1</sup>, Joe S. Thompson<sup>1</sup>, Shih-Sung Chuang<sup>2</sup>, Hongxiang Liu<sup>3</sup>, Markus Raderer<sup>4</sup>, George Vassiliou<sup>5</sup>, Iwona Wlodarska<sup>6</sup>, Fangtian Wu<sup>1</sup>, Sergio Cogliatti<sup>7</sup>, Alistair Robson<sup>8</sup>, Margaret Ashton-Key<sup>9</sup>, Yingwen Bi<sup>10</sup>, John Goodlad<sup>11</sup>, Ming-Qing Du\*<sup>1,12</sup>

<sup>1</sup>Department of Pathology, University of Cambridge, Cambridge, United Kingdom, <sup>2</sup>Department of Pathology, Chi-Mei Medical Centre, Tainan, Taiwan, <sup>3</sup>Molecular Malignancy Laboratory, Cambridge University Hospitals NHS Foundation Trust, Cambridge, United Kingdom, <sup>4</sup>Department of Medicine I, Medical University of Vienna, Vienna, Austria, <sup>5</sup>The Genomic Research Group, The Wellcome Trust Sanger Institute, Cambridge, United Kingdom, <sup>6</sup>Center for Human Genetics, KU Leuven, Leuven, Belgium, <sup>7</sup>Institute of Pathology, State Hospital St. Gallen, St. Gallen, Switzerland, <sup>8</sup>Department of Dermatopathology, St John's Institute of Dermatology, London, <sup>9</sup>Department of Cellular Pathology, Southampton University Hospitals National Health Service Trust, Southampton, United Kingdom, <sup>10</sup>Department of Pathology, Eye & ENT Hospital, Fudan University, Shanghai, China, <sup>11</sup>Department of Pathology, Western General Hospital, Edinburgh, <sup>12</sup>Molecular Malignancy Laboratory, Addenbrooke's Hospital, Cambridge University Hospitals NHS Foundation Trust, Cambridge, United Kingdom

**Background:** MALT lymphoma originates from a background of diverse chronic inflammatory disorders at various anatomic sites. The genetics underlying its development, particularly in those of salivary gland and thyroid, are poorly characterised.

**Principals/Methodology:** A total of 21 cases of MALT lymphomas of the salivary gland and thyroid were investigated by whole exome sequencing (WES) for mutation discovery. The shortlisted genes were screened for mutation in 249 cases of MALT lymphoma from various anatomic sites by Fluidigm PCR and Illumina MiSeq sequencing. The rearranged IGH genes were analysed by BIOMED-2 PCR and Sanger sequencing.

**Results:** WES analyses of 21 cases of MALT lymphomas of the salivary gland and thyroid identified recurrent somatic mutations in 2 G-protein coupled receptors (GPR34 and CCR6) not previously reported in human malignancies, 3 genes (PIK3CD, TET2, TNFRSF14) not previously implicated in MALT lymphoma, and a further 2 genes (TBL1XR1, NOTCH1) recently described in MALT lymphoma. The majority of mutations in GPR34 and CCR6 were nonsense and frameshift changes clustered in the C-terminal cytoplasmic tail, and would result in truncated proteins that lack the phosphorylation motif important for  $\beta$ -arrestin mediated receptor desensitization and internalisation. Screening of these newly identified mutations, together with previously defined genetic changes, revealed distinct mutation profiles in MALT lymphoma of various sites, with those of salivary gland characterised by frequent TBL1XR1 and GPR34 mutations, thyroid by frequent TET2, TNFRSF14 and PIK3CD mutations, and ocular adnexa by frequent TNFAIP3 mutation. Interestingly, in MALT lymphoma of the salivary gland, there was a significant positive association



between TBL1XR1 mutation and GPR34 mutation/translocation ( $P=0.0002$ ). In those of ocular adnexa, TBL1XR1 mutation was mutually exclusive from TNFAIP3 mutation ( $P=0.049$ ), but significantly associated with IGHV3-23 usage ( $P=0.03$ ) and PIK3CD mutation ( $P=0.009$ ).

**Conclusion:** These findings unravel novel insights into the molecular mechanisms of MALT lymphoma and provide further evidence for potential oncogenic cooperation between receptor signalling and genetic changes.

LYS-O-1-2

## High-throughput sequencing of nodal marginal zone lymphomas identifies recurrent BRAF mutations

Darius Juskevicius<sup>1</sup>, Vincent Pillonel<sup>1</sup>, Charlotte K. Y. Ng<sup>1</sup>, Andrea Bodmer<sup>2</sup>, Andreas Zettl<sup>3</sup>, David Jucker<sup>1</sup>, Stefan Dirnhofer<sup>1</sup>, Alexandar Tzankov<sup>1</sup>

<sup>1</sup>Institute of Pathology and Medical Genetics, University Hospital of Basel, Basel, <sup>2</sup>Institute of Pathology, Cantonal Hospital Baselland, Liestal, <sup>3</sup>Pathology, Viollier AG, Basel, Switzerland

**Background:** Nodal marginal zone B cell lymphoma (NMZL) is a rare disease which represents less than 2% of all lymphoid neoplasms and ~10% of marginal zone B cell lymphomas (MZLs). NMZL has no disease-defining phenotype and its diagnostic borders to follicular lymphoma (FL) and other small B-cell lymphomas (SBCLs) are blurred. Owing to its rarity only a couple of studies have been performed to characterize its genetic features. Advanced understanding of the molecular pathology of NMZL may lead to more accurate diagnosis, reveal novel prognostic markers and improve treatment.

**Principals/Methodology:** We performed whole exome sequencing, targeted high-throughput sequencing (HTS) and array-CGH to characterize the genetic background of NMZL ( $n=25$ ). We also performed targeted HTS on cohorts of extranodal MZL ( $n=32$ ), splenic MZL ( $n=12$ ), lympho-plasmacytic lymphomas (LPL) ( $n=11$ ) and a comprehensive meta-analysis of gene mutation frequencies to pinpoint differential genetic events between NMZL and other closely related entities. We applied the results of meta-analysis on 16 ambiguous SBCL cases to test if mutational data can supplement the clinico-pathological characterization.

**Results:** We found that NMZL has more mutations compared to other MZLs (mean 5.4 vs 2.6,  $p=0.012$ ). Genes involved in epigenetic regulation (KMT2D, CREBBP, EZH2, TET2), NOTCH signaling (TBL1XR1, DTX1, NOTCH1) and p53 signaling (FAS, YY1) were among the most frequently mutated in NMZL. Surprisingly, in our cohort of NMZL we found recurrent clonal and sub-clonal BRAF mutations: three cases had a V600E hotspot mutation and one case had two co-occurring oncogenic variants - N581I and L597Q. Meta-analysis of gene mutation frequencies between entities revealed that mutations in CREBBP, FAS, EZH2, TET2, BRAF, DTX1 and CARD11 occur predominantly in NMZL and may be useful for differentiating this entity from other SBCLs (Figure 1). Detection of differentially occurring genetic aberrations improved classification of 12/16 ambiguous SBCL cases.

**Conclusion:** Until now, it was thought that among B-cell neoplasms the BRAF V600E mutation is almost entirely restricted to hairy cell leukemia. Detection of mutant BRAF in NMZL may open new opportunities in diagnostics and targeted therapy. Our study also suggests that gene mutational pattern in SBCL may be applied to better classify ambiguous cases, in which clinical, morphological and phenotypical features are equivocal.

## Image:

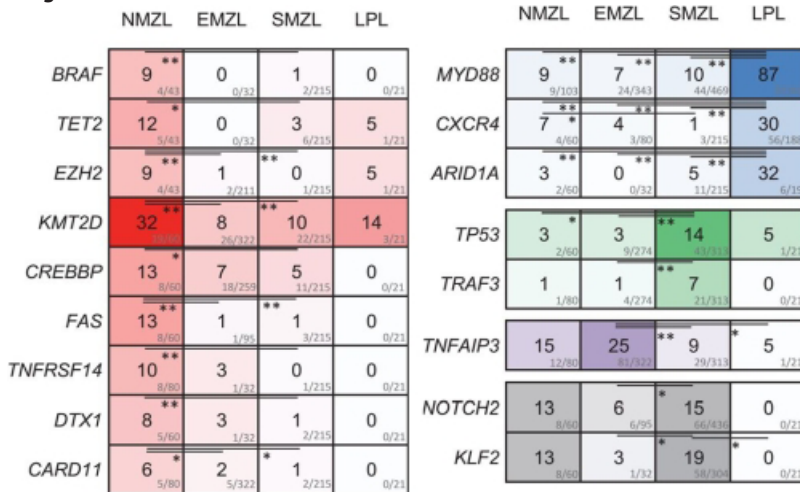


Figure 1. Meta-analysis of gene mutations in small B-cell lymphomas

LYS-O-1-3

**Clonality assessment of disseminated malt lymphoma.**

Fina Climent<sup>1</sup>, Davinia Fernandez<sup>1</sup>, Maria Condom<sup>2</sup>, Mar Varela<sup>3</sup>, Maria Pané<sup>1</sup>, Eva Gonzalez-Barca<sup>2</sup>, Anna Sureda<sup>2</sup>, Eva Domingo<sup>2</sup>

<sup>1</sup>Pathology, Hospital Universitari de Bellvitge-IDIBELL, <sup>2</sup>Hematology, <sup>3</sup>Pathology, Institut Català d'Oncologia, L'Hospitalet de Llobregat, Spain

**Background:** Extranodal mucosa-associated lymphoid tissue (MALT) lymphomas account for 7-8% of all non Hodgkin lymphomas, the stomach being the most frequent location. It is a disseminated disease in approximately 50% of extragastric MALT lymphomas, and 25% of gastric ones. There is very little literature published about the clonal relationship of MALT lymphomas with disseminated involvement.

Our aim was to study clonality of our disseminated MALT lymphomas.

**Principals/Methodology:** We reviewed all the cases of MALT lymphoma diagnosed at a single centre between 2009 and 2017. Cases that affected multiple locations were selected, both multifocal and multiorgan, excluding those with exclusive skin involvement. Clonality was detected by PCR for IGH (FR3 and FR2), and for IGK.

**Results:** Our series comprised 80 patients. Twenty seven (34%) presented with disseminated involvement. Those cases, 13 male and 14 females, presented with a median age of 60 years (range: 38-84). The most frequent involved primary locations were salivary gland (18.5%), lymph nodes (15%) and stomach (11%). Disseminated disease was present in 27 (34%) patients: one (4%) patient had multifocal MALT; 22 (81%) patients had multiorgan MALT; and 4 (15%) patients had both. All patients received treatment: 23 (85%) patients received chemotherapy, 2 (7%) radiotherapy, 1 (4%) surgery, and 1 (4%) chemotherapy plus surgery.



Clonality was analyzed in 52 samples from 24 different patients. We could compare clonality in 16 patients. In 6 of them (22%), the neoplastic clones were distinct and unrelated.

**Conclusion:** This is the largest series that compares clonality in disseminated MALT lymphoma. Our results suggest that in an important percentage of cases, the rearrangements are not clonally related.

LYS-O-1-4

## Primary CNS Small B-cell Neoplasms

Laila Nomani<sup>1</sup>, Claudiu V. Cotta<sup>1</sup>, Eric D. Hsi<sup>1</sup>, James R. Cook<sup>1</sup>

<sup>1</sup>Cleveland Clinic, Cleveland, United States

**Background:** Primary lymphomas of the central nervous system (CNS) are most commonly diffuse large B cell lymphomas which arise within brain parenchyma. Small B cell neoplasms presenting in the CNS are rare. Following diagnosis of an unusual index case, we have reviewed CNS small B-cell neoplasms at our institution in an effort to further characterize these uncommon tumors.

**Principals/Methodology:** An electronic search of the Cleveland Clinic pathology database from 2004-2018 for the diagnosis of CNS lymphomas yielded 194 cases. All available routine and immunohistochemistry (IHC) slides were reviewed for cases diagnosed as small B cell lymphomas of the CNS. Intraocular lymphomas were not included.

**Results:** Of 194 cases of CNS lymphoma, 20 small B cell neoplasms were identified. After exclusion of two cases of systemic lymphomas with secondary involvement of the CNS (1 chronic lymphocytic leukemia/small lymphocytic lymphoma, 1 lymphoplasmacytic lymphoma), 18 primary CNS small B-cell neoplasms were identified. Review by current WHO criteria identified 10 extranodal MALT lymphomas and 8 follicular lymphomas (FL). The FL cases involved dura of the skull (n=3) or spine (n=5). The 10 cases of MALT could be separated into two groups. Six cases involved the dura or choroid plexus, with imaging studies demonstrating a mass lesion suggestive of meningioma. Histologically, these cases showed a lymphoid mass lesion composed of predominantly small lymphocytes. Plasma cells were rare (<5% of cellularity) and polytypic by IHC. Four cases involved brain parenchyma with a perivascular growth pattern without a lymphoid mass lesion, although one case contained a dominant mass of Congo Red negative proteinaceous material. Cytologically, these cases showed prominent plasma cells (30-50% of cellularity) which were monotypic in 3 cases (75%). PCR was negative for MYD88 L265P mutations in 2/2 cases studied.

**Conclusion:** Primary CNS small B-cell neoplasms consist predominantly of extranodal MALT lymphoma and FL. MALT lymphomas involving the dural/choroid tissues differ histologically from cases involving brain parenchyma. Additional molecular studies are ongoing to further evaluate these two groups of CNS MALT. This study clarifies the spectrum of pathologic findings in primary CNS small B-cell neoplasms.

LYS-O-2-1

## DLBcl: microenvironmental signature along with coo identifies different risk groups

Federica Melle\*<sup>1</sup>, Giovanna Motta<sup>1</sup>, Marco Fabbri<sup>1</sup>, Sabino Ciavarella<sup>2</sup>, Maria C. Vegliante<sup>2</sup>, Simona De Summa<sup>3</sup>, Valentina Tabanelli<sup>1</sup>, Anna Enjuanes<sup>4</sup>, Alessandro Gulino<sup>5</sup>, Stefania Tommasi<sup>3</sup>, Elias Campo<sup>6</sup>, Claudio Tripodo<sup>5</sup>, Attilio Guarini<sup>2</sup>, Stefano A. Pileri<sup>1</sup>

<sup>1</sup>Unit of Diagnostic Haematopathology, European Institute of Oncology, Milano, <sup>2</sup>Hematology and Cell Therapy Unit, <sup>3</sup>Molecular Diagnostics and Pharmacogenetics Unit, IRCCS-Istituto Tumori 'Giovanni Paolo II', Bari, Italy, <sup>4</sup>Genomic Unit, Institute of Biomedical Research August Pi i Sunyer (IDIBAPS), Barcelona, Spain, <sup>5</sup>Tumor Immunology Unit, Dipartimento per la Promozione della Salute e Materno Infantile "G. D'Alessandro", Palermo, Italy, <sup>6</sup>Haematopathology Unit, Pathology Department, Hospital Clínic, University of Barcelona and Institute of Biomedical Research August Pi i Sunyer (IDIBAPS), Barcelona, Spain

**Background:** Diffuse large B cell lymphoma (DLBCL) includes a large group of disease entities with high molecular heterogeneity and variable treatment responsiveness. Gene expression profiling (GEP) uncovered prognostic gene sets linked to the nature of the tumor but failed in recognizing definite target cell populations of the tumor microenvironment endowed with prognostic significance.

**Principals/Methodology:** We generated a customized signature matrix including 1,028 genes to distinguish 17 cell types of both immune and stromal origin. The matrix was used to run a CIBERSORT deconvolution of two publicly available GEP datasets of overall 482 DLBCLs. In silico stratification of cases according to clinical outcome revealed significant differences among proportions of putative tumor-infiltrating cell types, whose related genes were selected and incorporated in a 45-gene panel. We applied NanoString technology to validate the prognostic power of the panel in a set of 203 formalin-fixed, paraffin-embedded samples from advanced-stage patients treated with comparable first-line regimens.

**Results:** CIBERSORT data analyzed in relation to clinical outcome revealed that the cases with higher proportions of MF, DC and CD4+ T-cells showed significantly longer OS, whereas activated NK and plasma cells (PC) were more represented in patients with poorer outcome.

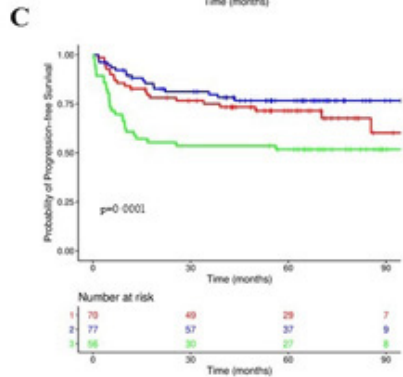
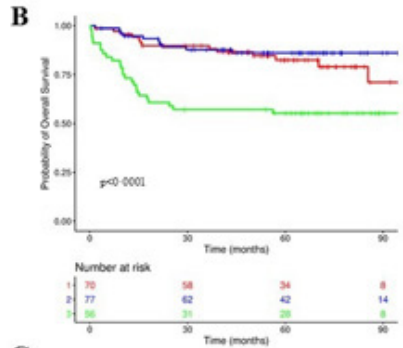
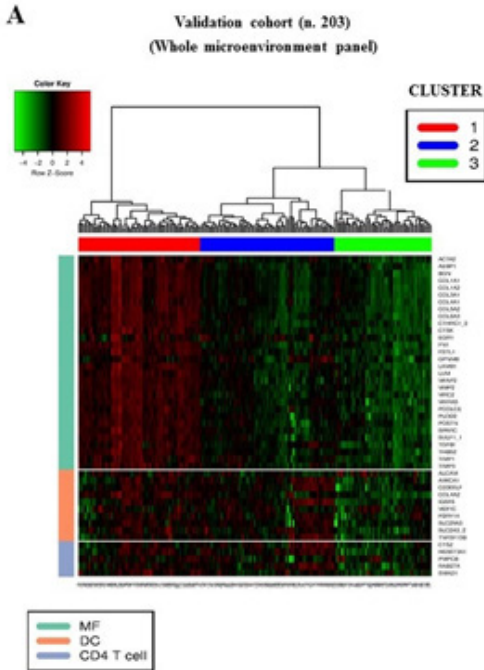
The list of the most expressed genes was filtered by choosing only those genes that, consistently with the prognostic significance of the related cytotypes, had a significantly different expression between "poor" and "good" outcome subgroups and a selection of 45 transcripts was used to define the microenvironment panel for subsequent validation.

Unsupervised clustering analysis stratified cases into three different subgroups with high, intermediate and low expression of genes included in the panel (Figure 1). Interestingly, the prognostic value of microenvironment genes was independent of cell of origin categorization, and integration of the two models remarkably improved survival prediction.

**Conclusion:** Our computational dissection of DLBCL microenvironment allowed the identification of distinct prognostic categories and provided an easy-to-apply gene panel that powerfully predicts patient survival. Moreover, owing to its relation with specific stromal and immune components, the panel may acquire a predictive relevance in clinical trials exploring new drugs with known impact on DLBCL microenvironment.



Image:



LYS-O-2-2

## PDL1 and PDL2 expression in primary diffuse large B cell lymphoma (DLBCL) of the CNS

Maysaa Abdulla<sup>1</sup>, Christer Sundström<sup>1</sup>, Peter Hollander<sup>1</sup>, Mattias Berglund<sup>2</sup>, Gunilla Enblad<sup>3</sup>, Rose-Marie Amini<sup>1</sup>

<sup>1</sup>Department of pathology, Uppsala university hospital, Uppsala, <sup>2</sup>Department of Biosciences and Nutrition, Karolinska Institute, Stockholm, <sup>3</sup>Department of Oncology, Uppsala university hospital, Uppsala, Sweden

**Background:** The prognostic value of biomarkers in systemic DLBCL is not valid in primary DLBCL in CNS (PCNSL). Programmed cell death 1 (PD1) and its ligands PDL1 and PDL2 constitute an immune checkpoint pathway that allows escape of tumour cells from immune surveillance. Both tumour cells and leukocytes may express PD1 and its ligands and the prognostic impact of PD1, PDL1 and PDL2 in PCNSL is still unclear

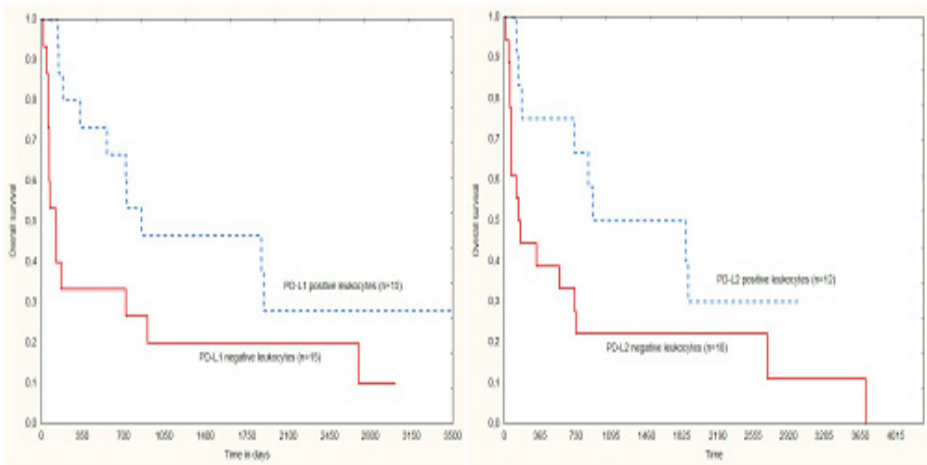
**Principals/Methodology:** 132 PCNSL cases diagnosed in Uppsala University Hospital (1996-2015) were included. IHC stainings of TMA for PD1, PDL1/PAX5, PDL2/PAX5 and in situ hybridization for EBER (n=45) were investigated. PD1, PDL1 and PDL2 as a ratio between positive tumour cells (TC)/all TC and positive

TC/all cells were analysed. Leukocytes were calculated as a ratio between positive leukocytes/all leukocytes and positive leukocytes/all cells for PDL1 and PDL2, while PD1 positive tumour infiltrating lymphocytes (TIL) were calculated as positive TIL per HPF. The proportions of PD1, PDL1 and PDL2-positive cells were estimated manually and validated with a computerized image analysis. Optimal cutoffs were determined by ROC curves. Overall survival (OS) was estimated with Kaplan-Meier and differences with log-rank test. Only curatively treated patients were included in the survival analyses (n=79).

**Results:** M:F ratio was 1.2:1, median age was 66 years. Younger age and better performance status were associated with better OS ( $p < .0001$ ,  $p = .0004$ ), as was treatment with Methotrexate ( $p = 0.02$ ). PD1 expression in TIL did not correlate to OS. PDL1 and PDL2 expression on TC did not correlate with OS but expression of PDL1 and PDL2 correlated with EBV-positive TC ( $p = .00003$ ). PDL1 expression  $>85\%$  in leukocytes/all leukocytes were detected in 15/30 (50%) patients and tended to be associated with better OS ( $p = .07$ ). High expression of PDL2 in leukocytes/all cells (cutoff 7.5%) were detected in 12/30 (40%) patients and had a tendency for better OS ( $p = .06$ ).

**Conclusion:** This is the first study to show that high expression of PDL1 and PDL2 on leukocytes tended to be associated with superior outcome in curatively treated patients with PCNSL. Hence, leukocytes in the tumour microenvironment of PCNSL appear to have tumour modulating abilities.

**Image:**





LYS-O-2-3

## The tumor microenvironment in Primary Central Nervous System Lymphoma

Lukas Marcellis<sup>1</sup>, Anne-Marie Delsupehe<sup>1</sup>, Pauline Biesemans<sup>1</sup>, Koen Debackere<sup>1</sup>, Gregor Verhoeft<sup>2</sup>, Olivier Gheysens<sup>3</sup>, Daan Dierickx<sup>2</sup>, Xavier Sagaert<sup>1</sup>, Thomas Tousseyn<sup>1</sup>

<sup>1</sup>Pathology, <sup>2</sup>Hematology, <sup>3</sup>Nuclear Medicine, UZ Leuven, Leuven, Belgium

**Background:** Primary central nervous system lymphoma (PCNSL) is a rare lymphoma with an aggressive clinical course and poor prognosis. The central nervous system (CNS) is an immune-privileged site, partially responsible for its unique clinical and pathological characteristics. Advances in the field of immunotherapy have led to increased interest in the cellular tumor microenvironment (TME) in different lymphoma subtypes, and also in PCNSL. Prognostic and predictive TME-specific biomarkers are however lacking in PCNSL.

**Principals/Methodology:** We performed an in-depth review of a selection of 36 excisional brain biopsies from a series of 126 patients with CNS lymphoma diagnosed at the University Hospitals Leuven, Belgium: 26 patients with PCNSL and 10 secondary CNS lymphomas. There were no significant differences in age and IELSG scores between groups. The tumor microenvironment was characterized with immunostainings against CD8, CD4, FoxP3, CD163, PD1, PDL1 and quantified in different regions (perivascular, diffuse intratumoral and peritumoral) using a digital image analysis system (Qupath©) of scanned images (Philips IntelliSite Ultra Fast Scanner ©).

**Results:** No significant differences were observed between TME in primary versus secondary CNS lymphoma. We observed two different pattern of tumor invasion: a predominantly diffuse and a predominantly angiocentric growth pattern, in which the cases with diffuse growing tumors were significantly correlated with a better survival ( $p = 0,015$ ).

A considerable spatial heterogeneity was observed for cytotoxic T-cells, T-helper lymphocytes and macrophages throughout the tumor components (intratumoral, peritumoral, perivascular). Significantly better survival was observed in cases with high CD8 count in the central intratumoral areas ( $p=0.008$ ) and high CD8/CD4 ratio in the perivascular region ( $p = 0,019$ ).

**Conclusion:** In a retrospective series of 36 CNS lymphomas we provide evidence for a prognostic significance of the growth pattern of the lymphoma and the spatial distribution of the infiltrating immune cells throughout different areas in the tumor.

LYS-O-2-4

## The microenvironmental landscape of extranodal natural killer/T-cell lymphoma

Junhun Cho<sup>1</sup>, Seok Jin Kim<sup>2</sup>, Won Seog Kim<sup>2</sup>, Young Hyeh Ko<sup>1</sup>

<sup>1</sup>Pathology, <sup>2</sup>Medicine, Samsung Medical Center, Seoul, Korea, Republic Of

**Background:** Extranodal natural killer/T-cell lymphoma (ENKTL) is an aggressive, life-threatening lymphoproliferative disorder and its pathogenesis is closely related to Epstein-Barr virus (EBV) infection. We aimed to elucidate the landscape of immune microenvironment of ENKTL.

**Principals/Methodology:** One hundred ENKTL patients were enrolled in this study, of which 63 tumors (63.0%) were biopsied in upper aerodigestive tract. We performed immunohistochemistry for immune-related markers including PD-L1, CD47, CD8, FoxP3, and S100 protein on whole section of all ENKTL cases.

As representative markers for M1 and M2 macrophages, we used CD68 and CD163, respectively. Double stains for PD-L1 immunohistochemistry and EBV in situ hybridization were done to clarify the difference of PD-L1 expression between tumor cells and peritumoral immune cells.

**Results:** PD-L1 was positive in tumor cells in 57 (57.0%) and 8 (8.0%) of ENKTL patients by cutoff of 1% and 10%, respectively. High CD68 group was significantly associated with younger age ( $P=0.023$ ), lower stage ( $P<0.001$ ), tumor located in upper aerodigestive tract ( $P=0.008$ ), no distant lymph node involvement ( $P=.037$ ), no bone marrow involvement ( $P<0.001$ ), and low risk of prognostic Index of natural killer cell lymphoma ( $P<0.001$ ). High CD68 group showed significantly longer overall survival than low CD68 group ( $P=0.006$ ). Although PD-L1, both on tumor cells and immune cells, was not an independent prognostic factor, high PD-L1/CD68 ratio was associated with better survival ( $P=0.019$ ). The cell count of CD163 and CD68:CD163 ratio revealed no correlation with prognosis, however, when CD163(+) cells were classified into dendritic and non-dendritic subtypes according to the predominant morphology of individual cells, only non-dendritic CD163(+) cells showed a tendency of pro-tumor effect ( $P=0.089$ ). In contrast, dendritic CD163(+) cells revealed significant anti-tumor effect ( $P<0.001$ ). CD47, CD8, and FoxP3 immunohistochemistry results are now being analyzed.

**Conclusion:** In this study, we first described the effect of M1 and M2 macrophages and dendritic cells on the clinical course in ENKTL patients. Our results provide insight into the immune microenvironment of ENKTL and a framework for application of targeted therapies in ENKTL patients.

LYS-O-3-1

## Mutational landscape of extranodal NK/T-cell lymphoma, nasal type from Latin America.

Ivonne A. Montes-Mojarro<sup>1</sup>, Julia Steinhilber<sup>1</sup>, Bo-Jung Chen<sup>1,2</sup>, Ana F. Ramirez-Ibarguen<sup>3</sup>, Carmen M. Quezada-Fiallos<sup>3</sup>, Wendy B. Pérez Báez<sup>3</sup>, Daniela Dueñas<sup>4</sup>, Sandro Casavilca-Zambrano<sup>4</sup>, Marcela Ortiz-Mayor<sup>5</sup>, Erica Rojas-Bilbao<sup>6</sup>, Hernan García-Rivello<sup>7</sup>, Maria F. Metrebian<sup>8</sup>, Marina Narbaitz<sup>8</sup>, Carlos Barrionuevo<sup>4</sup>, Carmen Lome<sup>3</sup>, Irina Bonzheim<sup>1</sup>, Falko Fend<sup>1</sup>, Leticia Quintanilla-Martinez<sup>1</sup>

<sup>1</sup>Institute of Pathology and Neuropathology, University Hospital and Comprehensive Cancer Center Tuebingen, Tuebingen, Germany, <sup>2</sup>Department of Pathology, Shuang-Ho Hospital, Tapei Medical University, New Tapei City, Taiwan, <sup>3</sup>Department of Pathology, Instituto Nacional de Cancerología, Mexico City, Mexico, <sup>4</sup>Department of Pathology, Instituto Nacional de Enfermedades Neoplásicas, Lima, Peru, <sup>5</sup>Department of Pathology, Hospital Ángel C. Padilla, San Miguel Tucumán, <sup>6</sup>Department of Pathology, Instituto de Oncología Ángel H. Roffo, <sup>7</sup>Department of Pathology, Hospital Italiano de Buenos Aires, <sup>8</sup>Department of Pathology, Instituto de Investigaciones Hematológicas, Academia Nacional de Medicina, Buenos Aires, Argentina

**Background:** Extranodal NK/T-cell lymphoma (ENKTCL) is an aggressive Non-Hodgkin lymphoma associated with Epstein Barr virus (EBV), prevalent in Asia and Latin America. Studies in Asian cohorts have identified recurrent mutations in ENKTCL; however, our understanding of the genomic landscape in ENKTCL remains incomplete and mutational status in Latin America is still unknown. The aim of this study was to investigate the mutational landscape in a series of ENKTCL cases from Latin America and compare it with Asian populations.

**Principals/Methodology:** We analysed 71 ENKTCL cases from 3 different centers in Latin America (42 from Mexico, 17 from Peru and 12 from Argentina). In all cases H&E stain, CD56, and EBER in situ hybridization were performed. NGS workflow based on a custom AmpliSeq panel designed for sequencing the most frequent mutated genes (STAT3, STAT5B, JAK3, DDX3X, TP53, MGA, MSN and BCOR) was applied using Ion Torrent PGM Sequencer. PCR analysis to identify EBV strain type and LMP1 30 bp deletion was performed.



**Results:** 58 mutations were identified in 43 (60.6%) cases. Mutations affecting the JAK-STAT signalling pathway were identified in 19 cases (27%); the most frequent mutated gene was STAT3, (16 cases; 22%). Mutations in STAT5B (1 case) and JAK3 (2 cases) were rarely identified. STAT3 mutations were located in the SH2 domains with hotspots in D661Y, N647I, Y640F leading to pSTAT3 expression. Inactivating mutations in BCOR and DDX3X were found in 11 (15%) and 6 (8.5%) cases, respectively. TP53 mutations were identified in 6 (8.5%) cases. Interestingly, mutations in STAT3, BCOR and DDX3X were mutually exclusive, highlighting different pathogenesis, whereas mutations in MGA, TP53, STAT5B and JAK3 co-occurred with other mutations (figure 1). Comparison of the mutation distribution between countries did not reveal differences, except for JAK3 mutations, which were only found in two Argentinian cases. EBV genotype showed that the majority of the cases were type A EBV and carried wild-type LMP1 gene (53/71; 75%). Type B EBV with LMP1 deletion was detected only in 3 Mexican cases.

**Conclusion:** ENKTCL in Latin America reveals frequent mutations leading to abnormal activation of the JAK-STAT pathway (27%), mainly STAT3 mutations. BCOR, DDX3X and TP53 mutations were also identified but with low frequencies. Type A EBV with LMP1 wild type was the most frequent strain found in Latin America. ENKTCL shows similar mutational landscape in Latin America and Asia, but with different frequencies.

**Image:**

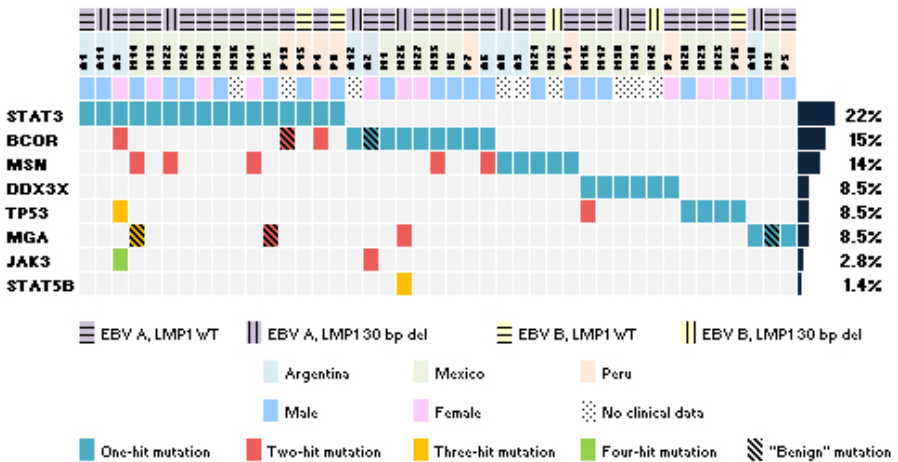


Figure 1. ENKTCL mutational landscape in Latin America

LYS-O-3-2

## NKp46 is a useful diagnostic biomarker in gastrointestinal T-cell lymphoproliferative diseases and constitutes a therapeutic target. A CELAC network study.

Julie Bruneau<sup>1</sup>, Morgane Cheminant<sup>2</sup>, Georgia Malamut<sup>3</sup>, David Sibon<sup>2</sup>, Nicolas Guegan<sup>4</sup>, Amelie Trinquand<sup>5</sup>, Sherine Khater<sup>3</sup>, Chris Mulder<sup>6</sup>, Elizabeth Macintyre<sup>5</sup>, Laurent Pouyet<sup>7</sup>, Cecile Bonnafous<sup>8</sup>, Florence Lhospipe<sup>8</sup>, Thierry Jo Molina<sup>1</sup>, Bertrand Meresse<sup>4</sup>, Christophe Cellier<sup>3</sup>, Nadine Cerf-Bensussan<sup>4</sup>, Olivier Hermine<sup>2</sup>

<sup>1</sup>Pathology, <sup>2</sup>Hematology, Hôpital Necker - Enfants Malades, <sup>3</sup>Gastroenterology, Hopital Européen Georges Pompidou, <sup>4</sup>INSERM UMR1163, Laboratory of Intestinal Immunity, Imagine Institute - Necker Enfants Malades, <sup>5</sup>biological hematology, Hôpital Necker - Enfants Malades, Paris, France, <sup>6</sup>Gastroenterology, VU University Medical Centre, Amsterdam, Netherlands, <sup>7</sup>MI-mAbs, <sup>8</sup>Innate Pharma, Marseille, France

**Background:** Primary gastrointestinal (GI) T-cell lymphoproliferative diseases (T-LPD) are heterogeneous entities, whose diagnoses, prognoses and therapeutic options remain to be standardized.

**Principals/Methodology:** NK receptors expression was assessed by flow-cytometry and immunohistochemistry on celiac disease (CD), refractory celiac diseases (RCDI and RCDII) and GI T-cell lymphomas (n=204), and on a validation cohort (n=61). An anti-NKp46 monoclonal antibody conjugated to pyrrolone benzodiazepine (PBD) was tested in-vivo in NOD-SCID mice engrafted with human NKp46-transfected Raji cells, and ex-vivo in human primary tumor cells isolated from fresh duodenal biopsies.

**Results:** NKp46 was the only NK receptor that distinguishes between RCDII and CD or RCDI. ROC analysis showed that more than 25 NKp46+ intraepithelial lymphocytes (IEL) per 100 epithelial cells could discriminate RCDII from CD and RCDI, and was associated with a shorter survival (OS-5years 74.8% vs. 96.4%, p=0.0007). In addition, NKp46 was expressed by almost all aggressive GI T-cell lymphomas, such as enteropathy-associated T-cell lymphomas (EATL, n=24/29) and monomorphic epitheliotropic intestinal T-cell lymphomas (MEITL, n=4/4) but never by indolent T-cell LPD (n=0/15). NKp46 expression was associated with shorter survival (OS-5years 5.4% vs. 46.8%, p=0.0023). Treatment with anti-NKp46-PBD promoted tumor regression and prolonged survival of mice bearing NKp46-transfected Raji tumors in-vivo, and could efficiently and selectively kill human NKp46+ primary IEL ex-vivo.

**Conclusion:** NKp46 is a novel biomarker useful for diagnosis, prognosis and therapeutic stratification of GI T-LPD. Strong preclinical rationale identifies anti-NKp46-PBD as a promising therapy for RCDII, EATL and MEITL.

## Angioimmunoblastic T-cell lymphoma contains multiple clonal T-cell populations derived from a common TET2 mutant progenitor cell

Wen-Qing Yao<sup>1,2</sup>, Wen-Yan Zhang<sup>1</sup>, Joe S. Thompson<sup>2</sup>, Shao-Wei Zhang<sup>2,3</sup>, Alex Clipson<sup>2</sup>, Ming Wang<sup>2</sup>, Hongxiang Liu<sup>4</sup>, Hani Bibawi<sup>4</sup>, John Grant<sup>5</sup>, Penny Wright<sup>5</sup>, Hesham El-Daly<sup>6</sup>, Livia Rásó-Barnett<sup>6</sup>, Lorant Farkas<sup>6</sup>, Zifen Gao<sup>3</sup>, Shih-Sung Chuang<sup>7</sup>, Margaret Ashton-Key<sup>8</sup>, Weiping Liu<sup>1</sup>, Ming-Qing Du<sup>\*2,4</sup>

<sup>1</sup>Department of Pathology, West China Hospital, Sichuan University, Chengdu, China, <sup>2</sup>Department of Pathology, University of Cambridge, Cambridge, United Kingdom, <sup>3</sup>Department of Pathology, Health Science Centre, Peking University, Beijing, China, <sup>4</sup>Molecular Malignancy Laboratory, <sup>5</sup>Department of Histopathology, <sup>6</sup>The Haematopathology and Oncology Diagnostic Service, Addenbrooke's Hospital, Cambridge University Hospitals NHS Foundation Trust, Cambridge, United Kingdom, <sup>7</sup>Department of Pathology, Chi-Mei Medical Center, Tainan, Taiwan, <sup>8</sup>Department of Cellular Pathology, Southampton University Hospitals National Health Service Foundation Trust, Southampton, United Kingdom

**Background:** The genetic changes in AITL can be grouped into two classes. Class-I changes involve mutations in epigenetic regulators including TET2, DNMT3A and IDH2, with TET2 mutations also seen in non-neoplastic B and CD8+ T-cells. Class-II changes affect molecules critical for T-cell biology, particularly those downstream of TCR signaling such as RHOA, VAV1 and PLCG1. To search for evidence of potential oncogenic cooperation between genetic changes and intrinsic TCR signaling, we studied somatic mutations and TCR beta (TRB) rearrangements in a series of T cell lymphoma.

**Principals/Methodology:** Somatic mutations in 8 lymphoma genes and TRB rearrangement were investigated in 78 AITL, 23 PTCL-TFH and 39 PTCL-NOS by Fluidigm PCR and Illumina MiSeq sequencing.

**Results:** We confirmed frequent TET2, DNMT3A and RHOA mutations in AITL (77%, 30%, 45%) and PTCL-TFH (57%, 26%, 22%) and showed multiple TET2 mutations (2-3) in 62% of the involved cases. Clonal TRB rearrangement was seen in 62 cases with multiple functional rearrangements (2-4) in 19 cases (30%) including 11 AITL, 3 PTCL-TFH and 5 PTCL-NOS. The number of cases with multiple functional TRB rearrangements was higher in cases with multiple TET2 mutations (9/28=32.1%) than those with a single TET2 mutation (7/34=20.5%) albeit not statistically significant. Among these cases, one case, which harbored 2 TET2 and 2 DNMT3A mutations, had 4 functional TRB rearrangements. In two selected cases, a series (n=100) of small clusters of tumour cells were microdissected and investigated for the respective TRB rearrangements and TET2 mutations. In one case, non-supervised hierarchical clustering analysis showed two clusters, each with one TRB rearrangement significantly associated with one TET2 mutation, suggesting the presence of two independent clonal T-cell populations. Finally, in comparison with tonsillar TFH cells, both AITL and PTCL-TFH showed a significant over-representation of several TRB variable family members, particularly TRBV19\*01. Of the 16 TRBV19\*01 functional rearrangements seen in AITL and PTCL-TFH, 8 involved TCR βJ2-1, with two cases showing a nearly identical VDJ junctional sequence.

**Conclusion:** Our findings demonstrate the presence of more than one clonal T cell population in a high proportion of AITL and PTCL-TFH. The biased TRBV usage in these lymphomas suggests that the intrinsic properties of TCR may play an important role in predilection of T cells to clonal expansion and malignant transformation.

LYS-O-3-4

## Angio-Immunoblastic T-cell Lymphoma and Chronic Myelomonocytic Leukemia: a non-fortuitous association arising from precursor hematopoietic cells with acquired TET2 mutations

Francois Lemonnier<sup>1</sup>, Pierre Sujobert<sup>2</sup>, Julie Abraham<sup>3</sup>, Clementine Sarkozy<sup>2</sup>, Bruno Tesson<sup>4</sup>, Morgane Cheminant<sup>5</sup>, Clémence Loiseau<sup>6</sup>, Alexandra Traverse-glehen<sup>2</sup>, Richard Delarue<sup>5</sup>, Mauela Delage<sup>3</sup>, Julie Bruneau<sup>5</sup>, Arnaud Jaccard<sup>3</sup>, Olivier Hermine<sup>5</sup>, Gilles Salles<sup>2</sup>, Philippe Gaulard<sup>7</sup>

<sup>1</sup>Unité Hémopathies Lymphoïdes, Henri Mondor hospital, Créteil, <sup>2</sup>Hospices Civils de Lyon, Pierre Bénite, <sup>3</sup>CHU Limoges, Limoges, <sup>4</sup>CALYM, Pierre Bénite, <sup>5</sup>Hopital Necker, Paris, <sup>6</sup>IMRB, <sup>7</sup>Henri Mondor hospital, Créteil, France

**Background:** Inactivating TET2 mutations, affecting the DNA methylation pathway, have been described in various hematological neoplasms. They are especially frequent in 2 diseases: angioimmunoblastic T cell lymphoma (AITL) and chronic myelomonocytic leukemia (CMML) where they are detected in up to 80 and 60% cases, respectively. They are associated with other mutations affecting the DNA methylation (DNMT3A, IDH) in both disease and with mutations encoding RHOA<sup>G17V</sup>, or affecting the TCR signaling in AITL, or mutations affecting ASXL1 or genes from spliceosome in CMML. Therefore, an association between CMML and AITL might be expected.

**Principals/Methodology:** Within the framework of the TENOMIC T-cell research program of the LYSA, 5 patients who developed both AITL and CMML were identified, including 2 who have previously been reported (PMID: 25312805 and PMID: 27353473). Whole exome sequencing (WES) (300X) was performed on CD14+ CMML cells and on sorted ICOS+PD1+ CD3+ CD4+/- AITL cells, as well as in hair follicle, in 2 patients (PTCL 10 and 13).

**Results:** Patients characteristics are described in Figure 1. Briefly, patients had a median age of 79 (75-81), median monocyte count was 2.1 G/L (1.5-2.3), and bone marrow karyotype was normal in all patients. CMML diagnosis preceded AITL in 1 patient, was concomitant in 2 and was made after AITL in 2 patients. After multiple therapeutic regimen, including 5 azacytidine in the 5 patients, 5 year overall survival was 40%.

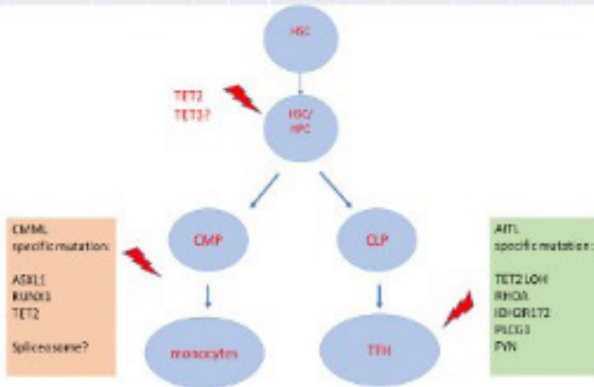Aiming to decipher the molecular mechanism of this association, we performed WES in myeloid and lymphoid tissues of 2 patients. In PTCL10, we detected 2 TET2 and 1 TET3 mutations, both in CD14 + CMML cells and in AITL tumor, whereas RHOA and PLCG1 mutations were detected only in AITL tumor. In PTCL 13, we detected a common TET2 mutation (R1216X) in both disease whereas RHOA<sup>G17V</sup>, IDH2<sup>R172S</sup> and FYN were restricted to sorted AITL cells, and TET2<sup>Q778X</sup>, ASXL1 and RUNX1 were restricted to CMML cells. Interestingly, TET2<sup>Q778X</sup> was detected by targeted deep sequencing in AITL tumor, while undetected in AITL tumor cells, suggesting that some TET2 mutations detected in AITL lymph node can occasionally be restricted to microenvironment cells.

**Conclusion:** This study emphasizes the occurrence of both CMML and AITL in some patients likely arising from a reservoir of TET2 mutated hematopoietic precursor cells, from which additional disease specific mutations occur in a multistep process to drive the oncogenesis of AITL and CMML.



Image:

ID	Sex	Age	CMML					AITL					status at last follow up	follow up (month hs)	
			monocyte count (G/L)	BM Karyo type	BM blast s%	Stage	LDH	EC OG	IP1	TET2 mutation	RHOA mutation	DNMT 3A mutation			IDH2 mutation
PTO10	F	81	1,5	N	<5%	4	1	2	3	2	G17V	0	0	D	27
PTO2	F	85	1,3	N	6	4	0	4	3	2	G17V	R182H	0	D	18
PTO7	M	75	2,3	N	2	3	1	0	2	1	0	0	0	A	75
PTO3	F	79	2,1	N	7	3	1	2	4	2	0	0	0	A	61
PTO11	M	60	2,7	N	<5%	3	0	1	2	1	G17V	0	R172S	D	18



LYS-O-4-1

## Gene Expression Profile distinguishes Breast Implant-Associated Anaplastic Large Cell lymphoma from other Peripheral T-cell Lymphomas

Arianna Di Napoli<sup>1</sup>, Loris De Cecco<sup>2</sup>, Pier Paolo Piccaluga<sup>3</sup>, Mohsen Navari<sup>4</sup>, Valeria Cancila<sup>5</sup>, Claudia Cippitelli<sup>6</sup>, Giuseppina Pepe<sup>6</sup>, Gianluca Lopez<sup>6</sup>, Francesca Monardo<sup>7</sup>, Antonella Bianchi<sup>8</sup>, Emanuele S. D'Amore<sup>9</sup>, Umberto Gianelli<sup>10</sup>, Fabio Facchetti<sup>11</sup>, Govind Bhagat<sup>12</sup>

<sup>1</sup>Department of Clinical and Molecular Medicine, Sapienza University of Rome, Sant'Andrea Hospital, Roma, <sup>2</sup>Istituto Tumori Milano, Milan, <sup>3</sup>Bologna University, Bologna, Italy, <sup>4</sup>Torbat Heydariyeh University of Medical Sciences, Torbat, Iran, Islamic Republic Of, <sup>5</sup>University of Palermo, Palermo, <sup>6</sup>Sapienza University of Rome, <sup>7</sup>San Giovanni Addolorata Hospital, <sup>8</sup>University Hospital Campus Bio-Medico, Roma, <sup>9</sup>San Bortolo Hospital, Vicenza, <sup>10</sup>IRCCS Ca' Granda Ospedale Maggiore Policlinico, University of Milan, Milan, <sup>11</sup>University-Spedali Civili of Brescia, Brescia, Italy, <sup>12</sup>Columbia University Medical Center, New York Presbyterian Hospital, New York, United States

**Background:** Breast implant-associated anaplastic large cell lymphoma (BI-ALCL) is a rare T-cell malignancy arising around mammary prosthetic implants. It has been included as a new provisional entity within the group of ALCL in the revised WHO classification of lymphoid malignancies<sup>1</sup>. Although activating

mutations of the JAK/STAT3 pathway genes have been reported in some cases<sup>2-3</sup> and its derivation from capsular Th1/Th17 cells has been suggested<sup>4</sup>, its pathogenesis and cell of origin remain largely unknown.

**Principals/Methodology:** We performed gene expression profiling of micro-dissected BI-ALCL samples using the Whole-Genome DASL assay (Illumina) and compared the transcriptional profiles with those previously obtained from normal T-cells and other peripheral T-cell lymphomas (PTCLs)<sup>5</sup>.

**Results:** Gene expression profile results indicate that BI-ALCLs are distinct from other PTCLs showing an activated CD4+ memory T-cell phenotype, which is associated with CD25 and FoxP3 expression in most cases. Moreover, gene ontology analyses revealed upregulation of genes involved in cell motility programs (e.g. CCR6, MET, HGF, CXCL14) and in myeloid cell differentiation (e.g. PPAR $\gamma$ , JAK2, SPI-1, GAB2), as well as deregulation of genes that participate in viral gene transcription (e.g. RPS10, RPL17, EIF3L, MCTS1). Moreover, gene set enrichment analyses revealed shared features between the molecular profiles of BI-ALCL and other types of ALCL, including down-regulation of TCR-signaling and STAT3 activation.

**Conclusion:** Our findings provide novel insights into the biology of this emerging entity and further evidence that BI-ALCL represents a distinct PTCL mostly exhibiting an activated CD4+ memory T-cell phenotype with upregulated STAT3, motility and viral gene transcription programs and downregulated TCR signaling.

#### References:

1. Swerdlow SH et al. World Health Organization Classification of Tumours, Revised 4th Edition, Volume 2. Lyon, France: IARC; 2017.
2. Di Napoli A et al. Br J Haematol. 2018;180(5):741-744.
3. Blombery P et al. Haematologica. 2016;101:e387-e390.
4. Kadin ME et al. Aesthetic Surgery Journal. 2016;36(7):773-781.
5. Piccaluga PP et al. J Clin Oncol. 2013;31(24): 3019-3025.

LYS-O-4-2

## The role of PD-1 and PD-L1 in T-cell immune suppression in patients with primary testicular diffuse large B-cell lymphoma (PT-DLBCL)

Maria R. Ambrosio<sup>1</sup>, Giuseppe Lo Bello<sup>1</sup>, Virginia Mancini<sup>1</sup>, Ayse Akarka<sup>2</sup>, Raffaella Santi<sup>3</sup>, Maria M. de Santi<sup>1</sup>, Raffaella Guazzo<sup>1</sup>, Lucia Mundo<sup>1</sup>, Thomas Menter<sup>4</sup>, Alexander Tzankov<sup>4</sup>, Stephen Dirnhofer<sup>4</sup>, Teresa Marafioti<sup>2</sup>, Gabriella Nesi<sup>3</sup>, Stefano Lazzi<sup>1</sup>, Ioannis Anagnostopoulos<sup>5</sup>, Korinna Joehrens<sup>5</sup>, Lorenzo Leoncini<sup>1</sup>

<sup>1</sup>University of Siena, Siena, Italy, <sup>2</sup>University College London, London, United Kingdom, <sup>3</sup>University of Florence, Florence, Italy, <sup>4</sup>University of Basel, Basel, Switzerland, <sup>5</sup>Charité University, Berlin, Germany

**Background:** PT-DLBCL are extranodal large B-cell lymphomas with poor response to current therapies. This might reflect the sites of origin considered to be an immune privileged sanctuary. A recent paper have described frequent 9p24.1/PD-L1/PD-L2 copy number alterations in PT-DLBCL which may represent structural bases of immune evasion. However, a complete assessment of the immune escape mechanisms eventually acting in this type of disease is missed and this is the aim of the present study

**Principals/Methodology:** We studied 90 cases of PT-DLBCL diagnosed according to the updated WHO classification. The following antibodies were tested by means of multiplex staining: CD20, CD3, PAX-5, CD4, CD8, CD10, BCL-6, BCL-2, MUM-1, MYC, PD-1, PD-L1, PD-L2, FOXP3, CD25, CD68, CD163. In situ hybridization for EBV (EBER) and qPCR for EBNA-1 and Bam were carried out in most of cases. FISH analysis was performed by SPEC CD274, PDCD1LG2/CEN9, Dual Color, Zyto Light probe for PD-L1. A statistical software package (SYSTAT-7) was used for statistical analysis.



**Results:** The activated B-cell phenotype was observed in 80% of cases. MYC protein was detected in 45% of PTL, BCL-2 in 76%. Only 2 high grade B-cell lymphoma with MYC and BCL-2 rearrangements and 9 double expressor (MYC and BCL-2) were identified. PD-1 and PD-L1 were detected in both lymphoma and tumor microenvironment (reactive lymphocytes-TILS and macrophages), PD-L2 in neoplastic tissue. No correlation between MYC, BCL-2 and PD1/PD-L1 was detected. PD1 score in TILS corresponded to the PD-L1 one in tumour. The TILs were represented mainly by CD8-positive T-cell. PD-1 tumour associated macrophages were M2. EBER-ISH was negative in all cases but 7 samples showed EBV infection by qRT-PCR. These cases demonstrated an higher PD-1 expression. FISH analysis detected 9 amplified cases. Univariate analysis recognized high MYC expression, PD-1 in neoplastic cells, PD-L1 in tumor microenvironment, high T-reg lymphocytes, low T-exhausted lymphocytes and high M2 macrophages as significant prognostic factors in PTL.

**Conclusion:** Growing knowledge about immune pathology in PTL along with the implementation of immunotherapy occurred in the last years. If our preliminary results will be confirmed, the present study will open new avenues for identifying predictive biomarkers that may guide therapeutic choices and eventually improve the prognosis of these diseases.

LYS-O-4-3

## Next generation sequencing of vitreoretinal B-cell lymphoma reveals a mutational landscape similar to primary central nervous system lymphoma and facilitates diagnosis

Irina Bonzheim<sup>\*1</sup>, Melanie Büssgen<sup>1</sup>, Christoph Deuter<sup>2</sup>, Daniela Süsskind<sup>2</sup>, Manfred Zierhut<sup>2</sup>, Birgit Federmann<sup>1</sup>, Julia Steinhilber<sup>1</sup>, Jens Schittenhelm<sup>1</sup>, Leticia Quintanilla-Martinez<sup>1</sup>, Sarah Coupland<sup>3</sup>, Karl-Ulrich Bartz-Schmidt<sup>2</sup>, Falko Fend<sup>1</sup>

<sup>1</sup>Institute of Pathology and Neuropathology, <sup>2</sup>Centre of Ophthalmology, University Hospital Tübingen, Tübingen, Germany, <sup>3</sup>Department of Molecular & Clinical Cancer Medicine, Institute of Translational Medicine, University of Liverpool, Liverpool, United Kingdom

**Background:** Vitreoretinal B-cell lymphoma (VRL) is a rare ocular malignancy. It occurs either as primary VRL or secondary to primary central nervous system lymphoma (PCNSL) and is in most cases classified as diffuse large B-cell lymphoma (DLBCL) of ABC type. It is usually diagnosed by cytological, immunocytochemical, and molecular examination of vitreous aspirates. Using conventional diagnostics, distinguishing VRL from uveitis remains difficult. We previously reported that MYD88 mutations are found in 69% of VRL cases, and that their detection improves the diagnostic yield of vitreous aspirates. Recent studies of PCNSL using high throughput sequencing have identified the spectrum of recurrently mutated genes, which in part overlaps with ABC DLBCL, but shows some specific features thought to reflect the site of origin. The aim of our study was to analyse a large series of VRL using targeted NGS to compare their mutational landscape with PCNSL and to assess the potential of this approach to further increase the diagnostic sensitivity in vitreous aspirates.

**Principals/Methodology:** DNA of a large series of vitrectomy specimens with suspicion or confirmed diagnosis of VRL was investigated by NGS. Samples had previously been analysed by cytological, immunohistochemical examination as well as for IG rearrangements. NGS was performed using an AmpliSeq custom panel to analyse the most frequently recurrently mutated genes in PCNSL. In addition, five PCNSL samples served as controls.

**Results:** All confirmed VRL cases examined, as well as the 5 control PCNSL cases, showed mutations in one or more of the examined genes. In addition to a high frequency of MYD88 mutations, which fre-

quently co-occurred with CD79B mutations, we observed that in cases with a high number of mutations, most mutated genes were targets of aberrant somatic hypermutation as previously shown in systemic DLBCL (PIM1, IRF4, BTG1/2, IGLL5). Furthermore, the identification of mutations in MYD88 WT VRL cases confirmed that our targeted NGS panel increases the diagnostic sensitivity of vitreous fluid examination. None of the examined reactive uveitis cases showed mutations.

**Conclusion:** The mutational spectrum of VRL is similar to PCNSL, with high frequencies of MYD88 and CD79B mutations and a signature of aberrant somatic hypermutation. NGS analysis of vitreous fluid is a powerful tool to diagnose VRL in cases with insufficient cytological evidence of malignancy or lack of clonal IG rearrangements and can be performed with small amounts of input DNA.

LYS-O-5-1

## Localized low-stage follicular lymphomas exhibit distinct biological/genetic features

Annette M. Staiger<sup>\*1</sup>, Ellen Leich<sup>2</sup>, Jordan Pischmarov<sup>2</sup>, Eva Hoster<sup>3</sup>, Vindi Jurinovic<sup>3</sup>, Marianne Engelhard<sup>4</sup>, Klaus Herfarth<sup>5</sup>, Wolfgang Hiddemann<sup>3</sup>, Martin Dreyling<sup>3</sup>, Thomas F. Barth<sup>6</sup>, Peter Möller<sup>6</sup>, Heinz-Wolfram Bernd<sup>7</sup>, Alfred C. Feller<sup>7</sup>, Wolfram Klapper<sup>8</sup>, Michael Hummel<sup>9</sup>, Dido Lenze<sup>9</sup>, Harald Stein<sup>10</sup>, Martin-Leo Hansmann<sup>11</sup>, Sylvia Hartmann<sup>11</sup>, Andreas Rosenwald<sup>2</sup>, German Ott<sup>1</sup>, Heike Horn<sup>12</sup>

<sup>1</sup>Department of Clinical Pathology, Robert-Bosch-Krankenhaus, Dr. Margarete Fischer-Bosch-Institute of Clinical Pharmacology, Stuttgart, <sup>2</sup>Institute of Pathology, Universität Würzburg, Würzburg, <sup>3</sup>Department of Internal Medicine III, University of Munich, München, <sup>4</sup>Department for Radiotherapy, University Hospital Essen, Essen, <sup>5</sup>Department of Radiation Oncology, University Hospital of Heidelberg, Heidelberg, <sup>6</sup>Institute of Pathology, Universitätsklinikum Ulm, Ulm, Germany, Ulm, <sup>7</sup>Institute of Pathology, Universitätsklinikum Schleswig-Holstein, Campus Lübeck, Lübeck, <sup>8</sup>Institute of Pathology, Hematopathology Section and Lymph Node Registry, Universitätsklinikum Schleswig-Holstein, Campus Kiel, Kiel, <sup>9</sup>Institute of Pathology, Campus Benjamin Franklin, Charité Universitätsmedizin, Berlin, <sup>10</sup>Pathodiagnostik Berlin, Berlin, Germany, Berlin, <sup>11</sup>Institute of Pathology, Universitätsklinikum Frankfurt, Frankfurt, <sup>12</sup>Dr. Margarete Fischer-Bosch-Institute of Clinical Pharmacology, Stuttgart, Germany

**Background:** The genetic background of typical systemic follicular lymphomas (FL) of clinical stages III/IV has been unraveled substantially. Molecular features, e.g. translocation t(14;18) found in ~90% of cases, are also important in risk stratification. In contrast, little information is available concerning nodal low stage (I/II) FL (~20% of newly diagnosed FL) and in which a BCL2 rearrangement is detected in only ~50%.

**Principals/Methodology:** To investigate the genetic background of low stage FL, we selected a patient cohort uniformly treated within prospectively randomized clinical trials of the German Low-Grade Lymphoma Study Group (GLSG). We performed targeted gene expression profiling (GEP) using the nCounter technology in 110 low stage and 556 systemic FL. 184 candidate genes were selected that already had been described to be of prognostic relevance in FL. Fluorescence in situ hybridization (FISH) was used to detect recurrent deletions in chromosomes 1p, 6q and 17p in 146 localized and 541 systemic FL. Mutation analysis of TNFRSF14 (1p36) and TP53 (17p) complemented FISH analysis. Whole exome sequencing (WES) was performed in a representative sample cohort of low stage (n=14) and high stage (n=12) FL.

**Results:** A prognostically relevant gene signature could not be identified in patients with high stage FL. However, it was possible to identify a GE signature that allows to discriminate low and high stage FL. Of note, some cases with “high stage signature” were included in the low stage cohort. Likewise, cases



with “low stage signature” were identified in the high stage cohort. In the latter cases, TTF and OS were significantly prolonged. No significant differences in the frequency of deletions in 1p, 6q and/or 17p were observed between high and low stage FL. However, TNFRSF14 mutations were significantly more frequent in low stage FL (66% vs 51%;  $p=0.0041$ ). Moreover, dissecting low stage FL into t(14;18)-positive (49%) and t(14;18)-negative (51%) tumors revealed that 1p-deletions and TNFRSF14-mutations were more frequently observed in t(14;18)-positive FL ( $p=0.020$ ). Clinical correlations and WES data analysis are still ongoing.

**Conclusion:** Gene expression analysis allowed the identification of patients with a “low stage” signature among high stage FL denoting patients with significantly longer survival who may profit from milder treatment. It seems of pivotal interest to reliably categorize FL patients not only based upon clinical parameters, but also by underlying molecular features.

LYS-O-5-2

## Frequency of potential N-glycosylation sites in t(14;18)-positive and negative low and high stage follicular lymphoma

Claudia Maier<sup>1,2</sup>, Riccardo Bomben<sup>3</sup>, Alberto Zamo<sup>4</sup>, Filippo Vit<sup>3</sup>, Heike Horn<sup>5</sup>, Valter Gattei<sup>3</sup>, German Ott<sup>6</sup>, Andreas Rosenwald<sup>1,2</sup>, Ellen Leich-Zbat<sup>1,2</sup>

<sup>1</sup>Institute of Pathology, University of Würzburg, <sup>2</sup>Comprehensive Cancer Center (CCC) Main Franken, Würzburg, Germany, <sup>3</sup>Department of Translational Research, CRO, Aviano, <sup>4</sup>Department of Oncology, University of Turin, Torino, Italy, <sup>5</sup>Dr. Margarete Fischer-Bosch-Institute for Clinical Pharmacology, <sup>6</sup>Department of Clinical Pathology, Robert-Bosch-Krankenhaus, Stuttgart, Germany

**Background:** N-glycosylation of the immunoglobulin variable (IGV) region is a common feature in follicular lymphoma (FL) and is seen in ~80-100% of random FL cohorts. In our recent study we observed that mutations in N-glycosylation associated genes are enriched in t(14;18)-negative FL and revealed that the gain of new N-glycosylation sites occurred only in the minority of t(14;18)-negative cases. Thus, we aimed to investigate the occurrence of newly gained N-glycosylation sites in an independent German FL cohort of t(14;18)-negative and t(14;18)-positive low stage (I/II) and high stage (III/IV) FL.

**Principals/Methodology:** Specifically, we investigated the BCL2-breakpoint and translocation status of 31 low and 58 high stage FL cases at diagnosis with fresh frozen (FF) material and clinical data available using fluorescence in situ hybridization. Subsequently, we performed PCR amplification of the IGV region using the CE-IVD certified LymphoTrack® Dx IGH FR1 Assay MiSeq® kit and DNA of FF samples was sequenced on the Illumina-MiSeq platform. FASTq files were processed using the Lymphotrack software and an in house-protocol. VDJ assignment was done using the IMG\_T\_vquest and the NCBI-IGBLAST tool.

**Results:** Sequencing, which revealed a clonal amplification in 7/9 t(14;18)-positive and 8/9 t(14;18)-negative high stage FL and in 11/15 t(14;18)-positive and 8/12 t(14;18)-negative low stage FL allowed the detection of new N-glycosylation sites in 6/15 (40%) high stage and 12/19 (~63%) low stage FL. t(14;18)-positive FL more frequently gained new N-glycosylation sites compared to t(14;18)-negative FL (~61% vs ~44%,  $p=0.039$ ) and this difference was specifically prominent in the group of high stage FL (~57% vs 25%) while the frequency between t(14;18)-positive and negative low stage FL was highly similar in the current study cohort (~64% vs ~63%). However, the total number of newly gained sites was higher in t(14;18)-positive low stage FL (10 vs 5).

**Conclusion:** In conclusion, we observed a lower frequency of newly gained N-glycosylation sites than previously described in common FL cohorts which might be linked to the different ethnic background or technical procedures. However, in concordance with our previous findings, the gain of new N-glycosylation sites seems to be less common in t(14;18)-negative FL.

LYS-O-5-3

## Reproducibility of MYC protein expression scoring and impact on the prognosis of aggressive B-cell lymphoma patients

Stefano Lazzi<sup>1</sup>, Giuseppe Lo Bello<sup>1</sup>, Maria M. de Santi<sup>1</sup>, Raffaella Guazzo<sup>1</sup>, Lucia Mundo<sup>1</sup>, Massimo Granai<sup>1</sup>, Raffaella Santi<sup>2</sup>, Leonardo Del Porro<sup>1</sup>, Roshanak Bob<sup>3</sup>, Thomas Menter<sup>4</sup>, Kikkeri K. Naresh<sup>5</sup>, Harald Stein<sup>3</sup>, Elena Sabattini<sup>6</sup>, Lorenzo Leoncini<sup>1</sup>, Maria R. Ambrosio<sup>\*1</sup>

<sup>1</sup>University of Siena, Siena, <sup>2</sup>University of Florence, Florence, Italy, <sup>3</sup>Pathodiagnostik lab, Berlin, Germany,

<sup>4</sup>University of Basel, Basel, Switzerland, <sup>5</sup>Imperial College, London, United Kingdom, <sup>6</sup>University of Bologna, Bologna, Italy

**Background:** Several investigators have demonstrated that MYC and BCL-2 protein co-expression in DLBCL patients has adverse prognostic effect when conventional up-front immunochemotherapies are administered. Therefore, evaluation of their protein over-expression by immunohistochemistry (IHC) is an important tool in prognostic stratification of patients and standardizing reproducible cut-offs to define positivity for MYC- and BCL-2 by IHC is highly desirable for optimizing patients' management.

**Principals/Methodology:** We evaluated MYC and BCL-2 gene alterations and proteins across a large number of aggressive B-cell lymphomas (n=753) to define the cut-offs at IHC with the highest reproducibility in a "real-life" context and to provide information for risk stratification and prognosis of patients by statistical analysis.

**Results:** Our findings confirm that BCL-2-IHC scoring is highly reproducible across the different institutions and that  $\geq 50\%$  cut-off is reliably assessable. Scoring MYC-IHC staining can be critical, mainly for the variability of staining intensity and percentage of positivity. The concordance were high only for MYC-IHC positivity  $\geq 70\%$ , while the largest discrepancy was observed in the range 40-69%. Therefore, we propose the threshold of MYC-IHC 70-100% to define non-BL cases as MYC highly positive and 0-39% to classify samples as MYC protein negative. MYC-IHC scores between 40% and 69% should be termed "indeterminate". This threshold is able to predict the presence of rearrangements. Univariate and multivariate analysis showed that IPI, MYC-IHC  $>70\%$ , DH and DE with MYC  $\geq 70\%$  were independent prognostic factors that influence patients outcome. By comparing the OS and PFS of DH, DE with MYC-IHC  $\geq 40\%$  and BCL-2-IHC  $\geq 50\%$ , DE with MYC-IHC  $\geq 70\%$  and BCL-2-IHC  $\geq 50\%$  and nonDH/nonDE subsets of non-BL we showed that strictly depended on MYC protein expression, being worse in those patients with MYC  $>70\%$ . Moreover, by using the cut-off of 70% no differences in prognosis was identified between DH and DE.

**Conclusion:** Our results support the role of MYC protein as the active trigger of the MYC-mediated oncogenic effects since protein expression levels likely represent a more direct measure of the activity of a particular gene. Therefore, MYC-IHC should be undertaken in all cases, limiting FISH to selected situations and widely reproducible cut-offs are needed to identify patients who may benefit from different therapeutic strategies.



LYS-O-5-5

## Engagement of RelA, cRel or RelB NF- $\kappa$ B subunit activation impacts on classification and prognosis of diffuse Large B-cell lymphoma

Davi Collares<sup>1</sup>, Nathalie Faumont<sup>2</sup>, Francis Devez<sup>3</sup>, Oussama Taoui<sup>2</sup>, Fabrice Jardin<sup>4</sup>,  
Christiane Copie-Bergman<sup>5</sup>, Karen Leroy<sup>6</sup>, Jean-Philippe Jais<sup>7</sup>, Thierry Molina<sup>8,9</sup>, Jean Feuillard<sup>2</sup>,  
Veronique Baud<sup>1</sup>

<sup>1</sup>NF- $\kappa$ B, Differentiation and Cancer, Université Paris Descartes, Paris, <sup>2</sup>CNRS, UMR 7276, Université de Limoges, Limoges, <sup>3</sup>Pathology department Hopital Necker, Assistance Publique Hopitaux de Paris, Paris, <sup>4</sup>Centre Henri Becquerel, Rouen, <sup>5</sup>Pathology department Hôpital Henri Mondor, Assistance Publique Hopitaux de Paris, Créteil, <sup>6</sup>Inserm U1016, Institut Cochin, <sup>7</sup>Institut Imagine, <sup>8</sup>Université Paris Descartes, <sup>9</sup>Pathology department Hôpital Necker, Assistance Publique Hopitaux de Paris, Paris, France

**Background:** The NF- $\kappa$ B family of transcription factors is activated by at least two major signalling pathways. The classical pathway results in the activation of RelA and cRel containing dimers, whereas the alternative pathway leads to the activation of RelB containing complexes. Diffuse large B-cell lymphoma (DLBCL) is the most common non-Hodgkin lymphoma. Gene expression profiling has revealed at least two distinct subtypes based on cell of origin (COO): the germinal centre (GC) and activated-B cell (ABC) subtypes. Identification of frequent mutations in genes encoding regulators of the classical NF- $\kappa$ B activity in ABC de novo DLBCL patients has led to the concept of NF- $\kappa$ B addiction in this subtype. However, the status per se of DNA-binding activity of classical (RelA and cRel) and alternative (RelB) NF- $\kappa$ B subunits in ABC and GC DLBCL patients and how it impacts on DLBCL subtype specificity and clinical outcome has never been investigated.

**Principals/Methodology:** We have directly evaluated by Electrophoretic mobility shift assay (EMSA) combined with supershifts the DNA binding activity of the classical (RelA and cRel) and the alternative (RelB) NF- $\kappa$ B subunits in a large cohort of newly diagnosed DLBCL patients. Then we have studied the impact of the NF- $\kappa$ B DNA binding activity pattern on DLBCL subtype specificity, mutational pattern, and clinical outcome.

**Results:** We show that strong RelA activation is linked to ABC DLBCL patients, whereas strong cRel activity is associated with GC DLBCL. Interestingly, cRel activation correlates with frequent REL amplification reported in the GC subtype. Further, we revealed that more than 60% of newly diagnosed DLBCL patients have a constitutive RelB DNA-binding activity. Contrary to RelA and cRel, RelB activation occurs independently from the COO classification, and defined a new subgroup of DLBCL patients with poor prognosis.

**Conclusion:** Our study demonstrates that the two classical NF- $\kappa$ B subunits (RelA and cRel) utilize distinct, non-redundant mechanisms in DLBCL pathogenesis. We have established the alternative NF- $\kappa$ B pathway as a new prognostic marker and potential molecular target for drug development in RelB-positive DLBCL patients.



LYS-O-6-1

## THRLBCL immune transcriptomic profile displays high expression of inhibitory receptors and tolerogenic molecules

Valentina Tabanelli<sup>1</sup>, Federica Melle<sup>1</sup>, Giovanna Motta<sup>1</sup>, Marco Fabbri<sup>1</sup>, Angelica Calleri<sup>1</sup>, Ning Chen<sup>2</sup>, Alessandra Cesano<sup>2</sup>, Stefano Pileri<sup>1</sup>

<sup>1</sup>Unit of Haematopathology, European Institute of Oncology, Milano, Italy, <sup>2</sup>NanoString Technologies, Seattle, United States

**Background:** T-cell/histiocyte rich large B-cell lymphoma (THRLBCL) is recognized by the WHO as a separate clinicopathological entity from diffuse large B cell lymphoma (DLBCL). Tumour microenvironment (TME) plays a key role in THRLBCL, due to its peculiar cellular composition (less than 10% neoplastic B-cells interspersed in a cytotoxic T-cells/histiocytes rich background).

To better understand the immune cells interplays in TME, we compared the expression profile of 770 immune-related transcripts in THRLBCL and DLBCL samples.

**Principals/Methodology:** Total RNA was extracted from 12 THRLBCL and 24 DLBCL (12 GCB and 12 ABC molecular subtypes) formalin-fixed paraffin-embedded samples; mRNA expression analysis was carried out with a Nanostring PanCancer Immune Profiling Panel.

**Results:** Supervised analysis identified 165 transcripts differentially expressed in THRLBCL compared with DLBCL (143 upregulated and 22 downregulated with > 2-fold, adjusted  $p < 0.05$ ). THRLBCL set showed higher expression of genes involved in cytokine/cytokine receptor interaction, T/NK-cell immune response and macrophage activation; conversely, B-cell related genes were downregulated. Among the THRLBCL most expressed genes, we found several inhibitory receptors (IRs): CD160, KLRG1, LAG3, TIM3, 2B4, TRAIL, and TIGIT. IRs expression is linked to T-cell differentiation status (it is higher in effector memory and terminally differentiated T-cells); these molecules fine-tune immune responses counterbalancing activating receptors; increased IRs levels have been described in tumour-infiltrating CD8+ T-cells, in association with reduced cytotoxic activity.

We also observed a significant up-regulation of the immunosuppressive enzyme IDO and of other molecules involved in macrophage-recruitment (interleukin-21, STAT1, interferon- $\gamma$ , CCL8, CCL5, CSF1R, CCR1, CCR2, CCR5).

**Conclusion:** THRLBCL microenvironment seems to be balanced by an interplay between macrophages and cytotoxic T-cells: the former may have been recruited by chemoattractants produced by T-cells, and subsequently stimulated to produce IDO (as previously described by Van Loo et al). IDO can dampen the effector T-cell cytotoxic activity, up-regulating IRs expression and switching their phenotype to a terminally differentiated one.

To conclude, THRLBCL immune transcriptomic profile shows deregulation of several immunomodulatory molecules, suggestive of a tolerogenic milieu. Moreover, the up-regulation of IRs and IDO may represent a potential target for a "checkpoint blockade" therapy.

LYS-O-6-2

## JUNB, DUSP2, SGK1, CREBBP and SOCS1 are frequently mutated in T-cell/histiocyte rich large B-cell lymphoma

Bianca Schuhmacher<sup>1</sup>, Julia Bein<sup>2</sup>, Tobias Rausch<sup>3</sup>, Vladimir Benes<sup>3</sup>, Thomas Tousseyn<sup>4</sup>, Martine Vornanen<sup>5</sup>, Maurilio Ponzoni<sup>6</sup>, Randy Gascoyne<sup>7</sup>, Christian Steidl<sup>7</sup>, Ralf Küppers<sup>8</sup>, Martin-Leo Hansmann<sup>2</sup>, Sylvia Hartmann<sup>\*1</sup>

<sup>1</sup>Pathologie, <sup>2</sup>Goethe Universität, Frankfurt, <sup>3</sup>EMBL, Heidelberg, Germany, <sup>4</sup>University of Leuven, Leuven, Belgium, <sup>5</sup>Fimlab, Tampere, Finland, <sup>6</sup>Scientific Institute San Raffaele, Milan, Italy, <sup>7</sup>British Columbia Cancer Center, Vancouver, Canada, <sup>8</sup>University of Duisburg-Essen, Essen, Germany

**Background:** T-cell/histiocyte-rich large B-cell lymphoma (THRLBCL) is a rare aggressive lymphoma showing histological overlap with nodular lymphocyte predominant Hodgkin lymphoma (NLPHL). Despite differences in tumor microenvironment and clinical behavior, the tumor cells of both entities show remarkable similarities, suggesting that both lymphomas might represent a spectrum of the same disease. The aim of our study was to analyze if genes recurrently mutated in NLPHL are also mutated in THRLBCL.

**Principals/Methodology:** A targeted NGS-based re-sequencing approach for 67 genes was applied for typical NLPHL patterns A/B (n=6), histopathological NLPHL variants patterns C/D/E (n=11) and THRLBCL (n=9).

**Results:** This approach revealed that the mutational landscapes of THRLBCL and NLPHL are highly related, both frequently harboring mutations in JUNB, DUSP2, SGK1, CREBBP and SOCS1. JUNB, DUSP2, SGK1 and SOCS1 showed an increased number of variants per gene and were affected by mutations more frequently in THRLBCL and the histopathological NLPHL variants than in typical NLPHL. Mutations in these genes were highly enriched for somatic hypermutation (SHM) hotspot sites, suggesting an important role of aberrant SHM in the pathogenesis of NLPHL and THRLBCL.

**Conclusion:** THRLBCL and the histopathological NLPHL variants might therefore have longer or stronger exposure to SHM than typical NLPHL. Taken together, the present study further supports a close relationship of THRLBCL and NLPHL by showing that they share key highly recurrent genetic lesions.

LYS-O-6-3

## FBXO11 is a frequently mutated oncosuppressor in Burkitt Lymphoma

Chiara Pighi<sup>\*1,2</sup>, Mara Compagno<sup>2</sup>, Taek Chin Cheong<sup>2</sup>, Teresa Poggio<sup>1</sup>, Qi Wang<sup>2</sup>, Riccardo Dall'Olio<sup>1</sup>, Fernanda Langellotto<sup>2</sup>, Anoop Sendamarai<sup>2</sup>, Kyriacos Markianos<sup>2</sup>, Paola Francia di Celle<sup>1</sup>, Alberto Zamò<sup>3</sup>, Roberto Chiarle<sup>1,2</sup>

<sup>1</sup>Department of Molecular Biotechnology and Health Sciences, University of Torino, Torino, Italy, <sup>2</sup>Department of Pathology, Children's Hospital Boston, Harvard Medical School, Boston, United States, <sup>3</sup>Department of Oncology, University of Torino, Torino, Italy

**Background:** FBXO11 is an ubiquitin ligase involved in the degradation of BCL6, a key oncogene in lymphoma pathogenesis. The FBXO11 gene is frequently inactivated by mutations in Diffuse Large B cell Lymphoma (DLBCL)<sup>1</sup>, promoting the accumulation of BCL6. Here we searched for FBXO11 mutations in BCL6-positive lymphomas and investigated its role in lymphoma development in vivo.

**Principals/Methodology:** We sequenced the FBXO11 gene in 100 cases of Follicular Lymphoma (FL), 36 cases and 8 cell lines of Burkitt Lymphoma (BL), 8 Anaplastic Large cell Lymphoma cell lines and 50 cases of Marginal Zone B cell Lymphoma (MZL). We validated the FBXO11 mutations by testing their ability to



induce BCL6 degradation. We knocked-out (KO) the FBXO11 gene in BL cells by CRISPR/Cas9 and tested the sensitivity of FBXO11 KO BL cells to a BCL6 inhibitor (FX1) alone or in combination with chemotherapy (doxorubicin). We generated conditional FBXO11 KO mice (CD19/Cre-FBXO11<sup>fl/fl</sup>) and crossed them with E $\mu$ -myc transgenic mice to investigate whether FBXO11 inactivation cooperates with c-myc in lymphomagenesis.

**Results:** We identified FBXO11 mutations in BL cases and cell lines (10/44, 22.7%), one case of FL and one case of MZL. Recurrent FBXO11 mutations in BL were further identified in public sequencing databases of 66 BL cases (13/66, 19.7%)<sup>2,3</sup>. BL mutations found in our series were mostly missense and splice-site mutations, all of them impairing FBXO11 ability to induce BCL6 degradation. FBXO11-KO BL cells showed increased resistance to standard chemotherapy as well as increased sensitivity to BCL6 inhibition compared to the FBXO11 WT BL cells. The simultaneous combination of FX1 with doxorubicin restored the sensitivity of FBXO11-KO BL cells to standard chemotherapy. We observed an acceleration of lymphoma development in CD19/Cre-FBXO11<sup>fl/fl</sup> mice crossed with E $\mu$ -myc transgenic mice. Lymphomas showed a more mature B-cell phenotype, stabilization of BCL6 and reduced apoptotic fraction compared to E $\mu$ -myc only tumors.

**Conclusion:** We demonstrate that FBXO11 is frequently mutated in BL (23/110, 20.9%) placing it among the top five genes most frequently mutated in BL. Experiments in vitro and in vivo show that FBXO11 deletion cooperates with c-myc in accelerating lymphomagenesis. Lastly, combination of BCL6-targeted therapy restored the sensitivity of FBXO11-KO BL cells to standard chemotherapy suggesting potential combinational strategies for the treatment of BL patients.

**References:**

1. Duan et al, Nature 2012
2. Love et al, Nat Genet 2012
3. Grobner et al, Nature 2018

LYS-O-6-4

## Burkitt-like lymphoma with 11q aberration: A germinal center derived lymphoma without ID3-TCF3-CCND3 pathway deregulation

Blanca Gonzalez-Farre<sup>\*1,2</sup>, Joan Enric Ramis-Zaldivar<sup>1</sup>, Julia Salmeron-Villalobos<sup>1</sup>, Marta Garrido<sup>3</sup>, Veronica Celis<sup>4</sup>, Jaime Verdu<sup>5</sup>, Federico Garcia-Bragado<sup>6</sup>, Olga Balague<sup>1</sup>, Noelia Garcia<sup>1</sup>, Elias Campo<sup>1</sup>, Itziar Salaverria<sup>1</sup>

<sup>1</sup>Hematopathology Unit., Hospital Clinic De Barcelona. IDIBAPS, BARCELONA, <sup>2</sup>Centro de Investigación Biomédica en Red de Cáncer (CIBERONC), Madrid, <sup>3</sup>Pathology, Hospital Vall d'Hebron, <sup>4</sup>Pediatric Oncology, Hospital Sant Joan de Deu, Barcelona, <sup>5</sup>Pediatric Oncology, Hospital Clínico Universitario de Valencia, Valencia, <sup>6</sup>Pathology, Complejo Hospitalario de Navarra, Pamplona, Spain

**Background:** Burkitt-like lymphoma with 11q aberration (BLL-11q) is a new provisional entity in the 2016 WHO classification. The limited number of reported cases does not allow to define whether this is a specific entity or it is a particular variant or other categories such as Burkitt (BL) or diffuse large B-cell lymphomas (DLBCL).

Here we performed a complete study of BLL-11q aiming to improve its knowledge.

**Principals/Methodology:** To identify potential cases that may correspond to this category we initially search in our files for cases diagnosed as BL, atypical BL, or high-grade B-cell lymphoma in patients  $\leq 40$  years. MYC status was reviewed and completed using MYC break apart FISH probe. In MYC negative cases the study of 11q aberrations was performed by copy number (CN) array and FISH with a custom probe.

Additionally, in the subset of BLL-11q cases identified, clinico-pathological data, immunohistochemical studies including MYC and LMO2, cell-of-origin (COO) using NanoString Lymph2Cx assay, and Target Next Generation Sequencing with a custom panel of 96 B-cell lymphoma related genes (Sureselect XT libraries) were performed.

**Results:** A total of 10 cases lacked MYC translocations and displayed 11q aberration characteristic of BLL-11q by CN array and FISH analyses (7M/3F, mean age 16 years, range 8-37). The presentation was nodal in 8 cases. All cases had excellent prognosis after chemotherapy and all were alive without disease after median follow-up of 32 months (range 2-113m). Histologically, 9 cases were considered as high-grade B-cell lymphomas, NOS, two of them with blastoid features and the remaining case had DLBCL morphology. Two out of 10 cases had a nodular growth pattern. All cases had a germinal center (GC) phenotype (Hans algorithm and Lymph2Cx COO assay) and one was positive for BCL2. LMO2 was positive (>30% of positive cells) in 6/10 cases, whereas 4 cases expressed MYC (>40% of positive cells). All cases were negative for CD56. The cases displayed certain levels of genetic complexity with 6.4 CN alterations/case (range 2-15) and lack BL-related ID3-TCF3-CCND3 pathway mutations. In contrast, cases carried recurrent MYC, BTG2 (4 cases each) and ETS1 mutations (3 cases).

**Conclusion:** The pathological and clinical characteristics and the genomic and mutational profile of BLL-11q differ from those of classical BL suggesting that these tumors may correspond to different category of GC-derived lymphomas. MYC and BTG2 mutations together with the 11q alterations may play a relevant role in their pathogenesis.

LYS-O-7-1

## Simultaneous analysis of mutations, translocations and copy number aberrations in B-cell Non-Hodgkin Lymphomas using an “All-in-One Next-Generation Sequencing Assay”

G. Tjitske Los-de Vries<sup>1</sup>, Matias Mendeville<sup>1</sup>, Margaretha G. M. Roemer<sup>1</sup>, Reno Bladergroen<sup>1</sup>, Phylicia Stathi<sup>1</sup>, Nathalie J. Hijmering<sup>1</sup>, Bauke Ylstra<sup>1</sup>, Daphne de Jong<sup>1</sup>

<sup>1</sup>Pathology, VU University Medical Centre, Amsterdam, Netherlands

**Background:** Genome studies in B-cell Non-Hodgkin Lymphomas (B-NHL) have identified recurrent mutations, translocations and copy number aberrations (CNA) that may be used for diagnostic and treatment classification. We developed a comprehensive assay for simultaneous screening of these alterations using DNA derived from FFPE biopsy samples without the need of matched normal DNA optimized to be implemented in clinical practice.

**Principals/Methodology:** For assay development, 19 FFPE B-NHL samples were used, with known BCL2, BCL6, CCND1 and MYC translocations as determined by FISH, including 5 paired FFPE/FF samples. Library preparation was optimized to allow 100-250 ng fragmented DNA input.

A custom sequencing panel was designed to screen for mutations and translocations in 355 genes and 12 genomic regions (3Mb), often perturbed in hematologic malignancies. Shallow whole genome NGS for CNA analysis and deep targeted NGS was performed using the same library preparation.

A bioinformatic analysis pipeline was assembled using Snakemake and publically available tools. Multiple tools were combined to boost sensitivity and specificity.

**Results:** Similar results for mutations, translocations and CNAs were found in FFPE and matched FF samples. Expected mutations and CNAs were detected. Moreover, with combined analysis several LOH events and mutations affecting the same gene could be identified, such as TNFAIP3 mutations together with a chromosomal loss. Also FISH and NGS showed high concordance. Of 22 translocations detected with



FISH, NGS missed one MYC translocation, while FISH had missed one BCL6 break. Moreover, 4 previously unknown translocations were discovered: a CD70 translocation and 3 IGH translocations to PAX5, PRCC, and the 6p25.3 locus. Also, 6 non-IG translocation partners of MYC and BCL6 were identified. Complex FISH patterns could be explained by integration of CNA and translocation data and underpinned causes of misinterpretation of FISH patterns.

**Conclusion:** We present a targeted All-in-One NGS NHL assay, that has several advantages:

- 1) simultaneous screening of mutations, translocations and CNAs,
- 2) optimized for limited amount of FFPE material,
- 3) base pair resolution translocation detection,
- 4) identification of translocation partners,
- 5) multiple samples can be assayed in parallel and;
- 6) no need for matched normal DNA.

This comprehensive approach will enable broad application in the diagnosis and treatment stratification of B-NHL and help to develop biomarker-driven clinical trials for personalized medicine.

LYS-O-7-2

## Use of T cell-specific RNA in situ hybridisation as a novel test to distinguish malignant (lymphomatous) and benign (inflammatory) T cell infiltrates

Elizabeth Soilleux<sup>1,2</sup>, William Day<sup>3</sup>, Tasneem Hassanali<sup>4</sup>, Megan Peccarelli<sup>3</sup>, Rachel Etherington<sup>5</sup>, Graham Ogg<sup>5</sup>

*<sup>1</sup>Department of Pathology, University of Cambridge, <sup>2</sup>Haematopathology & Oncology Diagnostic Service, Cambridge, Cambridge University Hospitals NHS Foundation Trust, Cambridge, United Kingdom, <sup>3</sup>tRED, Assay Reagents & Technologies, Ventana Medical Systems Inc., Tucson, AZ, United States, <sup>4</sup>Nuffield Division of Clinical Laboratory Sciences, Radcliffe Department of Medicine, <sup>5</sup>MRC Human Immunology Unit, NIHR Biomedical Research Centre, Radcliffe Department of Medicine, University of Oxford, Oxford, United Kingdom*

**Background:** The differentiation between benign and malignant (e.g., lymphoma or leukaemia) lymphocytic infiltrates is an important and common clinicopathological question in routine healthcare practice. While this is possible for B cell infiltrates using kappa/lambda immunoglobulin light chain staining, there is not an equivalent for T cell infiltrates, which currently require expensive and time consuming T cell receptor gene rearrangement PCR studies to be undertaken. We have identified two T cell-specific, mutually exclusively expressed, RNA sequences (TRBC1 and TRBC2), corresponding to the two, alternatively employed, T-cell receptor beta constant region segments.

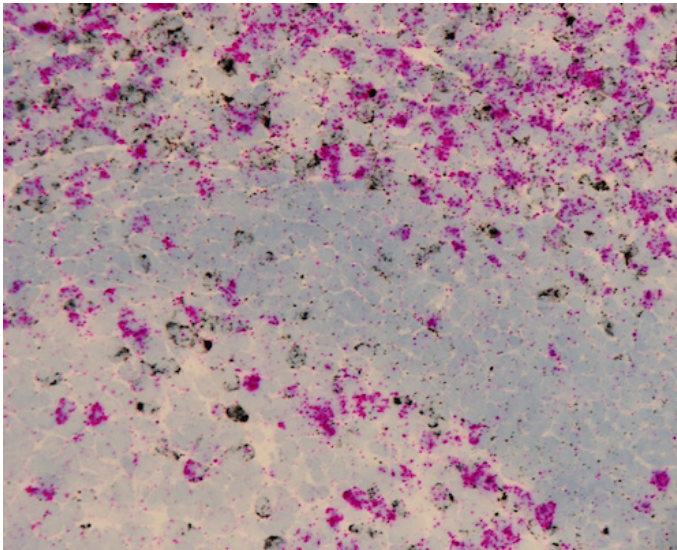
**Principals/Methodology:** We analysed the TRBC1 and TRBC2 gene segments using standard bioinformatics tools, undertook Q-PCR to investigate relative expression levels and developed TRBC1/TRC2 segment-specific probes for chromogenic in situ hybridisation (CISH), which we validated on T-cell lymphoma/ leukaemia lines processed to paraffin and on formalin fixed paraffin embedded (FFPE) sections of T-cell lymphoma and corresponding benign tissue.

**Results:** The coding regions of TRBC1 and TRBC2 are very similar at amino acid level, making development of highly specific TRBC1/ TRBC2 diagnostic monoclonal antibodies difficult. However, the 3' untranslated regions differ substantially. Q-PCR demonstrated that, in benign populations of peripheral blood mononuclear cells the ratio of TRBC1: TRBC2 was very close to 1:1. Single TRBC1 and TRBC2 CISH staining on serial sections of benign T-cell infiltrates demonstrated similar numbers of TRBC1+ and TRBC2+ cells. Single staining of both T-cell lymphoma/ leukaemia lines and FFPE sections of T-cell lymphoma demonstrated

clear TRC1/ TRC2 restriction (i.e., T-cell monotypia for TCR), with excellent correlation with TRCB1: TRBC2 ratio Q-PCR results. Double (duplex) staining was successfully developed and optimised on benign lymphocyte populations (figure 1: benign tonsil, polytypic for TCRB: TRBC1-pink; TRBBC2-black).

**Conclusion:** This is the basis of a novel diagnostic pathology test for T-cell lymphoma, applicable to FFPE sections, that might replace PCR-based clonality studies in the majority of cases. It has the potential to transform the routine assessment of T cell infiltrates in a manner analogous to the way kappa/lambda staining has done for B cells. It is therefore likely to impact upon international diagnostic guidelines with global health economic implications.

**Image:**



LYS-O-7-3

## MiR-146a target gene CD147 regulates energy metabolism and promotes tumor growth, angiogenesis and invasion of ALK+ ALCL

Julia Steinhilber<sup>1</sup>, Christoph Griebinger<sup>2</sup>, Ivonne A. Montes-Mojarro<sup>1</sup>, Achim Rau<sup>1</sup>, Ann-Kathrin Gersmann<sup>1</sup>, Ursula Kohlhofer<sup>1</sup>, Bernd Pichler<sup>2</sup>, Falko Fend<sup>1</sup>, Irina Bonzheim<sup>1</sup>, Leticia Quintanilla-Martinez<sup>1</sup>

<sup>1</sup>Institute of Pathology and Neuropathology, <sup>2</sup>Department of Preclinical Imaging and Radiopharmacy, University Hospital and Comprehensive Cancer Center Tuebingen, Tuebingen, Germany

**Background:** We recently reported that miR-146a is differentially expressed in ALK+ and ALK- anaplastic large cell lymphoma (ALCL). The strong downregulation of miR-146a in ALK+ ALCL in comparison to ALK- ALCL, normal T-cells and lymph nodes, which show a moderate and high expression, respectively, suggested that this miRNA might have an impact in the tumorigenesis of ALK+ ALCL. In this study, the downstream targets of miR-146a in ALK+ ALCL were investigated to identify its function.



**Principals/Methodology:** To identify the miR-146a target genes, transcriptome analysis of the ALK+ ALCL cell line SUDHL-1 with and without miR-146a overexpression using NGS was performed. Validation of the miR-146a target genes was performed by RT-qPCR, Western blot and Luciferase reporter assay. The functional characterization of the identified miR-146a target gene CD147 was performed in vitro by cell proliferation assay and in vivo by mice experiments and subsequent immunostainings.

**Results:** Transcriptome analysis identified ZNF275, SRPRB, PNPO and CD147 as miR-146a target genes. Because CD147 is also differentially expressed in ALK+ ALCL versus ALK- ALCL and normal T cells, this gene emerged as a strong candidate for the pathogenesis of this tumor. Here we demonstrate that CD147 contributes to the survival and proliferation of ALK+ ALCL cells in vitro and to the engraftment and tumor growth in vivo in an ALK+ ALCL-xenotransplant mouse model. CD147 knockdown in ALK+ ALCL cells resulted in loss of MCT1 expression, a transmembrane transporter of lactate. The loss of CD147-MCT1 complexes in ALK+ ALCL tumors resulted in reduced glucose consumption and tumour growth retardation, as demonstrated by [<sup>18</sup>F] FDG-PET/MRI analysis, indicating a strong “Warburg effect”. Additionally, the expression of MMP7, a downstream target of CD147 important for tumor invasion was lost after CD147 knockdown, suggesting that CD147 promotes also the invasion of ALK+ ALCL cells. Finally, angiogenesis, as demonstrated by CD31 and VEGFR2a expression, was clearly reduced in ALK+ ALCL xenograft tumors with CD147 knockdown.

**Conclusion:** Our findings indicate that the miR-146a target gene CD147 is of vital importance for ALK+ ALCL to maintain the high-energy demand of rapid cell proliferation, promotes lactate export, angiogenesis, invasion and tumor growth. Furthermore, CD147 has the potential to serve as a novel therapeutic target in ALK+ ALCL.

LYS-O-7-4

## Genetic evolution of clonally related in situ follicular neoplasia to diffuse large B-cell lymphoma of germinal center subtype

Antonio Vogelsberg<sup>1</sup>, Julia Steinhilber<sup>1</sup>, Janine Schmidt<sup>1</sup>, Irina Bonzheim<sup>1</sup>, Barbara Mankel<sup>1</sup>, Birgit Federmann<sup>1</sup>, Leticia Quintanilla-Martinez<sup>1</sup>, Falko Fend<sup>1</sup>

<sup>1</sup>Institute of Pathology and Neuropathology, University Hospital and Comprehensive Cancer Center Tuebingen, Tuebingen, Germany

**Background:** Diffuse large B-cell lymphoma (DLBCL) NOS is the most common non-Hodgkin lymphoma (NHL) and can be subdivided into germinal center B-cell (GCB) and activated B-cell type. DLBCL can arise as a transformation from indolent B-NHL, most commonly follicular lymphoma (FL), or manifest de novo. For primary cases, no precursor lesion is known. In contrast, in situ follicular neoplasia (ISFN) is well recognized as a precursor lesion of FL. Since DLBCL of GCB type frequently carries the t (14;18)(q32;q21) and can also develop as a transformation from FL, we speculated that some DLBCL may be derived from ISFN without clinically recognized FL as an intermediate stage. Thus, in this study we aimed to identify ISFN in patients with de novo or transformed DLBCL of GCB type to analyze the clonal relationship and potential evolution from ISFN to DLBCL.

**Principals/Methodology:** We searched our archive for DLBCL of GCB type with or without antecedent FL, for which reactive lymphoid tissue from any point in time was available. ISFN were identified by BCL2 staining and FISH to detect BCL2 rearrangements. The clonal relationship was investigated by standard clonality analysis, sequencing of the t (14;18) breakpoint and next generation sequencing (NGS) using the LymphoTrack IGH PGM™ assay. 22 genes frequently mutated in FL and DLBCL were analyzed using custom NGS panels.

**Results:** Seven paired cases of DLBCL/ISFN were identified, two de novo DLBCL and five transformed from FL. In two of these cases, focal FL was only identified retrospectively in the BCL2 stains of the “reactive” tissues. For six cases, a clonal relationship was firmly established, whereas it was implied in case 7 by a KMT2D mutation shared between the de novo DLBCL and the ISFN. In case 1, the ISFN already carried a CREBBP mutation, whereas the related de novo DLBCL gained further mutations in KMT2D, BCL2 and TP53. Case 2 showed surprising complexity with shared mutations in TNFRSF14, HIST1H1D, EP300 and BCL2 in ISFN and DLBCL lesions 13 years apart. Three cases revealed divergent evolution with both shared and private mutations in ISFN, FL and secondary DLBCL (Table 1).

**Conclusion:** Our study demonstrates for the first time that DLBCL of GCB type can arise from clonally related ISFN without clinically evident FL as an intermediate step. Similar to the clonal evolution and transformation of manifest FL, branched or complex evolution seems to be common in the progression from ISFN to DLBCL.

Gene	Case 1*		Case 2		Case 3		Case 4		Case 5		Case 6		Case 7*	
	DLBCL	ISFN	DLBCL	ISFN	DLBCL	ISFN	DLBCL	ISFN	DLBCL	ISFN	DLBCL	ISFN	DLBCL	ISFN
<i>EZH2</i>			p.Y646N				p.Y646N	p.Y646N	p.Y646F		p.Y646F	p.Y646F		p.Y646F
<i>KMT2D</i>	p.L5455fs				p.W4987*	p.W4987*								p.Q4473*
<i>GNAI3</i>														p.M68R p.D155A p.T201A p.R33M
<i>MEF2B</i>														
<i>HIST1H1B</i>										p.S107C				
<i>HIST1H1D</i>			p.N77K	p.N77K										p.T93S
<i>TNFRSF14</i>			p.W12*	p.W12*	p.V219G		p.S171C							
<i>EP300</i>			p.L415P	p.L415P										
<i>CREBBP</i>	p.Y1503D	p.Y1503D					p.L1499P	p.L1499P						
<i>CARD11</i>								p.S250P						
<i>PIM1</i>					p.E79D									
<i>CD79B</i>														p.Y196H
<i>BCL2</i>	p.W214C		p.P59S	p.P59S	p.G8E	p.G8E	p.D10A		p.L36F	p.L86F				p.P59S
			p.A76D		p.P75L		p.N11D			p.E135D				p.P53A
<i>TP53</i>	p.H179N													p.D102G

\*de novo DLBCL

Private mutations

Shared mutations

Table 1. Overview of the mutations identified in paired DLBCL/ISFN cases. Mutations of the intermediate FL are not shown.





# Lymphoma Symposium

---

Poster Presentations (LYS-P-2 – LYS-P-98)

## Lymphoma Symposium

### Poster Presentations (LYS-P-2 – LYS-P-98)

LYS-P-2

### Epstein - Barr virus leaves its mark: new evidence for “hit and run” hypothesis from non-conventional methods

Lucia Mundo<sup>1</sup>, Maria R. Ambrosio<sup>1</sup>, Leonardo Del Porro<sup>1</sup>, Gianluca Schiavoni<sup>2</sup>, Giuseppe Lo Bello<sup>1</sup>, Massimo Granai<sup>1</sup>, Stefano Lazzi<sup>1</sup>, Raffaella Santi<sup>3</sup>, Federica Vergoni<sup>3</sup>, Enrico Tiacchi<sup>2</sup>, Lorenzo Leoncini<sup>1,1</sup>  
<sup>1</sup>University of Siena, Siena, <sup>2</sup>University of Perugia, Perugia, <sup>3</sup>University of Florence, Florence, Italy

**Background:** Epstein-Barr virus (EBV) infection is a common feature of B-cell lymphoproliferative disorders, including Burkitt lymphoma (BL) and diffuse large B cell lymphoma (DLBCL), with a frequency ranging from 10% to virtually 100% in endemic BL cases. The possible contribution of EBV to B-cell lymphomas pathogenesis is largely unknown and it is unclear how infection and disease are linked. It has been recently demonstrated that EBV might be associated with all of the BL cases, including those diagnosed as EBV negative by routine methods [i.e. immunohistochemistry – IHC and EBV-encoded RNAs (EBER) in situ hybridization – ISH] thanks to a mechanism of hit-and-run. The aim of this study was to identify the presence of EBV infection in a series of “EBV negative” B-cell lymphomas by applying conventional and non-conventional methods (i.e. EBV viral load measurement; EBV-encoded microRNAs-miRNAs detection, RNAscope assay).

**Principals/Methodology:** We analyzed a total of 71 cases (14 BL, 29 DLBCL, 10 follicula lymphoma -FL and 18 Hodgkin lymphoma -HL) by performing EBER-ISH, Quantitative reverse transcription PCR (qPCR) targeting BamH1 W and EBNA-1, RT-PCR for EBV-encoded miRNAs BART9-5p, BART10-3p, BART19-3p, RNAscope assay, methylation status assesment of O<sup>6</sup>-methylguanine DNA methyltransferase (MGMT) and p16 genes.

**Results:** We diagnosed 8 EBER-positive and 6 -negative BL, 5 EBER-positive and 24 -negative DLBCL, 10 EBER-negative FL, 3 EBER-positive and 15 -negative HL. We focused on the EBER-negative samples in which we reported a significant presence of the virus in 100% (6/6) of BL, 46% (11/24) DLBCL, 30% FL (3/10) and 47% (7/15) HL. The viral load was higher in BL. The presence of the virus in EBER-negative cases was further confirmed by the presence of EBV-encoded miRNAs and by RNAscope that showed positive dot neoplastic cells. A significant hyper methylation of the target genes was observed in both EBER-positive and EBER-negative/qPCR-positive cases.

**Conclusion:** These findings highlight for the first time the possibility that EBV might contribute to the development of more cancers than simply those remaining viral genome-positive and, whether confirmed, may further support the rationale for strengthening the effort toward EBV vaccines that could potentially prevent the development of EBV-associated neoplasms, thus affecting the worldwide epidemiology of lymphomas.



LYS-P-3

## Screening for prognostic molecular signatures in symptomatic follicular lymphoma patients treated without chemotherapy

Ellen Leich-Zbat<sup>1</sup>, Tobias Schmidt<sup>2</sup>, Michael Altenbuchinger<sup>2</sup>, Marianne Brodtkorb<sup>3</sup>, Sandra Lockmer<sup>4</sup>, Harald Holte<sup>3</sup>, Chloe Beate Steen<sup>5</sup>, Theodora Nedeva<sup>1</sup>, Tina Grieb<sup>1</sup>, Jordan Pischmarov<sup>1</sup>, Birgitta Sander<sup>6</sup>, Crister Sundström<sup>7</sup>, Rainer Spang<sup>2</sup>, Eva Kimby<sup>8</sup>, Andreas Rosenwald<sup>1</sup> and Nordic Lymphoma Study Group

<sup>1</sup>Institute of Pathology, University of Würzburg, Würzburg, <sup>2</sup>Institute of Functional Genomics, University of Regensburg, Regensburg, Germany, <sup>3</sup>Department of Oncology, Oslo University Hospital, Oslo, Norway, <sup>4</sup>Department of Medicine at Huddinge, Karolinska Institute, Stockholm, Sweden, <sup>5</sup>Department of Informatics, Oslo University Hospital, Oslo, Norway, <sup>6</sup>Department of Laboratory Medicine, Division of Pathology, Karolinska Institute, Stockholm, <sup>7</sup>Department of Genetics and Pathology, Rudbeck Laboratory, Uppsala University Hospital, Uppsala, <sup>8</sup>Division of Hematology, Dept. of Medicine at Huddinge, Karolinska Institutet, Stockholm, Sweden

**Background:** Among B-cell non Hodgkin lymphoma, follicular lymphoma is the second most common entity. Survival times within this disease range from one year to more than two decades. Risk stratification with standard clinical parameters is challenging and often fails. Thus, many patients, who may profit from watch and wait or a mild treatment such as anti-CD20 antibodies alone might be over treated with immunochemotherapy.

**Principals/Methodology:** In order to find molecular signatures that allow for the prediction of efficacy of immunotherapy alone, we analyzed the gene expression and copy number profiles of 102 symptomatic follicular lymphoma patients randomized to rituximab alone or rituximab plus interferon in two clinical trials of the Nordic lymphoma study group. Specifically, gene expression and copy number profiles were assessed using whole genome arrays from Affymetrix and Nimblegen and analyzed statistically using Cox LASSO, LASSO logistic regression and Cox proportional hazard models.

**Results:** No predictive molecular signatures were found, but deletions in 17p11.2 (~20% of patients) and 17q21.31 (~27% of patients) affecting genes such as the serine hydroxymethyltransferase 1 (SHMT1) and the frizzled class receptor 2 (FZD2) were associated with an early treatment failure and an increased expression of the gene inositol polyphosphate-5-phosphatase B (INPP5B) was associated with a longer time to treatment failure.

**Conclusion:** With respect to more personalized treatment approaches, it might be thus useful to further explore the predictive role of the deletions in 17p11.2 and 17q21.31 and the expression levels of INPP5B for risk stratification in independent follicular lymphoma study cohorts.

LYS-P-4

## Validation of the MCL35 gene expression proliferation assay in randomized trials of the European Mantle Cell Lymphoma Network

Hilka Rauert-Wunderlich<sup>\*1,2</sup>, Anja Mottok<sup>3</sup>, David W. Scott<sup>4</sup>, Lisa M. Rimza<sup>5</sup>, German Ott<sup>6</sup>, Wolfram Klapper<sup>7</sup>, Michael Unterhalt<sup>8</sup>, Hanneke C. Kluin-Nelemans<sup>9</sup>, Olivier Hermine<sup>10,11</sup>, Sylvia Hartmann<sup>12</sup>, Christoph Thorns<sup>13</sup>, Grzegorz Rymkiewicz<sup>14</sup>, Harald Holte<sup>15</sup>, Martin Dreyling<sup>8</sup>, Eva Hoster<sup>8,16</sup>, Andreas Rosenwald<sup>1,2</sup>

<sup>1</sup>Comprehensive Cancer Center (CCC), Mainfranken, <sup>2</sup>Institute of Pathology, University of Wuerzburg, Wuerzburg, <sup>3</sup>University Hospital of Ulm, Ulm, Germany, <sup>4</sup>British Columbia Cancer Agency, Vancouver, Canada, <sup>5</sup>Mayo Clinic, Scottsdale, United States, <sup>6</sup>Robert-Bosch Krankenhaus, Stuttgart, <sup>7</sup>Hematopathology Section and Lymph Node Registry, University of Kiel, Kiel, <sup>8</sup>University Hospital of the Ludwig Maximilians University Munich, Munich, Germany, <sup>9</sup>University Medical Center Groningen, University of Groningen, Groningen, Netherlands, <sup>10</sup>Imagine Institute, University of Sorbonne Paris City, <sup>11</sup>Department of Hematology, University Paris Descartes, Paris, France, <sup>12</sup>Dr. Senckenberg Institute of Pathology, Goethe University, Frankfurt am Main, <sup>13</sup>Institute of Pathology, Marienkrankenhaus, Hamburg, Germany, <sup>14</sup>Department of Pathology and Laboratory Diagnostics, Maria Skłodowska-Curie Institute-Oncology Center, Warsaw, Poland, <sup>15</sup>Department of Oncology, Oslo University Hospital, Oslo, Norway, <sup>16</sup>Institute for Medical Information Processing, Biometry and Epidemiology, Ludwig Maximilians University Munich, Munich, Germany

**Background:** Mantle cell lymphoma (MCL) is still considered incurable and the course of the disease is highly variable. Established risk factors include the Mantle Cell Lymphoma International Prognostic Index (MIPI) and the quantification of the proliferation rate of the tumour cells, e.g. by Ki-67 immunohistochemistry. In this study, we aimed to validate the prognostic value of the gene expression-based MCL35 proliferation assay in patient cohorts from randomized trials of the European Mantle Cell Lymphoma Network.

**Principals/Methodology:** Using this assay, we analysed the gene expression proliferation signature in routine diagnostic lymph node specimens from MCL Younger and MCL Elderly trial patients.

**Results:** The calculated MCL35 score was used to assign MCL patients to low (61%), standard (27%) or high (12%) risk groups with significantly different outcomes.

**Conclusion:** We confirm here in our prospective clinical trial cohort of MCL patients, that the MCL35 assay is strongly prognostic providing additional information to the Ki-67 index and the MIPI. Thus, this robust assay may assist in making treatment decisions or in devising risk-adapted prospective clinical trials in the future.

## MYC translocation positive diffuse large B-cell lymphoma has a distinct mutational spectrum

Francesco Cucco<sup>1</sup>, Sharon Barrans<sup>2</sup>, Alexandra Clipson<sup>1</sup>, Joe Sneath Thompson<sup>1</sup>, Rachel Dobson<sup>1</sup>, Hannah Kennedy<sup>1</sup>, Ming Wang<sup>1</sup>, Daniel Painter<sup>3</sup>, Alexandra Smith<sup>3</sup>, Chulin Sha<sup>4</sup>, Josh Caddy<sup>5</sup>, Thomas Cummin<sup>6</sup>, Eve Roman<sup>3</sup>, David R Westhead<sup>4</sup>, Cathy Burton<sup>2</sup>, Andrew J Davies<sup>6</sup>, Peter Johnson<sup>6</sup>, Ming-Qing Du<sup>1,7</sup>

<sup>1</sup>Department of Pathology, University of Cambridge, Cambridge, <sup>2</sup>HMDS, Leeds Cancer Centre, Leeds Teaching Hospitals NHS Trust, Leeds, <sup>3</sup>ECSG, Department of Health Sciences, Seebohm Rowntree Building, University of York, Heslington, York, <sup>4</sup>School of Molecular and Cellular Biology, University of Leeds, Leeds, <sup>5</sup>Southampton Clinical Trials Unit, <sup>6</sup>Cancer Research UK Clinical Centre, University of Southampton, Southampton, <sup>7</sup>Department of Histopathology, Addenbrooke's Hospital, Cambridge University Hospitals NHS Foundation Trust, Cambridge, United Kingdom

**Background:** MYC translocation occurs in ~10% of diffuse large B-cell lymphoma (DLBCL), and its prognostic value appears to depend critically on the second hit. In comparison with the DLBCL bearing an isolated MYC translocation, those with additional TP53 mutation and/or BCL2 translocation had a significantly worse overall survival (1). At a molecular level, MYC translocation cooperates with both TP53 inactivation and BCL2 over-expression in lymphomagenesis as the latter changes potentially impede the intrinsic pro-apoptotic activity of MYC. Apart from TP53 mutation and BCL2/BCL6 translocations, the genetic profile in MYC translocation positive DLBCL remains largely uncharacterised.

**Principals/Methodology:** A total of 335 cases of DLBCL from the REMoDL-B trial (n=253) and population based cohort (n=82), including 110 with a MYC translocation, were investigated for mutation in 70 genes that are recurrently involved in aggressive B-cell lymphoma by HaloplexHS target enrichment and Illumina HiSeq sequencing (2). Cell of origin was performed by transcriptomic profiling using Illumina WG-DASL assay and classification using DAC (3).

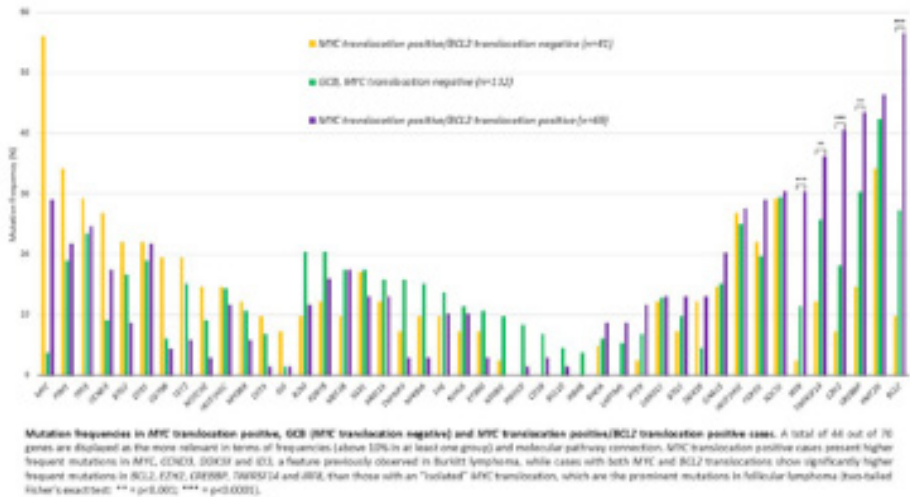
**Results:** The majority (86%) of MYC translocation positive DLBCL were germinal centre B-cell like (GCB) subtype. In comparison with GCB-DLBCL without MYC translocation (n=132), MYC translocation positive cases had significantly higher frequency of mutations in MYC, CCND3 and DDX3X, a feature previously observed in Burkitt lymphoma. Interestingly, DLBCL with both MYC and BCL2 translocations (n=69) showed significantly higher frequent mutations in BCL2, EZH2, CREBBP, TNFRSF14 and IRF8, than those with an "isolated" MYC translocation (n=41), which are the prominent mutations in follicular lymphoma. Furthermore, DLBCL with both MYC and BCL2 translocations displayed lower frequencies of mutation in CD79B, NOTCH2 and TET2 than those with an "isolated" MYC translocation, while TP53 mutation was at a similar frequency between the two sub-groups.

**Conclusion:** The results show distinct differences in the mutation profile between MYC translocation positive DLBCL and GCB-DLBCL without MYC translocation. DLBCL with both MYC and BCL2 translocations share the cardinal mutational profile of follicular lymphoma, suggesting that these double-hit lymphomas may be derived from transformation of an occult follicular lymphoma or t(14;18)(q32;q21)/IGH-BCL2 positive cells.

### References:

1- Clipson A. et al., J Pathol Clin Res, 2015; 2- Cucco F. et al., Lab Invest, 2018; 3- Care MA. et al., PLoS one, 2013.

## Image:



LYS-P-6

## MyC-related micrnas signatures in non-hodgkin b-cell lymphomas and their relationships with core cellular pathways

Giorgio Malpeli<sup>1</sup>, Stefano Barbi<sup>1</sup>, Gabriele Tosadori<sup>2</sup>, Corinna Greco<sup>3</sup>, Mauro Krampera<sup>3</sup>, Paul Takam Kamga<sup>3</sup>, George A. Calin<sup>4</sup>, Carlo M. Croce<sup>5</sup>, Alberto Zamò<sup>6</sup>, Aldo Scarpa<sup>7</sup>

<sup>1</sup>Diagnosics and Public Health, <sup>2</sup>Center for Biomedical Computing, <sup>3</sup>Department of Medicine, University of Verona, Verona, Italy, <sup>4</sup>Department of Experimental Therapeutics, The University of Texas MD Anderson Cancer Center, Houston, TX, <sup>5</sup>Department of Molecular Virology, The Ohio State University, Columbus, OH, United States, <sup>6</sup>Department of Oncology, University of Turin, Turin, <sup>7</sup>Department of Diagnostics and Public Health, University of Verona, Verona, Italy

**Background:** The transcription factor MYC is a key driver in the lymphomagenesis (1). MYC overexpression in B cell lymphomas promotes tumor survival and aggressiveness of the disease through a complex interplay of different signaling pathways including the modulation of microRNAs (miRNA) and of their gene targets (2,3).

**Principals/Methodology:** In order to investigate the role of microRNAs in the pathogenesis of different B-cell lymphoma subtypes, we have applied an array-based assay to a series of 76 mixed non-Hodgkin B-cell lymphomas, including Burkitt's lymphoma (BL), diffuse large B-cell lymphoma, primary mediastinal B-cell lymphoma, mantle cell lymphoma (MCL) and follicular lymphoma. The same series was then quantitatively analyzed for MYC expression by immunohistochemistry and MYC protein levels were compared with corresponding miRNA signatures.

**Results:** Lymphomas clustered according to histological subtypes, driven by two miRNA clusters (the miR-29 family and the miR-17-92 cluster). Since the two miRNA clusters are known to be MYC-regulated,



we investigated whether this would be supported in MYC-driven experimental models. We found that MYC-related miRNA signatures are directly related to MYC protein expression across the whole spectrum of B-cells and B-cell lymphoma, suggesting that the MYC-responsive machinery shows predominantly quantitative, rather than qualitative, modifications in B-cell lymphoma (Figure 1). Novel MYC-related miRNAs were also discovered. Finally, network analysis found that in BL MYC-related differentially expressed miRNAs could control, either positively or negatively, a limited number of hub proteins, including BCL2, CDK6, MYB, ZEB1, CTNNB1, BAX and XBP1.

**Conclusion:** We identified miRNA signatures across the whole spectrum of NHBCLs as well as in BL and MCL cell lines. These comparisons lead to the recognition of known and new miRNA clusters correlated with MYC<sup>+</sup> cell counts.

**References:**

1. The Role of c-MYC in B-Cell Lymphomas: Diagnostic and Molecular Aspects. Nguyen L. et al. *Genes* (Basel). 2017 Apr 5;8(4)
2. The MYC/miR-17-92 axis in lymphoproliferative disorders: A common pathway with therapeutic potential. Dal Bo M. et al. *Oncotarget*. 2015 Aug 14;6(23):19381-92
3. Malpeli G. et al. MicroRNA signatures and Foxp3<sup>+</sup> cell count correlate with relapse occurrence in follicular lymphoma. *Oncotarget*. 2018 Apr 13;9(28):19961-19979

LYS-P-7

## CDKN2A alteration in PTCL with a TFH phenotype: a recurrent event that could confer a sensitivity to MDM2 inhibitors

Clemence Loiseau<sup>1</sup>, George Allen<sup>2</sup>, Loeticia Favre<sup>1</sup>, Laura Pelletier<sup>3</sup>, Aurélie Dupuy<sup>3</sup>, Nadine Martin<sup>3</sup>, Anais Pujals<sup>4</sup>, Virginie Fataccioli<sup>5</sup>, Nicolas Ortonne<sup>3</sup>, Pamela Dobay<sup>2</sup>, Laurence de Leval<sup>2</sup>, Francois Lemonnier<sup>6</sup>, philippe Gaulard<sup>5</sup>

<sup>1</sup>U955, IMRB, Creteil, France, <sup>2</sup>departement de pathologie, CHUV, Lausanne, Switzerland, <sup>3</sup>U955, IMRB, Créteil, <sup>4</sup>departement de pathologie, Henri Mondor hospital, Creteil, <sup>5</sup>departement de pathologie, <sup>6</sup>Unité Hémopathies Lymphoïdes, Henri Mondor hospital, Créteil, France

**Background:** Peripheral T Cell Lymphomas with a TFH phenotype (TFH-PTCL) are the most frequent nodal PTCL, associated with a poor survival when treated by chemotherapy. They are characterized at the molecular level by frequent mutations in TET2, IDH2, DNMT3A, RHOA and TCR signaling. However, TP53 alterations are uncommon in this entity, and whether CDKN2A deletions are recurrent in these lymphomas has not been investigated so far. Indeed, CDKN2A is frequently deleted in various lymphomas entities and this deletion is associated with a decreased of p14(ARF), resulting in the disinhibition of the E3-ubiquitin ligase MDM2 and the excessive degradation of P53. This could have therapeutic relevance as MDM2 inhibitors are currently tested in clinical trial.

**Principals/Methodology:** We investigated CDKN2A deletion by fluorescent in situ hybridation (FISH) in 50 patients (AITL=43, nodal PTCL with TFH phenotype=7) with available molecular (gene expression profile and targeted deep sequencing) and clinical data. T cell lymphomas cell lines representing various entities and genotype were treated by MDM2 inhibitors (Nutlin-3a and RG7338) and cell line proliferation was investigated by MTT test.

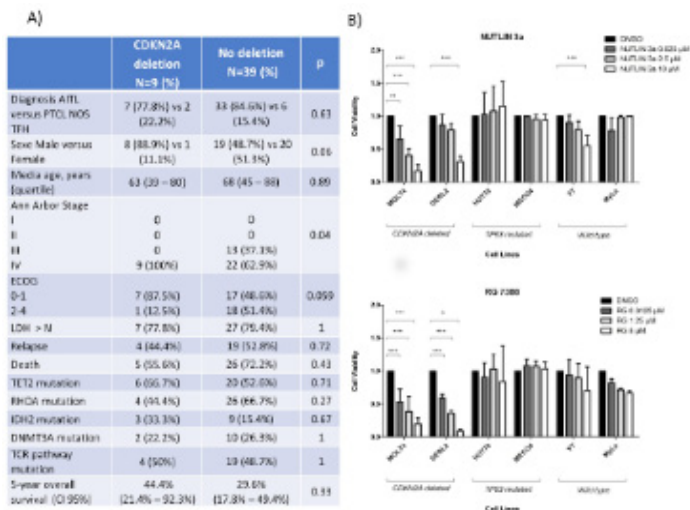
**Results:** Among 47 evaluable patients with TFH PTCL, we detected monoallelic CDKN2A deletion in 8 patients (17%). These deletions were present in ICOS positive AITL tumors cells. CDKN2A deletion was not associated with peculiar clinical presentation, or mutational profile. Especially, within the limit of our series, it was not associated with a shorter survival (Figure 1A).

We compared gene expression profile from deleted cases and germline cases. Interestingly, CDKN2A deleted cases had a lower level of CDKN2A transcript than germline ( $p=0.02$ ), and GSEA studies found an impaired TP53 dependent signaling pathway in deleted cases, indicating that these deletions have functional consequences.

We sequenced TP53, CDKN2A and investigated CDKN2A deletion in various T cell lymphoma cell lines. We compared response to Nutlin-3a and RG7338 in 2 CDKN2A deleted/TP53WT, 2 CDKN2A WT/TP53 WT and in 2 TP53 mutated cell lines. As shown in Figure 1B, response was better in CDKN2A deleted/TP53WT cell lines, regardless of histology.

**Conclusion:** CDKN2A deletion appears to be a frequent oncogenic event in TFH PTCL, which disturbs the P53 signaling. In vitro studies suggest that CDKN2A deletion could be a biomarker of response to MDM2 inhibitors in PTCL.

**Image:**



LYS-P-8

**Histiocytic neoplasms with myeloid neoplasm-associated genetic alterations suggest hematopoietic stem cells as a cell of origin**

Mariko Yabe<sup>1</sup>, Kseniya Petrova-Drus<sup>1</sup>, Benjamin H. Durham<sup>2</sup>, Omar Abdel-Wahab<sup>2</sup>, Raajit K. Rampal<sup>3</sup>, Eli L. Diamond<sup>4</sup>, Ahmet Dogan<sup>1</sup>

<sup>1</sup>Hematopathology, <sup>2</sup>Human Oncology and Pathogenesis Program, <sup>3</sup>Leukemia Service, <sup>4</sup>Department of Neurology, Memorial Sloan Kettering Cancer Center, New York, United States

**Background:** Histiocytic neoplasms are rare and heterogeneous disorders derived from mononuclear phagocytes (macrophages and dendritic cells) or histiocytes, accounting for <1% of tumors presenting in the lymph nodes or soft tissue.<sup>1</sup> Among them, Langerhans cell histiocytosis (LCH) and Erdheim-Chester



disease (ECD) are known to have recurrent mutations activating MAPK signaling, including BRAF, NRAS, KRAS, ARAF, and MAP2K1. High prevalence of myeloid neoplasms has been reported in association with ECD, and bone marrow myeloid progenitor cells are reported to contain BRAF V600E alleles in patients with LCH and ECD.<sup>2,3</sup> These findings support the hematopoietic progenitor cells as a cell-of-origin of LCH and ECD; however, it is rare for histiocytic neoplasms to harbor genetic alterations commonly seen in myeloid neoplasm such as TET2.

**Principals/Methodology:** Cases with histiocytic neoplasms diagnosed at Memorial Sloan Kettering Cancer Center between January 2012 and April 2018 were reviewed. Genomic analysis was performed either using MSKCC IMPACT or an amplicon based myeloid gene panel NGS assay, as previously described.<sup>4</sup>

**Results:** 15 patients with histiocytic neoplasms were found to have myeloid neoplasm-associated genetic alterations. Among these, 3 cases (case 1-3) had TET2 mutations in histiocytic neoplasm. Case 4 shared same TP53 mutation in histiocytic sarcoma and CMML, and case 5 shared JAK2 mutation in ECD and myelofibrosis. Case 6 and case 7 shared same NRAS and KRAS mutations in ECD and bone marrow, respectively. 8 patients (case 8-15) showed myeloid neoplasm-related mutations in bone marrow/peripheral blood, and these mutations were not detected or not tested in concomitant histiocytic neoplasms.

**Conclusion:** Myeloid neoplasm-associated genetic alterations, such as TET2 mutations, can be seen in histiocytic neoplasms. These findings give another support for a hematopoietic stem cell as an origin of histiocytic neoplasms.

**References:**

1. Pileri SA, et al. WHO Classification of Tumours of Haematopoietic and Lymphoid Tissue. Lyon: IARC; 2017: 466-482.
2. Papo M, et al. Blood. 2017; 130(8): 1007-1013.
3. Milne P, et al. Blood. 2017; 130(2): 167-175.
4. Cheng DT, et al. J Mol Diagn. 2015; 17(3): 251-264.

**Image:**

Case #	Specimen	Diagnosis	Corresponding molecular results
1	Left neck mass BM	monocytic/histiocytic neoplasm monocytic/histiocytic neoplasm	TET2 p.C1221S, TET2 p.C1289Y NA
2	Lymph node, axilla	LCH	TET2 p.N1774fs, TET2 p.N442fs, BRAF in progress
3	Lung	LCH	TET2 p.C1133Y, BRAF p.V600E, ASXL1 p.Q815*
4	Spleen, Abdominal mass BM	Histiocytic sarcoma CMML	NRAS p.Q61H, PIK3CD p.G124D, TP53 p.Q144fs TP53 p.Q144fs
5	Peri-renal tissue, Brain BM biopsy and aspirate	ECD Myelofibrosis	BRAF wild type, JAK2 p.V617F JAK2 p.V617F, IDH1 p.Y153S
6	Kidney, Paraspinal mass BM biopsy and aspirate	ECD CMML	NRAS p.Q61R NRAS p.Q61R
7	Heart, right atrial BM aspirate	ECD NA	KRAS p.G12S KRAS p.G12S
8	Tibia BM biopsy and aspirate	ECD CMML	BRAF p.V600E JAK2 p.V617F, IDH1 p.R140Q
9	Peri-renal tissue Peripheral blood	ECD NA	BRAF p.V600E TET2 p.Q754fs, TET2 p.H1380Y
10	Orbital mass BM	ECD Essential thrombocythemia	BRAF p.V600E CALR p.L387fs
11	Lung BM	ECD CMML	BRAF p.V600E ASXL1 p.Q755*, NRAS p.G15D
12	Oropharynx Lung, Scapula BM	LCH ECD MDS-EB-1	NA BRAF p.V600E IDH1 p.R140Q, TP53 p.N131K
13	Testis Peripheral blood	RDD NA	BRAF wt TET2 p.R1216*, TP53 p.H179R DNMT3A exon9 splicing
14	Vaginal lesion, Liver BM	LCH CMML	NA TET2 p.H937fs, TET2 p.E1106fs
15	Skin, left arm BM	Histiocytic neoplasm Myeloid neoplasm	NA TET2 p.G1956V

LYS-P-9

## TP53 mutations are enriched in Mantle cell lymphoma with negative and low SOX11 expression demonstrated by in situ hybridization assay for quantification of SOX11 mRNA expression

Birgit Federmann<sup>\*1</sup>, Helga Pertsch<sup>1</sup>, Julia Steinhilber<sup>1</sup>, Irina Bonzheim<sup>1</sup>, Leonie Frauenfeld<sup>1</sup>, Falko Fend<sup>1</sup>, Leticia Quintanilla-Martinez<sup>1</sup>

<sup>1</sup>*Institute of Pathology and Neuropathology, CCC and University Hospital Tuebingen, Tuebingen, Germany*

**Background:** SOX11 is a valuable marker to identify groups of Mantle cell lymphoma (MCL) such as cyclin D1 negative MCL (D1-MCL) and leukemic non-nodal MCL (nnMCL), but the prognostic relevance of SOX11 in MCL is controversial. SOX11 expression is usually investigated by immunohistochemistry (IHC). Because IHC is not quantitative, we aimed to establish a sensitive in situ hybridization (ISH) analysis of SOX11 mRNA allowing its quantification within the histopathological context and compare it with IHC and RT-PCR. The TP53 status was correlated with SOX11 mRNA expression levels.

**Principals/Methodology:** 66 cases were investigated including 53 cases of conventional MCL (cMCL) (13 with blastoid morphology), 6 cases of D1-MCL, and 7 cases of nnMCL. 12 cases were used as controls (4 FL, 4 CLL, 4 MZL). RNAscope was used for the RNA ISH (Discovery Ventana autostainer). RNAscope was scored as 0 (no signals), Scores 1 to 4 as positive. Score 0-1 were considered low, score 2 intermediate, score 3-4 high expression. RT-PCR was performed to quantify SOX11 mRNA levels. All cases were stained for p53 and TP53 sequence analysis performed by NGS (Ion Torrent PGM platform).

**Results:** MCL cases with SOX11 positivity by IHC were positive by RNAscope but with different scores (22 cases score 4, 13 cases score 3, 12 cases score 2, 10 cases score 1, 7 cases score 0). RT-PCR had a good correlation with the median of the grouped ISH-scores but a wide variation in individual cases. The D1-MCL cases had higher SOX11 mRNA expression levels than D1+MCL cases (RNAscope and RT-PCR). The SOX11 negative nnMCL and the negative controls were also negative by ISH. 11/66 (17%) cases were TP53 mutated with 4/7 (57%) nnMCL SOX11 negative and 7/59 (12%) cMCL. Interestingly, of the TP53 mutated cases 8 were in the low SOX11 expression group (8/17; 47%) and 3 in the high expression group (3/35; 9%). The difference was significant ( $p=0.02$ ). Of the cMCL, the TP53 mutated cases showed the lowest SOX11 expression including cases with blastoid morphology.

**Conclusion:** RNAscope ISH is a reliable method for detection of target RNA and can be used in daily routine to evaluate SOX11 mRNA expression. There is a good correlation between SOX11 expression at the mRNA and protein level, however the RT-PCR shows a high variation, making RNAscope a more reliable method. This study demonstrates the broad range of SOX11 expression in MCL. An important finding is that TP53 mutations are enriched in nnMCL but also in cMCL with low SOX11 expression, which warrants further investigation.



LYS-P-10

## Post-transcriptional modifications of small RNAs as prediction signatures for response to R-CHOP treatment in Diffuse Large B-cell Lymphoma

C. Scheepbouwer<sup>1,2</sup>, S. Giannoukakos<sup>1</sup>, E. Aparicio<sup>3</sup>, H. Verschueren<sup>1</sup>, B. Misovic<sup>1</sup>, J. Boele<sup>1</sup>, J.M. Zijlstra-Baalbergen<sup>4</sup>, R.E. Kibbelaar<sup>5</sup>, M. Hackenberg<sup>3</sup>, D. de Jong<sup>2</sup>, D. Koppers-Lalic<sup>1,2</sup>  
<sup>1</sup>Neurosurgery, <sup>2</sup>Pathology, VU Medical Center, Amsterdam, Netherlands, <sup>3</sup>Genetics, University of Granada, Granada, Spain, <sup>4</sup>Hematology, VU Medical Center, Amsterdam, <sup>5</sup>Pathology, Stichting HemoBase, Leeuwarden, Netherlands

**Background:** In diffuse large B-cell lymphoma (DLBCL), genomic and gene expression profiling still contributes insufficiently to specifically identify immuno-chemotherapy resistant phenotypes and thus provides very limited guidance to select DLBCL patients for early-personalized treatment. Extensive post-transcriptional remodeling of small non-coding (snc)RNA classes have been shown to coordinate RNA activity to adapt cellular processes in response to cancer therapy and integrated genomic data analysis suggests RNA modifications may result in therapy resistance. Therefore, analysis of RNA modifications may provide an important additional layer of information needed to identify molecular predictors of DLBCL chemo-resistance.

**Principals/Methodology:** To address whether sncRNA classes (e.g. microRNA, tRNA, snoRNA) may serve as diagnostic predictors of therapy resistance in DLBCL, we performed a comprehensive analysis of the sncRNA transcriptome from DLBCL tissue biopsies taken at diagnosis (fresh frozen material; n=20 good response to R-CHOP and n=20 poor response to R-CHOP). SncRNA sequencing data was generated by the small RNA Illumina platform. A custom-made computational package was used to examine the sncRNA repertoire and its epi-transcriptomic diversification and analyzed in the context of complete clinical information.

**Results:** Significant variation between the relative abundance and modifications of sncRNA classes was seen, indicating significant differential sncRNA processing and modification in DLBCL. Most importantly, distinctive tRNA-derived (tRFs) repertoires could separate patients according to treatment response. Processing patterns were highly suggestive to correspond with known tRNA base modifications, which are crucial for tRNA structure and stability as well as for tRNA function in protein synthesis/cellular metabolism. The posttranscriptional modifications are likely responsible for the differential tRF repertoires in treatment-resistant versus treatment response DLBCL.

**Conclusion:** Different tRNA types and post-transcriptional modifications in treatment-sensitive versus treatment resistant DLBCL result in specific tRF repertoires. Based on this study, tRNA/tRFs repertoires should be further explored as potentially valuable prognostic biomarkers in DLBCL. In general, we propose that patterns of cancer-driven variation of post-transcriptional RNA modifications might provide an important novel layer of information to currently explored DNA and mRNA assays.

LYS-P-11

## MHC class II transactivator (CIITA) abnormalities are frequent in B-cell lineage lymphomas and are associated with loss of MHC Class II (MHCII) expression

Fatima Zahra Jelloul<sup>1</sup>, Janine Pichardo<sup>1</sup>, Achim Jungbluth<sup>1</sup>, Lu Wang<sup>1</sup>, Connie Batlevi<sup>1</sup>, Maria Arcila<sup>1</sup>, Yanming Zhang<sup>1</sup>, Ahmet Dogan<sup>1</sup>

<sup>1</sup>Pathology, Memorial Sloan Kettering Cancer Center, New York, United States

**Background:** CIITA is the master regulator of MHCII antigen presenting pathway. CIITA mutations and fusions have been reported in primary mediastinal B-cell lymphoma (PMBL), and Classic Hodgkin lymphoma (CHL) and is believed to reduce MHCII expression, contributing to immune escape and adverse outcomes. CIITA protein expression has not been studied in normal and neoplastic lymphoid cells. The aims of this study were to evaluate CIITA protein expression in normal lymphoid tissues, study the frequency of CIITA mutations and protein expression in B-cell lymphomas and evaluate the correlation of CIITA mutations with CIITA and MHCII protein expression.

**Principals/Methodology:** CIITA mutations and fusions were investigated in 590 B-cell lymphoma cases as part of a targeted hybridization capture NGS assay. FISH studies were performed in selected cases. Tissue samples from 10 normal lymphoid tissues and 304 B cell lymphomas including 90 CHL, 52 DLBCL, 46 PMBL, 37 follicular lymphoma (FL), 29 marginal zone lymphoma (MZL), 24 mantle cell lymphoma (MCL) and 26 small lymphocytic lymphoma (SLL) were evaluated for CIITA and MHCII expression by immunohistochemistry (IHC). Expression was scored as positive if >20% of tumor cells expressed of CIITA and/or MHCII.

**Results:** NGS and FISH assays identified 39 B-cell lymphomas with deleterious mutation/fusions of CIITA (Figure1). Fusions were confirmed by FISH. CIITA and MHCII were uniformly expressed by normal B-cell subsets. Overall, CIITA and MHCII expression were concordant in 240/304 (79%). Among the discordant cases, 43/64 (67.2%) had loss of MHCII expression with retained expression of CIITA and 21/64 (32.8%) had loss of CIITA with retained expression of MHCII. Among different subsets of lymphomas, loss of both CIITA and MHCII expression was more commonly seen in DLBCL (28.8%), MCL (25%), CHL (17.8%) and PMBL (15.2%). Loss of CIITA and MHCII expression was more common in B cell lymphomas with CIITA mutations/fusions than in B cell lymphomas without CIITA mutations/fusions, however this was not statistically significant ( $p=0.0637$ , Fisher's exact test).

**Conclusion:** Our study shows that CIITA mutations/fusions are seen in a small proportion of B cell lymphomas with a higher frequency seen in PMBCL, CHL and DLBCL. CIITA expression loss is frequent in B cell lymphoma with concordant MHCII loss. Loss of CIITA and MHCII expression is an important immune escape mechanism in B cell lymphoma with potential implications for immune mediated therapies.



Image:

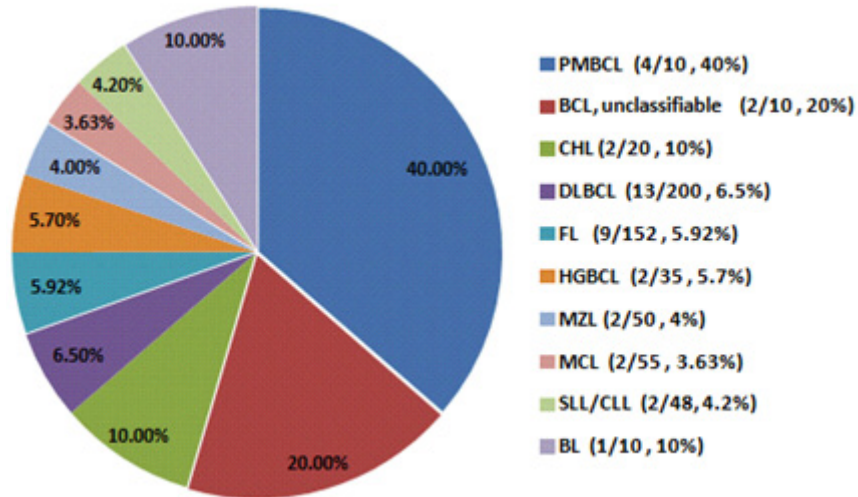


Figure 1.

LYS-P-12

## In situ follicular neoplasia lacks activation-induced cytidine deaminase

Tanu Goyal<sup>1</sup>, Sarah Ondrejka<sup>1</sup>, Lisa Durkin<sup>1</sup>, Juraj Bodo<sup>1</sup>, Eric D. Hsi<sup>1</sup>

<sup>1</sup>Laboratory Medicine, Cleveland Clinic, Cleveland, United States

**Background:** Activation-induced cytidine deaminase (AID), an enzyme present in germinal center (GC) centroblasts, initiates somatic hypermutation (SHM) and class switch recombination (CSR). AID is expressed in a proportion of B-NHLs of GC phenotype. Follicular lymphoma (FL) shows heterogeneity in the SHM pattern and AID expression. The indolent duodenal type FL was previously shown to lack AID. In situ follicular neoplasia (ISFN) is a FL variant with partial/total colonization of GCs by BCL2+/CD10+ B cells in an architecturally preserved lymph node. Given the variability of AID expression in FL and its absence in duodenal type FL, we explored AID expression in ISFN.

### Principals/Methodology:

Cases diagnosed as ISFN from 2002-2016 were identified and re-reviewed. Clinical information was obtained by review of the medical records. AID/BCL2 double immunofluorescence (DIF) staining was performed on 16 ISFN and a comparison group of 15 low grade FLs from a microarray constructed during the same time period. Images were analyzed with the Image-Pro Plus software (Media Cybernetics; Silver Spring, MD). Samples with ≥10% AID/BCL2 co-expressing cells within follicles were considered as AID-positive.

**Results:** The 16 ISFN patients (6 male, 10 female) had a median age of 66 (range 50–83 years) and all were incidentally discovered during pathologic examination of biopsies performed for a variety of clinical indications. Clinical information was available for 13 patients. Two patients had history of FL, one patient

had concurrent FL of another site, and six patients had other hematolymphoid neoplasms. None of the patients developed FL on median follow up 36 months (range 9-97 months). DIF staining demonstrated GC cells strongly positive for BCL2, and negative for AID in all 16 ISFN cases. 6 of 15 (47%) FL cases were double positive for BCL2/AID. This difference was statistically significant ( $P = .007$ , Fisher Exact).

**Conclusion:** Like duodenal type FL, ISFN appears to lack AID expression. In contrast, approximately half of low grade FLs expresses AID in neoplastic follicles. AID expression in GC B cells with prolonged lifespan due to IGH/BCL2 translocation may propagate continuous SHM and CSR resulting in increased genomic instability. The absence of AID, leading to decrease in ongoing SHM and lesser degree of genetic alterations, may be related to genetic stability and benign behavior of ISFN.

LYS-P-13

## Mutation screening using formalin-fixed paraffin-embedded tissues: a stratified approach according to DNA quality

Francesco Cucco<sup>1</sup>, Alexandra Clipson<sup>1</sup>, Hannah Kennedy<sup>1</sup>, Joe Sneath Thompson<sup>1</sup>, Ming Wang<sup>1</sup>, Sharon Barrans<sup>2</sup>, Moniek van Hoppe<sup>2</sup>, Eguzkine Ochoa Ruiz<sup>1</sup>, Josh Caddy<sup>3</sup>, Debbie Hamid<sup>3</sup>, Thomas Cummin<sup>4</sup>, Cathy Burton<sup>5</sup>, Andrew J Davies<sup>4</sup>, Peter Johnson<sup>4</sup>, Ming-Qing Du<sup>1,6</sup>

<sup>1</sup>Department of Pathology, University of Cambridge, Cambridge, <sup>2</sup>HMDS, Leeds Cancer Centre, Leeds Teaching Hospitals NHS Trust, Leeds, <sup>3</sup>Southampton Clinical Trials Unit, <sup>4</sup>Cancer Research UK Clinical Centre, University of Southampton, Southampton, <sup>5</sup>HMDS, Leeds Teaching Hospitals NHS Trust, Leeds, <sup>6</sup>Department of Histopathology, Cambridge University Hospitals NHS Foundation Trust, Cambridge, United Kingdom

**Background:** DNA samples from FFPE tissues are highly degraded with variable quality, and this imposes a big challenge for mutation analysis due to false positives by PCR errors and cytosine deamination. To eliminate false positives, a common practice is to validate the detected variants by Sanger sequencing or perform targeted sequencing in duplicate. Technically, PCR errors could be removed by molecular barcoding of template DNA prior to amplification as in the HaloPlexHS design. Nonetheless, it is uncertain to what extent variants detected using this approach should be further validated.

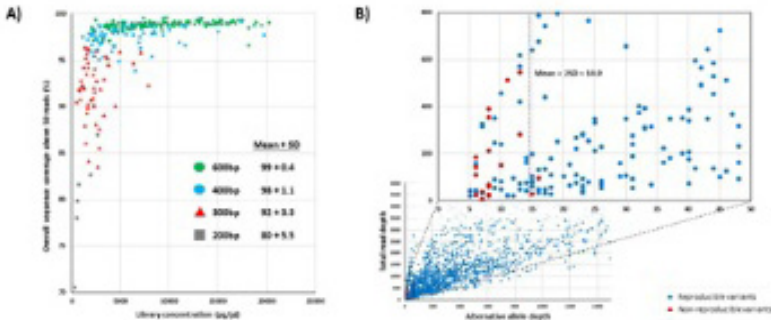
**Principals/Methodology:** DNA quality was assessed by PCR of variably sized genomic fragments under a standardised protocol. Targeted sequencing of 70 lymphoma associated genes was carried out using HaloPlexHS target enrichment and Illumina HiSeq4000, together with an in-house validated variant calling algorithm.

**Results:** The overall sequencing coverage, as shown by analyses of 70 genes in 266 cases of large B-cell lymphoma, was excellent (98%) in DNA samples amenable for PCR of  $\geq 400$ bp, but suboptimal (92%) and poor (80%) in those amenable for PCR of 300bp and 200bp respectively. By mutation analysis in duplicate in 93 cases, we demonstrated that 20 alternative allele depth (AAD) was an optimal cut-off value for separating reproducible from non-reproducible variants in DNA samples amenable for PCR of  $\geq 300$ bp, with 97% sensitivity and 100% specificity. By cross validation with a previously established targeted sequencing protocol by Fluidigm-PCR and Illumina MiSeq, the HaloPlexHS protocol was shown to be highly sensitive and specific in mutation screening.

**Conclusion:** We proposed a stratified approach for mutation screening by HaloPlexHS and Illumina HiSeq4000 according to DNA quality. DNA samples with good quality ( $\geq 400$ bp) are amenable for mutation analysis with a single replicate, with only variants at 15-20 AAD requiring for further validation, while those with suboptimal quality (300bp) are better analysed in duplicate with reproducible variants at  $> 15$  AAD regarded as true genetic changes.



Image:



**Impact of DNA quality on sequence coverage and variant detection reproducibility.** **A)** Correlation among DNA quality, target library quantity and overall sequence coverage (950 reads). In general, DNA samples that support PCR of >400bp genomic fragment yield much higher quantity of target sequence libraries and excellent sequencing coverage, while those that support PCR of only up to 300bp genomic fragment generate much lower quantity of target sequence libraries and suboptimal sequencing coverage. Mean and SD of sequencing coverage are provided according to DNA quality. **B)** Alternative allele depth (AAD) as an effective parameter in dichotomy between reproducible and non-reproducible variants. In general, the AAD value for non-reproducible variants is low, with mean plus 2SD being less than 15 AAD. To ensure highly specific mutation detection, a cutoff value of 20 AAD is used for dichotomy between reproducible and non-reproducible variants.

LYS-P-14

## The immune landscape of Burkitt lymphoma: dysfunctional T-cells phenotype and M2-macrophages polarization

Giuseppe Lo Bello<sup>1</sup>, Ayse Akarca<sup>2</sup>, Maria Raffaella Ambrosio<sup>\*1</sup>, Lucia Mundo<sup>1</sup>, Massimo Granai<sup>1</sup>, Noel Onyango<sup>3</sup>, Isaac Ndede<sup>4</sup>, Elena Sabbatini<sup>5</sup>, Michele Bibas<sup>6</sup>, Stefano Lazzi<sup>7</sup>, Lorenzo Leoncini<sup>7</sup>, Teresa Marafioti<sup>2</sup>

<sup>1</sup>Medical Biotechnologies, University of Siena, Siena, Italy, <sup>2</sup>Department of Histopathology, University College London, London, United Kingdom, <sup>3</sup>Department of Clinical Medicine and Therapeutics, University of Nairobi, Nairobi, <sup>4</sup>Department of Immunology, Moi University School of Medicine, Eldoret, Kenya, <sup>5</sup>Department of Haematology and Clinical Oncology, Haematopathology University Hospital Bologna, Bologna, <sup>6</sup>National Infectious Diseases Lazzaro Spallanzani, Lazzaro Spallanzani, Roma, <sup>7</sup>Medical Biotechnology, University of Siena, Siena, Italy

**Background:** Tumor microenvironment (TME) is heterogeneous and consists of several cells that include cytotoxic T lymphocytes, natural killer cells, dendritic cells, myeloid-derived suppressor cells, and tumor associated macrophages (TAMs). There is a limited number of studies characterizing the tumor microenvironment in Burkitt lymphoma. We studied the immune landscape of eBL, sBL and HIV-associated BL.

**Principals/Methodology:** The TME of BL was investigated in 14 eBL, 5 sBL, and 5 HIV+ type by multiplex immunohistochemistry applying the following panels: CD4/CD8/Foxp3, CD8/Granzyme B/PD1, CD8/CD56/Granulysin and CD163/c-MAF/ PD-L1.

**Results:** The amount of infiltrating CD4+ T-cells was low and it accounted for approximately 13% in eBL, 6% in sBL and 13% in HIV+ BL. Reduced Tregs (CD4+/Foxp3+) infiltrate was observed (6% in eBL, 3% in sBL and 5% in HIV+BL) and a significant increase in CD8+ T-cells was found in all the examined samples (22% in eBL, 16% in sBL and 20% in HIV+ BL). Furthermore, the great majority of the CD8+ cells co-expressed PD1 (10% in eBL, 3% in sBL and 13% in HIV+ BL). Double positive CD56 and granulysin (NK cells) were

significantly reduced in all BL cases. Analysis of triple staining for CD163/c-MAF and PD-L1 revealed that the great majority of TAMs in BL have a M2 phenotype, being also CD163 and c-MAF positive (10% in eBL, 8% in sBL and 15% in HIV+ BL).

**Conclusion:** High PD1 expression is associated with T-cell exhaustion. One of the major findings in our investigation was that the CD8+/PD1+ T-cells subset was particularly increased in eBL and HIV+BL compared to sBL. Our results suggest that exhausted T- cells exist in BL regardless the EBV status and, point out PD1 pathway as the underlying event responsible for tumor evasion in BL. This scenario is probably influenced by the immunosuppressive nature of the macrophages that we found in BL to have an M2 phenotype. Future studies are in progress to investigate the functional interplay between PD-L1+ macrophages and CD8+/PD1+ T- cells. The aim is to provide the rationale for target immune suppressive TAMs (M2 TAMs) as a part of immunotherapies for cancers.

LYS-P-15

## RNA-SEQ studies in primary intestinal T-cell lymphomas

Rebeca Manso<sup>1</sup>, Marta Rodriguez-Moreno<sup>1</sup>, Maria Rodriguez-Remirez<sup>2</sup>, Javier Menarguez<sup>3</sup>, Cristina Chamizo<sup>1</sup>, Raul Cordoba<sup>4</sup>, Federico Rojo<sup>1</sup>, Miguel Angel Piris Pinilla<sup>1</sup>, Socorro Maria Rodriguez-Pinilla<sup>1\*</sup>

<sup>1</sup>Pathology, <sup>2</sup>Oncology, FJD, <sup>3</sup>Pathology, Hospital Gregorio Marañón, <sup>4</sup>Haematology, FJD, Madrid, Spain

**Background:** Over the years gene expression array studies have put some light in the knowledge of the molecular background of many different subgroup of lymphomas. T-cell lymphomas are an aggressive subgroup of these tumors without specific therapeutic regimens. Enteropathy-associated t-cell lymphoma (EATL) has been recently subdivided in two different groups: Type I EATL or simply EATL and type II EATL now designated as monomorphic epitheliotropic intestinal T-cell lymphoma (MEITL). Although Type I EATL is related to coeliac disease and considered a disease of individuals of northern European origin and MEITL shows no association with coeliac disease and its incidence is increased in Asian and Hispanic population; both share immunophenotype and a really poor prognosis. The median overall survival for patients with any of these diseases does not exceed 7 months. Since their molecular background it is still poorly understood we took advantage of SEQUENCING techniques to study a series of 15 cases, in an attempt to find prognosis or therapeutic targets.

**Principals/Methodology:** RNA from a series of 4 EATL and 11 MEITL cases was extracted of FFPE samples. The library was prepared with Illumina's TruSight RNA Pan-Cancer Panel. The sequencing was performed on Miseq Reagent Kit V3 (paired-end, 2x76) on a MiSeq instrument (Illumina). Statistical studies using GSEA, POMELO or BABELMICS tools were performed.

**Results:** GSEA enrichment analysis, which uses t statistics, showed that there were 5 gene sets significantly enriched at FDR <25% when we compared EATL against MEITL cases. Those pathways were CD-40 signaling, NFKB alternative, TNFR2 and CD8 T-cell differentiation pathways. Furthermore, t-test studies using pomelo identified 33 genes statistically deregulated between both subgroup of tumors; being the top 10 differentiated genes BTG2, NAB2, HIPK2, PLAU, MEF2B, IKKBE, ID3, NFKB2, EPHB1 and PVT1. Differences between any of these subgroups of tumors and normal tissue are being evaluated.

**Conclusion:** We identified different molecular alterations leading to deregulation of different signaling pathways with potential prognosis or therapeutic roles which need further validation in these especially aggressive subgroup of T-cell lymphomas.

## Epstein Barr virus positive mucocutaneous ulcer and classical Hodgkin Lymphoma share similar immune microenvironmental features.

Matthew R. Pugh<sup>1</sup>, Ayse Akarca<sup>2</sup>, Louise King<sup>3</sup>, Teresa Marafioti<sup>2</sup>, Stefan Dojcinov<sup>1</sup>

<sup>1</sup>Department of Cellular Pathology, All Wales Lymphoma Panel, University Hospital of Wales, Cardiff,

<sup>2</sup>Department of Pathology, University College London, London, <sup>3</sup>Cellular Pathology, University Hospital of Wales, Cardiff, United Kingdom

**Background:** Classical Hodgkin lymphoma (cHL) and EBV+ mucocutaneous ulcer (EBVMCU) exhibit a morphological overlap but a marked difference in biological behaviour and outcomes. The importance of the inflammatory microenvironment and role of immunomodulatory molecules in pathogenesis of cHL has provided foundation for novel treatments but has not been studied in EBVMCU. In this study we characterised and compared the immune microenvironment in cHL and EBVMCU.

**Principals/Methodology:** Tissue microarrays were constructed using 4mm cores of cHL and EBVMCU cases from FFPE tissue blocks. Multiplex immunohistochemistry of the following panels was performed: CD4, CD8, FoxP3; CD25, FoxP3, CD8, Granzyme; PD1, PDL1, PAX5, CD163; PDL1, cMAF, CD163; PDL1, cMYC, PAX5; CD80, CTLA4, FoxP3; CD80, CD11c, PAX5, CD4; Ox40, CD4, FoxP3. In situ hybridisation for EBER was performed. Three TIFF images of a x200 magnification field were taken for each panel. Qualitative, semi quantitative and automated quantitative image analyses were performed with the aid of the "Image-J" software.

**Results:** Twenty two cases of cHL (14 EBV+; 8 EBV-) and 11 of EBVMCU were analysed. EBVMCU and cHL showed overlapping microarchitectural features, with compartmentalisation of the small B-cell, T-cell and histiocytic populations. Lesional Hodgkin and Reed-Sternberg (HRS) and HRS-like cells co-localised with the tumour infiltrating macrophages (TIM), and both the lesional cells and macrophages showed variable expression of immunoregulatory markers. PDL1 was expressed in 17/22 (77%) cases of cHL, and 11/11 (100%) cases of EBVMCU. Both entities were devoid of PD1+ T-cells in the vicinity of the lesional blasts. CD80 was expressed on HRS cells and TIM in 19/22 (86%) cases of cHL, and 11/11 (100%) cases of EBVMCU. CTLA-4+ T-regulatory lymphocytes (FoxP3+) were present in the vicinity of the CD80+ cells. cHL EBV status was not associated with PDL1 or CD80 expression. There was marked variation in the ratio of T-regulatory lymphocytes and cytotoxic T-cells within both entities.

**Conclusion:** EBVMCU and cHL, regardless of EBV status, show similar subpopulations of lymphoid cells and macrophages with similar "inflammatory microarchitecture", indicating other factors account for the biological differences. The expression of immunoregulatory markers did not discriminate between EBVMCU and cHL. Both entities show expression patterns in keeping with immune regulation via PDL1-PD1 and a pattern suggesting CD80-CTLA4 engagement between TIM, HRS cells and T-regulatory cells.

LYS-P-17

## Combined effects of MYC and EBV on lipid metabolism in aggressive B-cell lymphomas

Maria R. Ambrosio<sup>1</sup>, Mohsen Navari<sup>2</sup>, Stefano Lazzi<sup>1</sup>, Lucia Mundo<sup>1</sup>, Giuseppe Lo Bello<sup>1</sup>, Virginia Mancini<sup>1</sup>, Cristiano Peron<sup>3</sup>, Thomas Menter<sup>4</sup>, Alexander Tzankov<sup>4</sup>, Stephen Dirnhofer<sup>4</sup>, Lorenzo Leoncini<sup>1</sup>, Pier P. Piccaluga<sup>3</sup>

<sup>1</sup>University of Siena, Siena, Italy, <sup>2</sup>Torbat Heydariyeh University of Medical Sciences, Torbat Heydariyeh, Iran, Islamic Republic Of, <sup>3</sup>Bologna University School of Medicine, Bologna, Italy, <sup>4</sup>University of Basel, Basel, Switzerland

**Background:** MYC protein and Epstein-Barr virus (EBV), both involved in the pathogenesis of BL and other human lymphomas, are well known activators of cell metabolism. Bearing this in mind, we aimed to unveil whether lipid metabolism activation is related to either MYC or EBV or both in aggressive human B-cell lymphomas, with special focus on BL and diffuse large B-cell lymphoma (DLBCL).

**Principals/Methodology:** We analyzed 286 B-non Hodgkin lymphoma, 17 Hodgkin lymphoma (HL) cases and 25 samples representative of normal B-cell subsets for the expression of MYC, HIF1A, FASN, PLIN2 and PPARG, obtained from Affymetrix microarrays. In addition, 270 lymphoma cases (including BL, DLBCL, and PMBCL) were studied by immunohistochemistry (IHC) for validation. In situ hybridization was used for EBV detection.

**Results:** First, we found that HIF1A, FASN, PLIN2 and PPARG genes were variably expressed across the B-NHL panel. Particularly, BL and DLBCL presented a consistent over-expression of FASN, PLIN2 and PPARG compared to their normal counterparts or to other lymphoma subtypes. Interestingly, we found a significant correlation between the expression of FASN and PLIN2 on the one hand, and MYC on the other hand ( $p < 0.0001$  and  $p = 0.0004$ , respectively) confirming the initial hypothesis. To better explore the role of EBV, we then focused on DLBCL occurring after transplantation (PTLD-DLBCL). We found that both PLIN2 ( $p < 0.0001$ ) and PPARG (0.0004) were over-expressed in EBV+ cases, their expression not being significantly related to that of MYC in this specific setting. Similarly, in EBV+ vs. EBV- BL, PLIN2 was significantly over-expressed in presence of the virus. Overall, this indicated that not only MYC expression but also EBV infection significantly affected lipid metabolism activation in aggressive B-NHL. To further expand and validate this observation, we used IHC and found that EBV+/MYC- as well as MYC+ cases (independently of EBV) did consistently express FASN/PLIN2/PPARG, although with some degree of variability according to the lymphoma subtype. By contrast, EBV-/MYC- consistently did not express such molecules ( $\chi^2$ ,  $p < 0.0001$ ).

**Conclusion:** We provide evidence of combined/overlapping effects of EBV and MYC on lipid metabolism in lymphoma cells, shedding new light on the complex interaction between oncogenes and oncoviruses.

## Prognostic impact of MYC, BCL2 and/or BCL6 rearrangements status in large B cell lymphoma

Jiyeon Hyeon<sup>\*1</sup>, Hye Won Hwang<sup>2</sup>, Dohee Kwon<sup>2</sup>, Seung-Myoung Son<sup>3</sup>, Inju Cho<sup>4</sup>, Ji Yun Jeong<sup>5</sup>, Seok-Jin Kim<sup>6</sup>, Won Seog Kim<sup>6</sup>, Young-Hyeh Ko<sup>2</sup>

<sup>1</sup>Department of Pathology, Incheon St Mary's hospital, College of Medicine, The Catholic University of Korea, Incheon, <sup>2</sup>Department of Pathology and Translational Genomics, Samsung Medical Center, Sungkyunkwan University School of Medicine, Seoul, <sup>3</sup>Departments of Pathology, Chungbuk National University Hospital, Cheongju, <sup>4</sup>Department of Hospital Pathology, Yeouido St. Mary's Hospital, The Catholic University of Korea, Seoul, <sup>5</sup>Department of Pathology, Kyungpook National University Chilgok Hospital, Kyungpook National University, Daegu, <sup>6</sup>Division of hematology-oncology, Department of Internal medicine, Samsung Medical Center, Sungkyunkwan University School of Medicine, Seoul, Korea, Republic Of

**Background:** MYC rearrangement can be detected in a proportion of aggressive B cell lymphoma. In the 2017 WHO Classification, MYC rearranged tumors accompanied by BCL2 and/or BCL6 rearrangement are named high-grade B-cell lymphoma (HGBCL) with MYC and BCL2 and/or BCL6 rearrangement irrespective of their morphology.

**Principals/Methodology:** To investigate the prognostic impact of MYC rearranged large cell lymphoma, we retrospectively performed the fluorescence in situ hybridization (FISH) using break apart probe for MYC gene in 471 cases of high grade B cell lymphoma including Burkitt lymphoma, diffuse large B cell lymphoma, and grey zone lymphoma. For those of MYC-positive cases, FISH for BCL2 and BCL6 was performed to detect HGBCL with MYC with BCL2 and/or BCL6 rearrangement. Immunohistochemistry for CD10, BCL6, MUM-1, C-MYC, and BCL2 was carried out to determine the cell of origin classification by Hans' algorithm and find double expressor.

**Results:** Based on the FISH study for MYC, BCL2 and BCL6, 103 cases were classified into 31 Burkitt lymphomas, 31 diffuse large B cell lymphomas, 23 HGBCL with double hit translocation (DHL), 3 HGBCL with triple hit translocation (THL), and 15 HGBCL, NOS.

Patients with DHL/THL showed significantly early death compared with patients without DH/TH (2-year overall survival (OS) rate, 38% vs 82%;  $P < 0.05$ ). MYC rearrangement status, ECOG performance status  $> 1$  and International Prognostic Index  $> 2$  were associated with worse OS ( $P < 0.05$ ) and MYC rearrangement status, elevated serum lactate dehydrogenase level and ECOG performance status  $> 1$  were associated with worse progression free survival (PFS) ( $P < 0.05$ ). Cell of origin (COO) classification according to the Hans' algorithm has no differences in the survival in multivariable analyses in PFS (hazard ratio [HR] of ABC-like disease vs. GCB-like disease, 0.544; 95% CI, 0.75 to 1.690;  $P = 0.292$ ) and OS (HR, 1.468; 95% CI, 0.592 to 3.639;  $P = 0.407$ ). Double expressor (DE) status has no significant differences in PFS (HR of DE vs. no DE, 2.402; 95% CI, 0.947 to 6.093;  $P = 0.065$ ) and OS (HR, 1.007; 95% CI, 0.508 to 1.993;  $P = 0.985$ ) by univariable and multivariable analysis.

**Conclusion:** Our results suggest that double hit/triple hit lymphomas are clinically aggressive from the point of being associated with early death, irrespective of their morphological feature, COO classification group or DE status. HGBCL exhibits histologic finding of wide spectrum, routine FISH testing using three FISH markers is essential to identify HGBCL.

LYS-P-19

## Targeted deep sequencing of gastric marginal zone lymphoma identified alterations of TRAF3 and TNFAIP3 that were mutually exclusive for MALT1 rearrangement

Jiyeon Hyeon<sup>\*1</sup>, Boram Lee<sup>2</sup>, So-Hyun Shin<sup>3</sup>, Hae Yong Yoo<sup>4</sup>, Seok Jin Kim<sup>5</sup>, Won Seog Kim<sup>5</sup>, Young-Hyeh Ko<sup>3</sup>, Woong-Yang Park<sup>2</sup>

<sup>1</sup>Department of Pathology, Incheon St Mary's hospital, College of Medicine, The Catholic University of Korea, Incheon, <sup>2</sup>Samsung Genome Institute, Research Institute for Future Medicine, Samsung Medical Center, <sup>3</sup>Department of Pathology and Translational Genomics, Samsung Medical Center, Sungkyunkwan University School of Medicine, <sup>4</sup>Department of Health Sciences and Technology, Samsung Advanced Institute for Health Sciences and Technology, Sungkyunkwan University, <sup>5</sup>Division of hematology-oncology, Department of Internal medicine, Samsung Medical Center, Sungkyunkwan University School of Medicine, Seoul, Korea, Republic Of

**Background:** Gastric extranodal marginal zone lymphoma of mucosa-associated lymphoid tissue is a distinct entity in that *Helicobacter pylori* infection plays the most important causative role in the development of the disease.

**Principals/Methodology:** To investigate the genomic alteration in gastric marginal zone lymphoma that was resistant to the *H. pylori* eradication therapy, we analyzed 19 cases of the gastric marginal zone lymphoma using fluorescence in situ hybridization for MALT1, BCL10 rearrangement and targeted sequencing using an Illumina platform.

**Results:** Major genetic alterations affected genes involved in nuclear factor (NF)-κB pathway activation and included MALT1 rearrangement (39%), and somatic mutations of TRAF3 (21%), TNFAIP3 (16%), and NOTCH1 (16%). In the MALT1 rearrangement-negative group, disruptive somatic mutations of TRAF3 were the most common alterations (4/12, 33%), followed by somatic mutations of TNFAIP3 (3/12, 25%), and NOTCH1 (3/12, 25%).

**Conclusion:** The present study confirms that genes involved in activation of NF-κB signaling pathways are a major driver in oncogenesis of *H. pylori* eradication-resistant gastric marginal zone lymphoma and revealed that TRAF3 mutation is a major contributor in MALT1 rearrangement-negative gastric marginal zone lymphoma.



LYS-P-20

## DNA methylation analysis on paraffin embedded tissue as a new tool for the differential diagnosis between T-Lymphoblastic Lymphoma (T-LBL) and lymphocyte-rich thymoma

Aurore Touzart<sup>1,2</sup>, Mohamed Belhocine<sup>3</sup>, Salvatore Spicuglia<sup>3</sup>, Vincent Thomas de Montpreville<sup>4</sup>, Lara Chalabreysse<sup>5</sup>, Alexander Marx<sup>6</sup>, Nicolas Girard<sup>7</sup>, Laure Gibault<sup>8</sup>, Benjamin Besse<sup>9</sup>, Elizabeth Macintyre<sup>1,2</sup>, Vahid Asnafi<sup>1,2</sup>, Thierry Jo Molina<sup>10</sup>

<sup>1</sup>Laboratory of Onco-Haematology, Hôpital Necker Enfants-Malades, <sup>2</sup>Institut Necker-Enfants Malades (INEM), Paris, <sup>3</sup>TAGC, Marseille, <sup>4</sup>Department of Pathology, Institut d'oncologie thoracique, Hôpital Marie-Lannelongue, Le Plessis-Robinson, <sup>5</sup>Department of Pathology, Hôpital Louis-Pradel, Hospices Civils de Lyon, Lyon, France, <sup>6</sup>Institute of Pathology, Mannheim Medical University, Heidelberg University, Mannheim, Germany, <sup>7</sup>Université de Lyon, Hospices Civils de Lyon, Lyon, <sup>8</sup>department of pathology, hopital HEGP, Paris, <sup>9</sup>Department of Cancer Medicine, institut Gustave Roussy, Villejuif, <sup>10</sup>department of pathology, hopital Necker-Enfants Malades, Paris, France

**Background:** T-LBL and thymomas are rare primary mediastinal tumors derived either from T-cell precursors or from thymic epithelial cells, respectively. Some thymoma subtypes display predominant reactive TdT+ T-lymphocytes, masking epithelial tumor cells and complicating differential diagnosis from T-LBL, especially with needle biopsies. As prognosis and treatment differ dramatically, initial correct diagnosis is essential.

**Principals/Methodology:** We initially analyzed the global DNA methylation of 17 T-LBL compared to 1 lymphocyte-rich thymoma and 3 normal thymus by MeDIP (Methylation DNA ImmunoPrecipitation)-array and defined a methylation ratio based on the most differentially methylated genes discriminating T-LBL and thymoma/normal thymus. We then established a MS-MLPA (Methylation sensitive Multiplex Ligation-dependent Probe Amplification) assay to determine this ratio on a validation series of 40 T-LBL and 29 lymphocyte-rich thymomas (AB, B1 and B2 subtypes).

**Results:** Unsupervised hierarchical clustering of global DNA methylation analyzed by MeDIP-array identified two main subsets within a single T-LBL (n=17) cluster and the thymoma and normal thymus in a second cluster. Using SAM (Significance Analysis of Microarray) analysis we defined a methylation signature, which was strongly enriched in hypermethylated gene promoters in the T-LBL cluster. We then defined a methylation ratio based on the methylation average of 6 of the most differentially methylated gene promoters (ZIC1, TSHZ2, CDC42BPB, RBM24, C10orf53, and MACROD2). MS-MLPA analysis, performed using DNA from a validation series of 40 T-LBL cases and 29 FFPE T-cell rich thymomas, showed significantly different methylation between T-LBL and thymomas (methylation median 0.67 and 0.03 respectively,  $p < 0.0001$ ) which were close to normal thymus (0.015). A methylation ratio of 0.1 reliably discriminated T-LBL and thymoma.

**Conclusion:** DNA methylation analysis is a powerful biomarker for the differential diagnostic between T-LBL and TdT + T-cell rich thymoma. MS-MLPA is compatible with routine activity, require only 50 ng DNA from FFPE or fresh samples and no specific DNA treatment. T-LBL demonstrated aberrant DNA hypermethylation within gene promoters, reflecting malignancy. Conversely, the lymphoid population from lymphocyte rich thymoma showed a methylation profile close to normal thymic tissues confirming their reactive nature.

LYS-P-21

## Clinico-pathological and molecular heterogeneity of breast-implant lymphomas

Léna Mescam<sup>\*1</sup>, José Adelaide<sup>2</sup>, Anne Murati<sup>1</sup>, Marie Bannier<sup>3</sup>, Séverine Garnier<sup>2</sup>, Arnaud Guille<sup>2</sup>, Jean Marc Schiano<sup>4</sup>, Max Chaffanet<sup>2</sup>, Daniel Birnbaum<sup>2</sup>, Luc Xerri<sup>1</sup>

<sup>1</sup>Biopathology, <sup>2</sup>Molecular oncology, <sup>3</sup>Surgery, <sup>4</sup>Hematology, Institut Paoli Calmettes, Marseille, France

**Background:** Breast implant-associated anaplastic large cell lymphoma (BI-ALCL) is the most common type of breast-implant lymphomas (BIL). Little is known about the pathogenesis of this rare disease, since only few cases have been investigated through molecular assays. It is also unclear whether BIL could include other lymphoma subtypes. Although BI-ALCL cases confined to the capsule seem to have excellent outcome, the clinical management of other cases remains challenging due to the lack of prognostic markers.

**Principals/Methodology:** We report the clinico-pathological features of a series of 10 BIL, including 6 cases analyzed through array CGH (aCGH) and targeted NGS (tNGS).

**Results:** In 7/10 cases, the tissue infiltration was superficial /in situ, whereas 3 cases invaded the capsule. Two cases with in situ spread had axillary lymph node invasion. 9/10 cases fulfilled the BI-ALCL criteria, characterized by anaplastic cytology, variable and mostly deficient expression of T-cell markers, CD30 expression, negativity of ALK and EBV, and monoclonal TCR rearrangement. In contrast, 1/10 case was CD30- and EBV+ and exhibited a complex phenotypic and genotypic profile with negativity of CD30 and most B and T cell markers, except CD79a, together with both TCR and IGH monoclonal rearrangements and IGH-MYC translocation. DUSP 22 rearrangement was absent in all cases.

aCGH showed deletions involving fragile sites like the 3p12 region including FHIT in 2 cases and the 20p12 region in 1 case. Deletion of the 13q14 region including the RB1 gene was observed in 2 cases.

tNGS detected activating STAT3 mutations in 2 cases including a D661Y variant in 1 BI-ALCL case and a G618R variant in the non-anaplastic EBV+ case. The 7 patients with in situ extension had no chemotherapy and are in complete remission after watch and wait follow-up. One patient with capsule invasion died from lymphoma dissemination despite intensive chemotherapy. This patient displayed the highest number of aCGH abnormalities, together with a TP53 mutation.

**Conclusion:** Our series not only confirms that BI-ALCL is the most usual BIL type, but also suggests that non-anaplastic EBV+ large B-cell lymphomas could also rarely occur in this context. Our results further support a role of STAT3 mutations in BIL pathogenesis, whatever the BIL subtype. In addition our results suggest that high numbers of chromosomal abnormalities and TP53 mutation could be associated with aggressive clinical behaviour of BI-ALCL.



LYS-P-22

## Integrated analysis of signal transducers and activators of transcription 3 (STAT3) associated factors in diffuse large B-cell lymphoma

Kazuho Morichika<sup>\*1</sup>, Kennosuke Karube<sup>2</sup>, Risa Watanabe<sup>3</sup>, Mamoru Kawaki<sup>3</sup>, Sakiko Kitamura<sup>1</sup>, Sachie Uchibori<sup>1</sup>, Shohei Tomori<sup>1</sup>, Taeko Hanashiro<sup>1</sup>, Natsuki Shimabukuro<sup>1</sup>, Iori Tedokon<sup>1</sup>, Keita Tamaki<sup>1</sup>, Yukiko Nishi<sup>1</sup>, Sawako Nakachi<sup>1</sup>, Satoko Morishima<sup>1</sup>, Junnosuke Uchihara<sup>4</sup>, Takeaki Tomoyose<sup>5</sup>, Kazuiku Ohshiro<sup>5</sup>, Iwao Nakazato<sup>6</sup>, Atsushi Yamanoha<sup>7</sup>, Takashi Miyagi<sup>7</sup>, Tetsuro Nakazato<sup>8</sup>, Masaki Hayashi<sup>9</sup>, Taishi Takahara<sup>10</sup>, Akira Satou<sup>10</sup>, Satoko Shimada<sup>11</sup>, Kazuyuki Shimada<sup>12</sup>, Toyonori Tsuzuki<sup>10</sup>, Shigeo Nakamura<sup>11</sup>, Takuya Fukushima<sup>13</sup>, Hiroaki Masuzaki<sup>1</sup>

<sup>1</sup>Division of Endocrinology, Diabetes and Metabolism, Haematology, Rheumatology (Second Department of Internal Medicine), <sup>2</sup>Department of Cell Biology and Pathology, Graduate School of Medicine, University of the Ryukyus, <sup>3</sup>Medical Student, Faculty of Medicine, University of the Ryukyus, <sup>4</sup>Department of Haematology, Naha-City Hospital, <sup>5</sup>Department of Haematology, <sup>6</sup>Department of Pathology, Okinawa Prefectural Nanbu Medical Center and Children's Medical Center, <sup>7</sup>Department of Haematology, Heartlife Hospital, <sup>8</sup>Department of Haematology, Okinawa Red Cross Hospital, <sup>9</sup>Department of Haematology, Nakagami Hospital, Okinawa, <sup>10</sup>Department of Surgical Pathology, Aichi Medical University Hospital, <sup>11</sup>Department of Pathology and Clinical Laboratories, <sup>12</sup>Department of Haematology and Oncology, Nagoya University Graduate School of Medicine, Aichi, <sup>13</sup>Laboratory of Haematology, School of Health Sciences, Faculty of Medicine, University of the Ryukyus, Okinawa, Japan

**Background:** Diffuse large B-cell lymphoma (DLBCL) is the most frequent malignant lymphoma and heterogeneous in genetic and clinical viewpoint. Janus-associated kinase-signal transducer and activator of transcription (JAK-STAT) pathway is activated by various cytokines and plays pivotal roles in various biological phenomena in both physiological and neoplastic conditions. Especially, STAT3 associated genes are often mutated in DLBCL and its roles as prognostic markers and therapeutic targets have been discussed although detailed molecular background remains to be clarified. This tempted us to perform integrated analysis of STAT3 associated genetic aberrations in DLBCL.

**Principals/Methodology:** Immunohistochemistry and mutation analysis using targeted sequencing focusing STAT3 associated genes were performed with formalin-fixed and paraffin embedded samples from 279 patients newly diagnosed as DLBCL. Cut-off line of the phosphorylated STAT3 (pSTAT3) positivity, a surrogate marker of STAT3 activation, was set at 40% of lymphoma cells according to previous studies. Cell of origin (COO) was determined with Hans algorithm. Sensitivity to JAK inhibitor was analyzed using DLBCL cell lines and STAT3 protein activation status was analyzed by immunoblotting.

**Results:** pSTAT3 was detected 122 cases (44%) and biased toward in non-GCB type ( $P < 0.001$ ). MYD88 L265P and EBV positivity were significantly associated with non-GCB type and pSTAT3 expression ( $P < 0.001$ ) (Figure 1). STAT3 and non-L265P MYD88 mutations were relatively enriched in GCB type but only the former was significantly associated with pSTAT3 expression ( $P=0.02$ ). Interestingly, pSTAT3 was less frequently expressed in SOCS1 mutated cases ( $P=0.08$ ). DLBCL cell lines with STAT3 mutation (Pfeiffer) or MYD88L265P mutation (HBL-1) showed pSTAT3 expression and were sensitive against JAK inhibitor. On the other hand, SOCS1 mutated one (SUDHL-8) did not show pSTAT3 expression and was resistant against JAK inhibitor. Clinically, pSTAT3 expression and COO was not associated with overall survival among patients treated with immunochemotherapy. EBV positivity and STAT3 mutations were correlated with poorer and better prognosis, respectively.

**Conclusion:** Our data clarified clinicopathological diversity of STAT3 activation in DLBCL. These results and in vitro experiments suggest we should prudently apply clinical sequence to precision medicine until enough clinicopathological and functional evidence are established.

## Image:

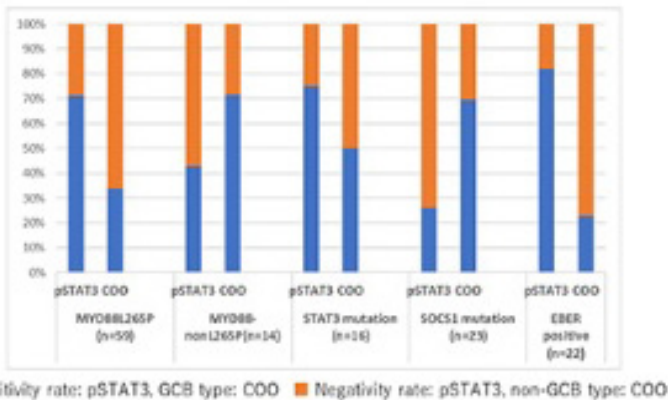


Figure 1. pSTAT3 positivity rate and COO in the cases with each STAT3 associated factor

LYS-P-23

## Activated signal transducers and activators of transcription (STAT3) in adult T cell leukemia/lymphoma and its association with disease subtypes and clinical findings

Kazuho Morichika<sup>1</sup>, Kennosuke Karube<sup>2</sup>, Hirona Kayo<sup>3</sup>, Shuta Uchino<sup>3</sup>, Satoko Morishima<sup>1</sup>, Sawako Nakachi<sup>1</sup>, Kazuiku Ohshiro<sup>4</sup>, Iwao Nakazato<sup>5</sup>, Takuya Fukushima<sup>6</sup>, Hiroaki Masuzaki<sup>1</sup>

<sup>1</sup>Division of Endocrinology, Diabetes and Metabolism, Haematology, Rheumatology (Second Department of Internal Medicine), <sup>2</sup>Department of Cell Biology and Pathology, Graduate School of Medicine, University of the Ryukyus, <sup>3</sup>Medical Student, Faculty of Medicine, University of the Ryukyus, <sup>4</sup>Department of Haematology, Okinawa Prefectural Nanbu Medical Center and Children's Medical Center, <sup>5</sup>Department of Pathology, Okinawa Prefectural Nambu Medical Center and Children's Medical Center, <sup>6</sup>Laboratory of Haematoimmunology, School of Health Sciences, Faculty of Medicine, University of the Ryukyus, Okinawa, Japan

**Background:** Adult T-cell leukemia-lymphoma (ATLL) is a mature T-cell neoplasm associated with human T-cell leukemia virus type I infection and is subdivided into two indolent (smoldering and chronic) and two aggressive (acute and lymphoma) clinical subtypes.

Janus-associated kinase-signal transducer and activator of transcription (JAK-STAT) pathway is activated by various cytokines and plays pivotal roles in various biological phenomena in both physiological and neoplastic conditions. Recent studies described that several genes associated with JAK-STAT pathway are mutated in ATLL, suggesting its important role in oncogenic process of ATLL. However, the detailed activation status of this pathway in ATLL tissue samples and its clinicopathological significances have not yet been well analyzed.

**Principals/Methodology:** Formalin-fixed and paraffin embedded samples of 117 ATLL cases composed of 25 acute, 45 lymphoma, 3 chronic, 38 smoldering subtypes (6 not identified) were used for the analysis. Nuclear localization of phosphorylated STAT3 (pSTAT3), pSTAT5 and pSTAT6 proteins, whose activation



has been frequently reported in haematologic malignancies, was analyzed by immunohistochemistry. Somatic mutation status of STAT3 was also analyzed. Immunoblotting was used to quantify the expression levels of STAT3 in ATLL cell lines.

**Results:** Nuclear expression of pSTAT3 was observed in 50 out of 117 cases (43%), whereas pSTAT5 and pSTAT6 were negative in almost all cases. More than half of cases with acute and indolent subtype showed pSTAT3 nuclear expression (Table 1). On the other hand, only 8 out of 45 cases (18%) of lymphoma subtype cases showed this finding, significantly less frequently positive than other subtypes ( $P < 0.001$ ). Interestingly, pSTAT3 was identified in five out of six cases of lymphoma subtype transformed from indolent ones. Clinically, pSTAT3 positive cases had better overall survival and progression free survival than negative cases in indolent subtype ( $P < 0.05$ ) (Figure 1). Known somatic STAT3 mutations were found in 22% (20/92) of analyzed cases. These mutated cases tended to show nuclear pSTAT3 expression ( $P = 0.08$ ). pSTAT3 expression levels in ATLL cell lines also varied.

Table 1: Comparison pSTAT3 immunohistochemical analysis with subtypes of ATLL.

**Conclusion:** Our data indicated the clinicopathological importance of the STAT3 activation in ATLL. The role of STAT3 activation might differ between acute/indolent and lymphoma type.

**References:** Kataoka K, et al. Blood 2018 11; 131(2): 215-225.

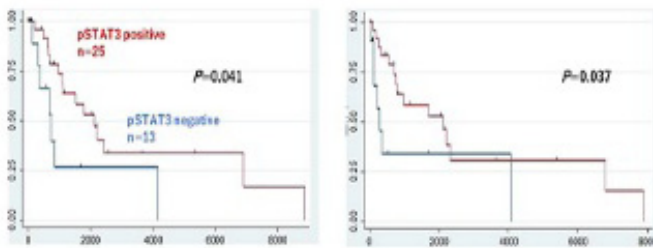


Figure 1. Overall survival (a) and progression free survival (b) of indolent cases with pSTAT3 positive and pSTAT3 negative

LYS-P-24

## Engineered bioluminescent 3D lymphoma avatars for targeted therapy

Maura Rossi<sup>1</sup>, Elisa Michelini<sup>2</sup>, Barbara Roda<sup>2,3</sup>, Francesco Alviano<sup>1</sup>, Martina Rossi<sup>1</sup>, Maria Maddalena Calabretta<sup>2</sup>, Silvia Zia<sup>3</sup>, Ilaria Vigliotta<sup>3</sup>, Simona Righi<sup>1</sup>, Salvatore Collura<sup>1</sup>, Francesca Scellato<sup>1</sup>, Maria Antonella Laginestra<sup>4</sup>, Maria Rosaria Sapienza<sup>1</sup>, Laura Bonsi<sup>1</sup>, Aldo Roda<sup>2</sup>, Claudio Agostinelli<sup>1</sup>, Elena Sabattini<sup>4</sup>

<sup>1</sup>Department of Experimental, Diagnostic and Specialty Medicine, <sup>2</sup>Department of Chemistry "Giacomo Ciamician", University of Bologna, <sup>3</sup>Stem Sel srl, Bologna, <sup>4</sup>Unit of Haematopathology, Sant'Orsola Hospital, Bologna, Italy

**Background:** Patient-derived 3D cell models and organoids are more representative in vivo physiology and reproduce the endogenous microenvironment. Currently, there are no predictive and standardized 3D model of lymphomas in vitro to study microenvironment, immune-escape phenomenon and for drug testing. Selection of targeted therapy for lymphoma still remains an unmet need for precision methods

to directly monitor lymphoma dynamics at the molecular level. The main objective of this project was to create 3D organoid ex vivo personalized lymphoma-models as a new tool for precision medicine.

**Principals/Methodology:** Diffuse Large B cell Lymphoma (DLBCL) cell lines (SU-DHL4/SU-DHL6) were cultured in micropatterned 96-well plates optimizing the protocols with different seeding cell densities and incubation time. Fresh lymph node biopsies from patients with different lymphoma types were disaggregated and plated with the same conditions of cell lines.

**Results:** Spheroids of 200 micron diameter were obtained in 24/48 hours from DLBCL cell lines with a uniform nearly spherical shape. Spheroids were transiently transfected with bioluminescent reporter genes and in vivo non-destructive imaging was accomplished to monitor cell viability and inflammatory pathways. To identify subsets of neoplastic and reactive cells, we used a new technology, Celecator<sup>®</sup>, able to separate and collect cells based on their intrinsic morphological/dimensional properties without the need of immunotags. Starting from a mixture of DLBCLs cell line and from peripheral blood mononuclear cells from healthy subjects, tumoral and normal cell profiles significantly differed, as confirmed by flow-cytometry, corroborating future applications on 3D patient-derived models. Fresh lymph node biopsies were disaggregated and cell suspensions were plated in low-attachment micro-plates to form 3D organotypic models. First results showed formation of nearly 200 micron sized 3D spheroids in about 24 hours. Cell suspensions obtained from lymph node were also injected into Celecator<sup>®</sup> and different cell subsets were successfully separated.

**Conclusion:** These results are promising and need optimization and protocol standardization. Validation on formalin-fixed paraffin-embedded spheroid is ongoing.

LYS-P-25

## Transformation of follicular lymphoma to Epstein Barr virus positive diffuse large b-cell lymphoma: a case report and review of the literature

Massimo Granai<sup>1</sup>, Lucia Mundo<sup>1</sup>, Ayse Akarca<sup>2</sup>, Giuseppe Lo Bello<sup>1</sup>, Virginia Mancini<sup>1</sup>, Federica Vergoni<sup>3</sup>, Raffaella Santi<sup>4</sup>, Gioia Di Stefano<sup>3</sup>, Teresa Marafioti<sup>2</sup>, Lorenzo Leoncini<sup>1,1</sup>, Maria R. Ambrosio<sup>1</sup>, Stefano Lazzi<sup>1</sup>

<sup>1</sup>University of Siena, Siena, Italy, <sup>2</sup>University College London, London, United Kingdom, <sup>3</sup>University of Florence, Florence, <sup>4</sup>University of Florence, Siena, Italy

**Background:** Epstein-Barr virus (EBV) is a member of the gammaherpesvirus family implicated in the pathogenesis of several human tumours, including carcinomas and lymphomas, particularly those derived from B-cells. In the vast majority of cases, EBV-associated B-cell lymphoproliferations arise on a background of congenital or acquired immune suppression. They range from benign lesions (i.e., EBV-positive mucocutaneous ulcer) to polymorphic B-cell proliferations to overt cases of B-cell lymphoma, peripheral T-cell/natural killer-cell lymphoma, and Hodgkin lymphoma. Although the link between EBV and EBV-LPD is strong enough to suggest a functional implication for EBV, its oncogenic role is still controversial.

**Principals/Methodology:** In December 2011, a 77-year woman presented for the swelling of a laterocervical lymph node. Histological examination revealed a grade 2 FL, stage IVA and the patient underwent R-FND and rituximab treatment. In March 2016, the patient relapsed and was treated according to the Renoir protocol. In November 2017, the patient was hospitalized for recurrent fever and a new biopsy was performed with a diagnosis of EBV-positive DLBCL. Since EBV reactivation has been observed following chemotherapy, it was hypothesized that EBV had been the trigger of the transformation of FL, determin-



ing the multiple relapses of the disease. Accordingly we checked EBV by EBER in all the samples, then we studied the latency of the virus by RT-PCR and immunohistochemistry, and the immunologic background of the different lymphomas as well as their clonal origin.

**Results:** EBV was demonstrated also in FL samples increasing from the first (10%) to the second (30%) biopsy. In all the biopsies the virus elicited a latency I associated to the activation of an abortive lytic cycle in the DLBCL sample. Interestingly, in FL samples there was a significant number of CD-4 and PD-1 lymphocytes within the follicles; in DLBCL the reactive T-cells were mainly CD8 and FOXP3 lymphocytes. IGHV rearrangement confirmed the clonal origin of FL and DLBCL.

**Conclusion:** This paper supports the view that the reactivation of lytic cycle may play an active role in EBV-driven lymphomagenesis by increasing the total number of latently infected cells, promoting the tumor growth and inducing a microenvironment permissive for the neoplastic transformation.

LYS-P-26

## Comprehensive analysis of Follicular Lymphoma evolution based on immunoglobulin variable region gene sequences reveal acquisition of N-glycosylation motifs is an early and stable event in pathology

Mariette Odabashian<sup>1</sup>, Emanuela Carlotti<sup>2</sup>, Shamzah Araf<sup>1</sup>, Jessica Okosun<sup>1</sup>, Francesco Forconi<sup>3</sup>, Freda Stevenson<sup>3</sup>, Sergey Krysov<sup>1</sup>, Mariarita Calaminici<sup>1</sup>, John Gribben<sup>1</sup>

<sup>1</sup>Centre for Haemato-Oncology, <sup>2</sup>Centre for Tumour Biology, Barts Cancer Institute, London, <sup>3</sup>Cancer Sciences Division, University of Southampton, Southampton, United Kingdom

**Background:** Longitudinal mutational studies on Follicular Lymphoma (FL) have revealed an evolutionary pathway reliant on an ancestral B cell pool, known as the common progenitor cell (CPC). Studies infer this cell population is responsible for giving rise to progression events. The CPC can have a 'rich' or 'sparse' mutational profile dependent on genetic relatedness between diseases events. FL cells acquire N-glycosylation (N-gly) motifs during somatic hypermutation within their immunoglobulin variable region which carry unusual high mannoses that interact with lectins found within the microenvironment, leading to activation of pro-survival signalling pathways.

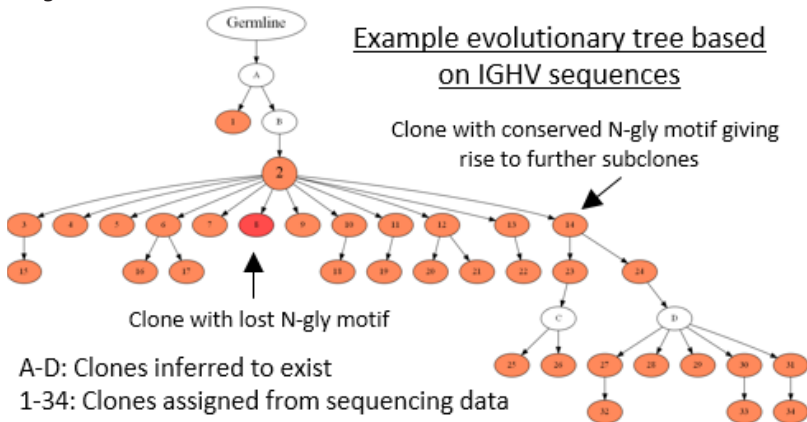
**Principals/Methodology:** We aimed to understand the behaviour of N-gly motifs during lymphoma progression and evolution. Genomic DNA from five FL patients taken at different time points of disease including diagnosis, relapse and transformation, underwent sequencing of the immunoglobulin heavy chain gene (IGHV) using the Illumina miseq platform. Patients 1&3 presented a 'sparse' profile, patient 2 a 'rich' profile and patients 4&5 were uncategorised. Tumour related reads were assigned as unique clones and analysed for N-gly motifs. Evolutionary trees were generated based on IGHV sequence homology between clones.

**Results:** All patients acquired  $\geq 1$  N-gly motif site within the IGHV that was conserved in  $>97\%$  of unique subclones. Conservation was maintained across disease events regardless of high or low genetic semblance to a preceding or subsequent episode. Patient 5 samples were taken from different anatomical locations with the two tumour populations displaying distinct N-gly motifs. However, a subgroup of motif positive clones were shared between populations. Evolutionary tree analysis revealed no additional motifs were gained as motif positive clones expand while rare negative subclones do not undergo further diversification and are presumably lost from the tumour population.

**Conclusion:** N-gly motifs are an early event in FL pathology and provide an advantage to tumour cells as seen through their conservation in and across disease episodes. This is despite an increase in the genomic complexity of the disease with additional driver mutations being acquired as the disease progresses. The

sharing of subclones between the distinct spatial samples infers an ability of motif positive cells to survive and traffic between anatomical sites. Targeting motifs and their interacting partners may offer patients effective therapeutic value and improve prognosis.

**Image:**



LYS-P-27

## Clinicopathologic Features of Lymphoma in Spinal Epidural Space

Kai Zhang<sup>\*1</sup>

<sup>1</sup>Medical Laboratory, Geisinger Health System, Danville, United States

**Background:** Both primary spinal epidural lymphoma and lymphoma involving spinal epidural space are uncommon. We retrospectively analyzed clinicopathologic features and outcome of eleven cases.

**Principals/Methodology:** Eleven cases of biopsy proven of spinal epidural lymphoma retrieved from 1 July 2015 to current at our institution. All the cases were diagnosed and sub-classified based on 2016 WHO classification Clinicopathologic features and outcome of the cases were reviewed.

**Results:** Eleven patients included 7 men and 4 women with age ranges of 15 to 80 years (mean 54). Most of the patients presented with weakness of upper and lower limbs, back or neck pain and bladder or bowel dysfunction. 2 out of 11 patients were HIV-positive. The lymphoma involved thoracic and lumbar paraspine in 9 of 11 cases (82%) and involved parasacral areas (2 out of 11 cases). 6 out 11 cases had CSF analysis that was negative for lymphoma. All of eleven lymphoma cases were those of B cell lymphoma with 1 Burkitt lymphoma, 1 double hit lymphoma, 1 high grade B cell lymphoma (NOS) and 8 diffuse large B cell lymphoma (NOS). 3 out of 8 DLBCL were germinal center (GC) -like subtype and 5 out of 8 were non-GC-like subtype. 10 out 11 cases had FISH study for cMYC, BCL2 and BCL6. 4 out 10 (40%) cases harbored rearranged c-MYC gene, and 6 out of 10 (60%) had BCL6 gene abnormalities (rearrangement, gains or deletion). 1 out of 10 cases had IgH-BCL2 fusion (double hit lymphoma). Only 1 case was positive for Epstein Barr virus by EBER1 staining. All patients were treated with chemotherapy and/or localized radiation therapy. 4 out 10 (40%) patients died within 6 months after initial diagnosis. 6 out of 10 (60%) were alive with 6 months to 24 months short follow-up, and one patient lost follow-up.



- Conclusion:** 1. Lymphoma involving epidural spinal region are uncommon, and usually seen in adults although broad age ranges are observed. It is that of mainly intermediate or high grade B cell lymphoma. A high proportion (40% of cases) of c-MYC rearranged cases is observed, and non-GC-like DLBCL cases seems a bit more common than GC-like subtype of DLBCL in our small series.
2. A significant subset of the patients have very poor prognosis with death within 6 months.

LYS-P-28

## MYC gene alterations and not BRAF and MAPK mutations are common features in dendritic cell neoplasms

Gerard Frigola<sup>1</sup>, Iban Aldecoa<sup>1</sup>, Natalia Papaleo<sup>2</sup>, Elías Campo<sup>1</sup>, Lluís Colomo<sup>2</sup>, Olga Balagué<sup>1</sup>

<sup>1</sup>Pathology Department, Hospital Clínic, <sup>2</sup>Pathology Department, Hospital del Mar, Barcelona, Spain

**Background:** Histiocytic and dendritic cell neoplasms (HDCT) include a group of heterogeneous and very uncommon diseases with limited data on genetic and molecular alterations. BRAF<sup>V600E</sup> and MAP2K1 (exons 2 and 3) mutations have been identified in up to 85% of cases of Langerhans cell histiocytosis but only in up to 19% of follicular dendritic cell sarcomas (FDCS), and cyclin D1 overexpression has been postulated as a surrogate marker for MAPK pathway activation. Moreover, in B-cell lymphomagenesis, a synergic role for MYC and the Ras-Raf-MAPK cascade has been earlier described, but the contribution of MYC in dendritic cell sarcomas oncogenesis has not been thoroughly evaluated. We aimed to study the presence of such alterations in a series of dendritic cell tumors.

**Principals/Methodology:** We reviewed 8 cases of FDCS, 1 case of interdigitating dendritic cell sarcoma (IDCS), 4 cases of FDCS-inflammatory pseudotumor variant (FDCS-IPT) and 7 cases of inflammatory pseudotumor (IPT) collected during the period 2000-2017. Immunophenotypic characterization included dendritic cell markers, cyclin D1 and MYC. In situ hybridization of EBV mRNA (EBER) was performed, and BRAF<sup>V600E</sup> and MAP2K1 (exons 2 and 3) mutational status was assessed by Sanger sequencing. MYC gene alterations were studied by FISH using break apart probes.

**Results:** Only 1/19 cases (a case of FDCS-IPT) harbored the BRAF<sup>V600E</sup> mutation and 0/17 cases exhibited mutations in exons 2 and 3 of the MAP2K1 gene. Cyclin D1 nuclear expression was positive in 6/8 FDCS (75%), 1/1 IDCS (100%), 2/4 FDCS-IPT (50%) and 2/6 IPT (33%). MYC expression was observed in 3/7 FDCS (43%), 1/1 IDCS (100%), 0/4 FDCS-IPT (0%) and 0/6 IPT (0%). FISH studies revealed MYC amplifications (defined as  $\geq 4$  copies/nucleus) in 2/6 FDCS (33%), and copy number gains (defined as  $\geq 3$  copies/nucleus) in 3/6 FDCS (50%) and 1/1 IDCS (100%). No MYC gene alterations were observed in 1/6 FDCS (17%), and in the 3 FDCS-IPT and 6 IPT assessed. The FDCS cases showing MYC overexpression correlated with MYC gene amplifications cases except one case in which no material was available for FISH.

**Conclusion:** MYC gene numerical alterations occur in FDCS and IDCS, and high level of MYC protein expression may identify cases with MYC amplification. On the other hand BRAF<sup>V600E</sup> mutation and MAP2K1 gene mutations are uncommon alterations in dendritic cell tumors, and may not be involved in the up-regulation of cyclin D1 observed in these tumors.

LYS-P-29

## Double hit lymphoma identification and characterization in routine practice

Olga Balagué<sup>\*1</sup>, Marta Marginet<sup>1</sup>, Anna Carrió<sup>2</sup>, Dolors Costa<sup>2</sup>, Blanca González<sup>1</sup>, Alfredo Rivas<sup>3</sup>, Cristina Teixidó<sup>1</sup>, Adriana Sierra<sup>1</sup>, Antonio Martínez<sup>1</sup>, Elías Campo<sup>1</sup>

<sup>1</sup>Pathology, <sup>2</sup>Cytogenetics, <sup>3</sup>Hematology, Hospital Clinic. University of Barcelona, Barcelona, Spain

**Background:** High-grade B-cell lymphomas (HGBL) with MYC and BCL2 and/or BCL6 rearrangement are a new category in the updated 2016 WHO classification of lymphoid neoplasms. They are called double/triple-hit lymphomas and their morphology may be diffuse large B-cell lymphoma (DLBCL), blastoid, or Burkitt-like lymphoma (BL). Identification of these cases is now mandatory, since these patients may be eligible for more aggressive therapeutic regimes. Fluorescence in situ hybridization (FISH) is the most widely used technique to identify structural genomic alterations in routine processed cases. However, there is still room for improvement in terms of hands-on time, turnaround time and interpretation

**Principals/Methodology:** We evaluated all DLBCL and HGBL routinely diagnosed at our institution, using two different break-apart FISH probes for MYC, BCL2 and BCL6 (our standard Metasystems and IQFISH Agilent). We compared the number of assessable cases, alterations and turnaround time (days from the H&E evaluation to the moment when FISH is available for interpretation with IQFISH or the date of the final report for the standard probe). All cases were classified as GCB or non-GCB according to the Hans algorithm

**Results:** Since 2016 we obtained results with both FISH protocols in 100 cases: 79 routine and 21 retrospective cases. The rate of non-assessable cases was 5% for BCL2, 5% for MYC and 7% for BCL6 with IQFISH vs 10%, 6% and 8% respectively with the standard probes. IQFISH identified 27/95(28%) cases with MYC aberrations: 7/95(7%) with gains and 20/95(21%) with rearrangements; including 6(6%) double-hit (4 cases had BCL2 and 2 had BCL6 rearrangements). With the Metasystems probes we identified 31/94(33%) cases with MYC aberrations: 10/94(11%) with gains, 21/94(22%) with rearrangements and 7/94(7%) double-hit cases. Correlation in double-hit lymphoma identification was 85%, the discordant case was not assessable with IQFISH. All double-hit cases were GCB. In routine cases the average turnaround time with IQFISH is 1.8 days vs 7.5 days with the standard probe

**Conclusion:** Our series reproduce the results previously published in terms of the frequency of MYC alterations and “double hit” cases. The rate of non-assessable cases is lower for all three probes with IQFISH compared to Metasystems. Turnaround time is shorter with IQFISH due to the lower rate of repetitions, a brighter signal and less background. IQFISH is a feasible, robust and reliable method for a (hemato) pathology department to identify “double hit” lymphomas.



LYS-P-30

## Clinicopathologic characteristics and novel biomarkers of aggressive B-cell lymphomas in the nasopharynx

Po-Han Chen<sup>\*1</sup>, Yuhang Yang<sup>2</sup>, Dennis P. O'Malley<sup>2</sup>, Mina Xu<sup>1</sup>

<sup>1</sup>Pathology, Yale-New Haven Hospital, New Haven, <sup>2</sup>Neogenomics, Aliso Viejo, United States

**Background:** Although nasal-type NK/T cell lymphomas are highly distinctive, the most common nasopharyngeal lymphomas in the United States are B-cell non-Hodgkin lymphomas (B-NHL), accounting for 75% of all cases (SEER database 2017<sup>1</sup>). Relatively little is known about the clinicopathologic features of these cases. In this study, we characterize a multi-institutional cohort of aggressive B-NHL primary to the nasopharyngeal area. We compare and contrast cases which are EBV positive versus EBV negative. In addition, we evaluate the expression of SSTR2 and PD-L1, potential markers for targeted therapeutics.

**Principals/Methodology:** We retrieved 53 cases of aggressive B-NHL (48 diffuse large B-cell lymphomas, 2 Burkitt lymphomas, 2 high-grade B-cell lymphomas and 1 plasmablastic lymphoma) from the two institutions. Cases in which systemic lymphoma was found prior to or concurrently were excluded. All diagnosis were made according to contemporary WHO criteria using appropriate ancillary studies. In all cases available, staining was performed for in situ EBV (EBER), SSTR2a and PD-L1.

**Results:** Twelve out of all 50 cases tested (24%) were positive for EBV by in situ hybridization. No significant difference was found between EBV+ and EBV- cases in terms of age at diagnosis, proliferation index or cell of origin classification by Hans criteria. Average expression of CMYC by immunohistochemistry was higher for EBV- cases than EBV+ cases (45% vs 15%) whereas CD30 expression was more often seen in EBV+ cases than in EBV- cases (3/5 vs 1/17). Six of 15 cases tested (40%) were positive for SSTR2. Seven of 14 cases tested (50%) demonstrated expression of PD-L1 within tumor cells with an average H-score of 56. The two EBV+ DLBCL tested demonstrated substantial PD-L1 reactivity.

**Conclusion:** This initial clinicopathologic study of aggressive B-NHLs of the nasopharynx reveals some differences between EBV positive versus EBV negative cases. The association of EBV+ cases with expression of CD30 and PD-L1 is particularly informative in terms of potential targeted therapies. This data is in line with previous studies of PD-L1 expression in virus-associated B-cell malignancies. In addition, a significant number of these cases expressed SSTR2, which could render them susceptible to somatostatin analogue therapy and peptide receptor radionuclide therapy.

**Reference:** Han AY Epidemiology of nasopharyngeal lymphoma in the United States: a population-based analysis of 1119 cases. *Otolaryngology—Head and Neck Surgery* 2017; 156(5): 870-876.

LYS-P-31

## Burkitt-like lymphoma with 11q aberration is not uncommon in children

Shunyou Gong<sup>\*1</sup>, Melissa Stalling<sup>2</sup>, Aroop Kar<sup>2</sup>, Madina Sukhanova<sup>3</sup>, Girish Venkataraman<sup>3</sup>, Katrin Leuer<sup>2</sup>, Lawrence Jennings<sup>2</sup>, Kristian Schafernak<sup>4</sup>, Nobuko Hijiya<sup>2</sup>

<sup>1</sup>Pathology, <sup>2</sup>Northwestern University, <sup>3</sup>University of Chicago, Chicago, <sup>4</sup>Phoenix Children's Hospital, Phoenix, United States

**Background:** Burkitt-like lymphoma with 11q aberration is a new provisional entity included in the 2016 revision of the World Health Organization (WHO) classification, with pathologic features closely resembling those of Burkitt lymphoma (BL) but lacking MYC rearrangements. Instead, this entity shows recur-

rent chromosome 11q alterations. Although its clinical course has been reported to be similar to that of BL, there have only been limited cases reported.

**Principals/Methodology:** We collected pathologic and clinical data from the medical record on all pediatric high grade B-cell lymphoma (HGBL) cases diagnosed in the past 10 years at our institution (2007-2017). Eight cases that did not meet criteria for either BL or diffuse large B-cell lymphoma (DLBCL) underwent FISH for MYC, BCL-2, and BCL-6, as well as array comparative genomic hybridization (CGH).

**Results:** A total of 51 cases of HGBL were identified. These included 23 cases of classical Burkitt lymphoma (BL) as defined by classic morphology and MYC rearrangement, 20 cases of diffuse large B-cell lymphoma (DLBCL), and 8 other cases. Chromosome 11q aberrations were identified in 5 out of the 8 non-DLBCL, non-BL HGBL cases. The other 3 cases were classified as HGBL, not otherwise specified (NOS.) We did not identify any cases of HGBL with MYC and BCL-2 and/or BCL-6 rearrangements.

Morphologically, all 5 cases of Burkitt-like lymphoma with 11q aberration showed typical pathological features as described in 2016 WHO. All 5 of these cases occurred in the head/neck region. Four of these cases were localized (stage II), with the remaining case also involving a few metabolically active but non-enlarged lymph nodes in the chest and abdomen (stage III). All 5 patients achieved complete remission with standard therapy for mature B-cell lymphoma. All patients were alive with no clinical evidence of disease at a median follow-up time of 34 months (range 12-95 months).

**Conclusion:** Although the number is small, our results suggest that the majority of pediatric non-Burkitt, non-DLBCL cases of HGBL carry 11q aberrations. In addition, patients with 11q aberrations appear to be more likely to present with lower stage disease, thus requiring less intensive therapy, and also tend to have primary disease in the head/neck. These findings further support the classification of Burkitt-like lymphoma with 11q aberration as a distinct pathologic and clinical entity.

LYS-P-32

## Impact of Sox11 overexpression in Ba/F3 cells

Birgitta Sander<sup>1</sup>, Martin Lord<sup>1</sup>, Gustav Arvidsson<sup>1</sup>, Agata M. Wasik<sup>1</sup>, Birger Christensson<sup>1</sup>, Anthony P. Wright<sup>1</sup>, Alf Grandien<sup>2</sup>

<sup>1</sup>Laboratory Medicine, <sup>2</sup>Medicine, Karolinska Institutet, Stockholm, Sweden

**Background:** SOX11 is epigenetically silenced in mature B-lymphocytes (1) but expressed in the vast majority of MCL (2). In MCL the functional role and prognostic impact of SOX11 is controversial with conflicting results on whether SOX11 serves as an oncogene or a tumor suppressor (3-6). We directly address this question by introducing Sox11 in the non-malignant, pro-B cell line Ba/F3, a cell-line previously used for evaluation of transformation capability of genes such as BCR-ABL (7).

**Principals/Methodology:** Sox11 was introduced in the pro-B cell line Ba/F3. Cell proliferation by trypan blue exclusion, XTT-analysis and 3HThymidine incorporation. Live cell microscopy. Global gene expression analysis by Affymetrix MTA-1 mouse array.

**Results:** Sox11 induced cell aggregation and suppressed DNA synthesis and cell proliferation. GEP showed up-regulation of many genes associated with the cell cycle progression and increased proliferation that might contribute to oncogenic transformation of the cells. However, the Ba/F3 cells appear to mount a DNA damage response with the consequent activation of several checkpoints, consistent with the observed reduction in cell proliferation.

**Conclusion:** Data indicate that Sox11 expressed under the immunoglobulin Emu promoter increases B-cell receptor signaling and promotes oncogenic transformation of murine B-cells (8). An important difference between the study by Kuo et al. (8) and our study is that immunoglobulin genes are not expressed



in the Ba/F3 cells (9) and thus Ba/F3 cells lack capacity to signal through the B-cell receptor. Still, Sox11 had profound effects on cell growth and significantly altered the global gene expression pattern. The net results of induced Sox11 expression in Ba/F3 cells was reduced proliferation and a marked cell aggregation. However, this does not exclude that SOX11 exhibits oncogenic activity in other cell contexts where crucial cell cycle checkpoint genes are absent, or perhaps by cooperating with oncogenes, tumor suppressor genes or ongoing BCR-signaling mechanisms that are deregulated in lymphoma.

#### References:

1. Wasik AM, et al. *Sci Rep.* 2013;3(1400).
2. Ek S, et al. *Blood* 2008; 111(2) 800-805
3. Palomero J, et al. *Leukemia.* 2016; 30(7):1596-1599.
4. Vegliante MC, et al. *Blood.* 2013; 121(12):2175-2185.
5. Conrotto P, et al. *Mol Oncol.* 2011; 5(6):527-537.
6. Kuo PY, et al. *Oncogene.* 2015;34(10):1231-1240.
7. Daley GQ, Baltimore D. *PNAS* 1988;85(23):9312-9316.
8. Kuo PY, et al. *Blood.* 2018
9. Sigvardsson M, et al. *Immunity.* 1997;7(1):25-36.

LYS-P-33

## Expression of P63 and absence of GATA3 are useful surrogate markers to differentiate primary mediastinal large B-cell lymphoma from classic Hodgkin lymphoma

Hyun-Jung Kim<sup>1</sup>, Geongsin Park<sup>2</sup>, Jae Ho Han<sup>3</sup>, Hee Kyung Kim<sup>4</sup>, Hee Jung Cha<sup>5</sup>, Dae Woon Eom<sup>6</sup>, Uiju Cho<sup>7</sup>, Suk Jin Choi<sup>8</sup>, Soo Kee Min<sup>9</sup>, Ji Eun Kim<sup>\* 10</sup>

<sup>1</sup>Pathology, Inje University Sanggye Paik Hospital, <sup>2</sup>Pathology, Seoul St. Mary's Hospital, The Catholic Univ, Seoul, <sup>3</sup>Pathology, Ajou Univ, Suwon, <sup>4</sup>Pathology, Soonchunhyang University Bucheon Hospital, Bucheon, <sup>5</sup>Pathology, Ulsan University Hospital, Ulsan, <sup>6</sup>Pathology, Gangneung Asan Hospital, Gangneung, <sup>7</sup>Pathology, St. Vincent Hospital, Suwon, <sup>8</sup>Pathology, Inha University Hospital, Incheon, <sup>9</sup>Pathology, Hallym University Sacred Heart Hospital, Anyang, <sup>10</sup>Pathology, Seoul National University Boramae Hospital, Seoul, Korea, Republic Of

**Background:** Despite recent advances of genetic testing and development of diagnostic markers, lymphoid lesions of the mediastinum still remains challenging. Particularly, distinction between three lymphomas of thymic B-cell origin such as primary mediastinal large B-cell Lymphoma (PMLBCL), nodular sclerosis Hodgkin lymphoma (NSHL) and gray-zone lymphoma requires careful consideration. In this study, we aimed to find more practical surrogate pathologic markers to better differentiate mediastinal B-cell lymphomas.

**Principals/Methodology:** A total of 32 cases of mediastinal B-cell lymphomas consisting of PMLBCL (N=16), NSHL (N=13), and gray zone lymphoma (N=3) were collected from 6 university hospitals from Korea. Clinicopathologic features were reviewed in the companion meeting. Protein expression of P63, GATA3 and cyclinE was investigated by immunohistochemistry.

**Results:** PMLBCL showed more frequent disease progression and mortality than NSHL (p<0.05), but other clinical features were similar. In pathologic review, fine reticulated fibrosis rapping individual cells was the most characteristic finding unique for PMLBCL (p<0.001), whereas collection of epithelioid histiocytes favored NSHL (p=0.078). Expression of P63 was quite exclusively found in PMLBCL (15/16) than NSHL

(2/11) with the most exquisite diagnostic value measured by De Long test ( $p < 0.001$ ). GATA3 was more frequently expressed in the NSHL (9/12) with heterogeneous intensity in contrast to PMLBCL (negative in all 16) ( $p < 0.001$ ). Expression of cyclinE was rarely found in a minor population of PMLBCL.

**Conclusion:** Expression of P63 and reticular fibrosis pattern are the most robust feature to distinguish PMLBCL from NSHL in the mediastinal lesions. Additionally, GATA3 expression favored NSHL.

**References:**

1. Gualco G, Natkunam Y, Bacchi CE. The spectrum of B-cell lymphoma, unclassifiable, with features intermediate between diffuse large B-cell lymphoma and classical Hodgkin lymphoma: a description of 10 cases *Modern Pathology* (2012) 25, 661–674
2. Elsayed AA, Satou A, Eladl AA, Kato S, Nakamura S, Asano N. Grey zone lymphoma with features intermediate between diffuse large B-cell lymphoma and classical Hodgkin lymphoma: a clinicopathological study of 14 Epstein–Barr virus-positive cases. *Histopathology* 2017, 70, 579–594

LYS-P-34

## Contribution of immunoglobulin lambda light chain gene rearrangement analysis in the diagnosis of lymphoproliferative disorders

Anna Paterson<sup>1</sup>, Hesham Eldaly<sup>2,3</sup>, Livia Raso-Barnett<sup>2</sup>, Ming-Qing Du<sup>4</sup>, Olivier Giger<sup>4</sup>, Elizabeth Soilleux<sup>4</sup>, Thomas Robert<sup>2</sup>, Yuanxue Huang<sup>2</sup>, Hani Bibawi<sup>2</sup>, Baljinder Matharu<sup>2</sup>, Anthony Bench<sup>2</sup>, Mike Scott<sup>2</sup>, Hongxiang Liu<sup>2</sup>

<sup>1</sup>Department of Histopathology, <sup>2</sup>Haematopathology and Oncology Diagnostics Service, Cambridge University Hospitals NHS Foundation Trust, Cambridge, United Kingdom, <sup>3</sup>Clinical Pathology Department, Cairo University, Cairo, Egypt, <sup>4</sup>Department of Pathology, University of Cambridge, Cambridge, United Kingdom

**Background:** Identification of clonal immunoglobulin (IG) gene rearrangements, usually undertaken using BIOMED-2 PCR assays for the IGH, IGK and IGL loci, offers a valuable diagnostic adjunct in cases of possible B cell lymphoproliferative disorders (B-LPDs). However, many centres omit IGL analysis as its additional value is uncertain. This study explored the contribution of IGL analysis in B-LPD diagnosis.

**Principals/Methodology:** From October 2016 to March 2018 all cases submitted for B-cell clonality analysis as part of their diagnostic assessment were tested for IGH, IGK and IGL rearrangements using BIOMED2 PCR assays. The results of each case as a whole and also each reaction tube (four for IGH, two for IGK and one for IGL) were interpreted using EuroClonality/BIOMED-2 guidelines, and the contribution of each reaction determined.

**Results:** IG rearrangement analysis was undertaken on 567 cases and was successful in 527 (93%) cases. In 307 cases (54%) a clonal rearrangement was identified in at least one reaction. Table 1 shows the proportion of clonal cases with a clonal rearrangement detected in individual reactions and combined reactions. A clonal IGL rearrangement was identified in 74 (24%) clonal cases. In a single case a clonal rearrangement was only identified in the IGL reaction. Review of this case confirmed the diagnosis to be follicular lymphoma. In the remaining cases a clonal IGL rearrangement was detected in addition to clonal IGH and/or IGK rearrangements (Table 2).



Reaction Tube(s)	Proportion of cases (n=307)
IGL	74 (24%)
All IGH	284 (93%)
All IGK	253 (82%)
All IGH & IGK	306 (99.7%)
All IGH & IGL	289 (94%)
All IGK & IGL	255 (83%)
All IGH & IGK & IGL	307 (100%)

Table 1: Proportion of clonal cases where a clonal reaction was detected in individual and combinations of reaction tubes.

Clonal reactions	Number of cases (n=74)
IGL only	1 (1.4%)
IGL + one other	2 (2.7%)
IGL + two others	4 (5.4%)
IGL + three others	5 (6.8%)
IGL + four others	18 (24%)
IGL + five others	20 (27%)
IGL + six others	24 (32%)

Table 2: The number of reaction tubes with a clonal result when the IGL reaction was clonal.

**Conclusion:** This study shows the value of IGL analysis in the diagnosis of B-LPDs. Given the importance of demonstrating a clonal IG rearrangement in the differentiation between benign and malignant processes, IGL analysis should be included in a standard IG clonality analysis protocol, especially in suspected B-LPDs where a clonal IGH and/or IGK rearrangement is not detected or the result is equivocal.

LYS-P-35

## Tumor Microenvironment in Anaplastic Large Cell Lymphoma: The role of CD8+, FOXP3 regulatory T cells, CD8/FOXP3 ratio and PD-L1 expression

Cristiane Rubia Ferreira<sup>\*1,2</sup>, Shuchun Zhao<sup>1</sup>, Charles Dana Bangs<sup>1</sup>, Raymundo Soares Azevedo<sup>2</sup>, Denis Ricardo Miyashiro<sup>4</sup>, José Antonio Sanches Junior<sup>4</sup>, Luis A. P. C. Lage<sup>3</sup>, Juliana Pereira<sup>3</sup>, Maria Claudia N. Zerbini<sup>2</sup>, Yasodha Natkunam<sup>1</sup>, Dita Gratzinger<sup>1</sup>

<sup>1</sup>Department of Pathology, Stanford University School of Medicine, Stanford, United States <sup>2</sup>Departments of Pathology, <sup>3</sup>Hematology, <sup>4</sup>Dermatology, University of Sao Paulo, Sao Paulo, Brazil

**Background:** Immune responses in tumor microenvironment (TME) between systemic anaplastic large cell lymphoma (sALCL) and primary cutaneous CD30+ lymphoproliferative disorders (pcLPD) may have differences.

**Methodology:** Retrospective study. Immunohistochemistry: ALK, CD20, CD3, CD30, CD8, FOXP3, PD-L1 and EBV ISH (EBER). PD-L1 expression in tumor cells (TCs) and tissue associated macrophages (TAM) was scored as negative, <5%; weak, ≥5% to <30% positivity or weak intensity; strong, ≥30% with moderate to strong intensity. CD8+ cytotoxic tumor infiltrating lymphocytes (TIL) and FOXP3+ regulatory T-cells (Treg) densities were evaluated in 2 non-overlapping high-power fields. The CD8+/FOXP3+ ratio was defined as the mean number of CD8+TIL divided by the mean number of FOXP3+Treg. Breakapart FISH for IRF4/DUSP22 (6p25.3) was performed. Statistical analysis: Kruskal-Wallis, Mann-Whitney, Wilcoxon signed-rank and Fisher's Exact tests. P < .05 was considered statistically significant.

**Results:** Our cohort had 82 sALCL, 43 (52.4%) ALK- ALCL [5 (11.6%) were ALK- ALCL DUSP22-rearranged], 39 (47.5%) ALK+ ALCL; and 21 pcLPD, 8 (38.1%) lymphomatoid papulomatosis (7 type A, 1 type C), 9 (42.8%) pcALCL and 4 (19%) borderline lesions. PD-L1+ in TCs of ALK+ ALCL was higher than ALK- ALCL (p=0.0001) and pcLPD (p=0.001639). None of the ALK- ALCL/DUSP22-rearranged cases expressed PD-L1 in TCs (p=0.0001754), but uniformly expressed it in TAM (p=0.01113). PD-L1+ in TAM was higher in ALK- ALCL than in ALK+ ALCL (p<0.0001) and higher in pcLPD than in sALCL (p=0.02503). By paired test, the correlation of PD-L1+ between TCs and TAM was negative in ALK- ALCL (p=0.0107) and positive in ALK+ ALCL (p=0.0025). There was no difference in the FOXP3+Treg density between ALK- ALCL vs ALK+ ALCL (p=0.131) or sALCL DUSP22-rearranged vs DUSP22- cases (p=0.622), but a lower CD8/FOXP3 ratio in ALK- ALCL than ALK+ ALCL (p=0.026) was observed. There was higher FOXP3+Treg density in pcLPD than in sALCL group (p=0.015), with lower CD8/FOXP3 ratio by pcLPD group (p=0.009). There was no difference in CD8+TIL density between ALK- ALCL vs ALK+ ALCL (p=0.366), pcLPD vs sALCL (p=0.737), or sALCL DUSP22-rearranged vs DUSP22- (p= 0.0974).

**Conclusion:** ALK- ALCL/DUSP22-rearranged group did express PD-L1 only in TAM; ALK+ ALCL had higher PD-L1+ in TCs than ALK- ALCL and pcLPD; ALK- ALCL had negative correlation between PD-L1+ in TCs and TAM, ALK+ ALCL had positive correlation; pcLPD had higher FOXP3+Treg density.



LYS-P-36

## The spectrum of findings in patients presenting with extranodal marginal zone B cell lymphoid proliferations of mucosa associated lymphoid tissue (MALT) in the recto-colonic mucosa

Lori Soma<sup>\*1</sup>, Stephen Smith<sup>2</sup>, Prathima Reddy<sup>2</sup>, Sindhu Cherian<sup>1</sup>, David Wu<sup>1</sup>, Kerstin Edlefsen<sup>1</sup>, Xueyan Chen<sup>1</sup>, Yi Zhou<sup>1</sup>, Jonathan Fromm<sup>1</sup>

<sup>1</sup>Department of Laboratory Medicine, <sup>2</sup>Department of Hematology-Oncology, University of Washington, Seattle, United States

**Background:** Colonic MALT lymphomas are uncommon and perhaps a controversial entity. We evaluated the clinicopathologic features of 12 patients presenting with atypical recto-colonic B cell proliferations considered to be lymphoproliferative disorders (LPD) or lymphomas of MALT type.

**Principals/Methodology:** Clinical and radiographic records were reviewed. Histologic material was reexamined in conjunction with laboratory data. Clonality and fluorescence in situ hybridization studies were performed (BIRC3/MALT1, IGH/BCL2, IGH/MALT1).

**Results:** Morphologic and immunophenotypic features were similar to MALT lymphomas at other sites, with the exception of lymphoepithelial lesions (LELs; 1 of 12). Of 9 patients tested, 3 demonstrated a B cell clone by flow cytometry, 4 by IGH PCR and 2 by both methods. Three of 10 patients showed BIRC3/MALT1 fusion, 0 of 9 showed IGH/BCL2 and 0 of 8 showed IGH/MALT1. The two patients with BIRC3/MALT1 showed identical B cell clones in subsequent gastric biopsies.

Patient age range was 20-74 years. Two clinical groups were identified: one with symptomatology (6) and one incidental identified upon screening (6). The symptomatic group typically showed hematochezia, and endoscopically demonstrated either a mass or polyps/mucosal change. The incidental group typically demonstrated polyps.

Follow-up data was available in 11 patients, 9 showed localized disease. Therapy included antibiotics (2), chemotherapy (3), rituximab (4) local resection (1), local radiation (1) or no further intervention (5). Follow-up ranged from 2-79 months; 9 with no evidence of disease, 1 with partial response, and 1 with continued gastric involvement. The 5 patients without intervention (all with polyps; 2 with hematochezia) showed no evidence of disease progression (follow-up is limited; 2-40 months).

**Conclusion:** Colonic MALT LPD shows similar morphologic and immunophenotypic features to MALT lymphomas at other sites, with the exception of LELs. Although none showed IGH/MALT1, two showed IGH/BIRC3 (and clonally related B cells in the stomach), raising the question of multi-focal MALT lymphomas in some instances. Based on this small series, we conclude that patients presenting with MALT LPDs as a colonic polyp (incidental or hematochezia) and clinically localized disease, might be better served with conservative management, though longer follow-up, and data based on consistent staging and surveillance methods (potentially including gastric evaluation), are needed to inform management.

LYS-P-37

## Mycosis Fungoides in Taiwan shows a relatively high frequency of large cell transformation and CD56 expression

Ren Ching Wang<sup>1</sup>, Shih-Sung Chuang<sup>2</sup><sup>1</sup>Pathology and Laboratory Medicine, Taichung Veteran General Hospital, Taichung, Taiwan, Taichung city,<sup>2</sup>Pathology, Chi-Mei Medical Center, Tainan, Taiwan

**Background:** Mycosis fungoides (MF) is an indolent cutaneous T-cell lymphoma. MF may transform into large cell lymphoma in the disease course. The incidence of MF in Taiwan is lower as compared to that in the West. We aimed to characterize the clinicopathological, immunohistochemical, and genetic features of transformed MF (t-MF) in Taiwan.

**Principals/Methodology:** We retrospectively collected MF cases from April 2004 to April 2015 from four medical centers in Taiwan, reviewed the clinical history and histopathology, and performed immunohistochemistry, in situ hybridization for EBV (EBER), and fluorescence in situ hybridization (FISH) for DUSP22/MUM1 gene translocation.

**Results:** Fifty-one specimens from 32 patients with MF were identified with a male to female ratio of 1.5:1 and a median age of 50.5 (range, 16-82). Tumors from 11 patients (34%) underwent large cell transformation, with the median age at 61 (range, 26-82). The tumor cells of t-MF expressed CD30 and MUM1 in 82% and 100% cases, respectively. CD56 was expressed in two (10%) of 21 MF cases and two (18%) of 11 t-MF cases, respectively; and all four CD56-positive cases were of a helper T-cell phenotype. FISH study showed rearranged DUSP22/MUM1 in one (9%) of 11 t-MF cases. All CD56-expressing MF and t-MF tumors tested for EBER were negative. Four patients with t-MF died of disease and six were alive with disease in a median follow-up time of 25 months (mean, 44.7 months).

**Conclusion:** Large cell transformation and aberrant CD56 expression were more frequent in patients with MF in Taiwan as compared to that in the West. MUM1 expression could serve as a surrogate marker for identifying MF cases with transformation. Larger case series and/or national studies are needed to clarify the significance and impact of large cell transformation on the prognosis of patients with MF and t-MF.

LYS-P-38

## Diagnostic yield of nerve biopsy in neurolymphomatosis: pathology and PCR-based clonality testing. A serie of 15 cases

Mathilde Duchesne<sup>1,2</sup>, Olivier Roussellet<sup>3</sup>, Thierry Maisonobe<sup>4</sup>, Nathalie Gachard<sup>5</sup>, Marine Armand<sup>6</sup>, Laurence Richard<sup>2</sup>, Arnaud Jaccard<sup>7</sup>, Jean-Michel Vallat<sup>2</sup>, Laurent Magy<sup>2,3</sup><sup>1</sup>Pathology, <sup>2</sup>Laboratory of Neurology, <sup>3</sup>Neurology, University Hospital of Limoges, Limoges, <sup>4</sup>Clinical Neurophysiology, University Hospital La Pitié-Salpêtrière, Paris, <sup>5</sup>Biological Hematology, University Hospital of Limoges, Limoges, <sup>6</sup>Biological Hematology, University Hospital La Pitié-Salpêtrière, Paris, <sup>7</sup>Hematology, University Hospital of Limoges, Limoges, France

**Background:** Neurolymphomatosis, which is the infiltration of the peripheral nervous system by lymphoma, is a rare condition among the spectrum of lymphoma-associated neuropathies. It can be secondary to a systemic hematologic malignancy or primary, consisting of isolated peripheral nervous involvement by malignant cells. Diagnosis is challenging because of clinical variability and difficulties encountered on histology. If cerebrospinal fluid analysis is of great value, sometimes nerve biopsy may be necessary to



prove invasion by malignant cells. Clonality Polymerase Chain Reaction (PCR)-based analysis is a validated method in the diagnosis of hematological malignancies, but there are very little data on its diagnostic yield on nerve biopsy samples. We explored the contribution of nerve biopsy with clonality analysis to the diagnosis of neurolymphomatosis.

**Principals/Methodology:** This is a two-center retrospective study performed between 2005 and 2016. Patients with a negative cerebrospinal fluid examination and nerve biopsy-confirmed diagnosis of neurolymphomatosis were included. Histological and clonality analysis of nerve biopsies were analyzed and compared. Moreover, we assessed the performance of clonality testing in a case-control manner, using patients with inflammatory infiltrates on nerve biopsy as controls.

**Results:** 15 patients were included: 14 B-cell lymphomas; one T-cell lymphoma. Neurolymphomatosis was the first manifestation of lymphoma in 60%. The main clinical pattern being progressive symmetrical sensory-motor polyneuropathy (40%) and painful neuropathy (80%). Hematological malignancy was strongly suspected on histological features in 73.3%, but neurolymphomatosis could be diagnosed on histology alone in only 40% cases because of low infiltrates. PCR-based clonality showed monoclonal rearrangement in 86.7% and was unsuccessful in 8.1%. Performance of clonality testing was as follows: 92.9% positive predictive value, 90% negative predictive value, 86.7% sensitivity, 94.7% specificity.

**Conclusion:** This study confirms the diagnostic challenge of neurolymphomatosis and the usefulness of nerve biopsy, but points out that the low rate of infiltrates may be an additional difficulty. It highlights the high performance of the PCR-based clonality test for assessing the malignant nature of lymphoid infiltrates of the peripheral nervous system, particularly to prove the monoclonality of a weak infiltrate or to help differentiate neurolymphomatosis from an inflammatory response.

LYS-P-39

## WHO Classification of Malignant lymphomas in Korea: Report of the 4th nationwide study

Kim Hyun-Jung<sup>\*1</sup>, Hye Ra Jung<sup>2</sup>, Ji Eun Kim<sup>3</sup>, Geongsin Park<sup>4</sup>, Jae Ho Han<sup>5</sup>, Dae Woon Eom<sup>6</sup>, Hee Jung Cha<sup>7</sup>, Young-Hyeh Ko<sup>8</sup>, Jooryung Huh<sup>9</sup>, Yoon Kyung Jeon<sup>10</sup>, Sun Och Yoon<sup>11</sup>, Young-A Kim<sup>12</sup>, Jin Ho Paik<sup>13</sup>, Ji-Young Choe<sup>14</sup>, Soo Kee Min<sup>15</sup>, Hee Kyung Kim<sup>16</sup>, Wook Youn Kim<sup>17</sup>, Suk Jin Choi<sup>18</sup>, Seung-Sook Lee<sup>19</sup>

<sup>1</sup>Inje Univ. Sanggye Paik Hospital, Seoul, <sup>2</sup>Department of Pathology, Keimyung University Dongsan Medical center, Daegu, <sup>3</sup>Department of Pathology, Seoul National Univ. Boramae Hospital, <sup>4</sup>Department of Pathology, Seoul St. Mary's Hospital, The Catholic Univ., Seoul, <sup>5</sup>Ajou Univ, Suwon, <sup>6</sup>Department of Pathology, Gangneung Asan Hospital, Gangneung, <sup>7</sup>Department of Pathology, Ulsan Univ, Ulsan, <sup>8</sup>Department of Pathology, Samsung Medical Center, <sup>9</sup>Department of Pathology, Asan Medical Center, <sup>10</sup>Department of Pathology, Seoul National University, <sup>11</sup>Department of Pathology, Yonsei University Severance hospital, <sup>12</sup>Department of Pathology, Seoul National University, Boramae Hospital, <sup>13</sup>Department of Pathology, Seoul National University Bundang Hospital, Seoul, <sup>14</sup>Department of Pathology, Hallym University Sacred Heart Hospital, Anyang, Anyang, <sup>15</sup>Department of Pathology, Hallym University Sacred Heart Hospital, Anyang, Anyang, <sup>16</sup>Department of Pathology, Soonchunhyang University Bucheon Hospital, Bucheon, <sup>17</sup>Department of Pathology, Konkuk University, Seoul, <sup>18</sup>Department of Pathology, Inha University, Incheon, <sup>19</sup>Department of Pathology, Korea cancer center hospital, Seoul, Korea, Republic Of

**Background:** The aim of study was determine the relative frequency and change of malignant lymphoma according to 4<sup>th</sup> World Health Organization (WHO) classification in Korea, compared to the report of one decade ago, based on 3<sup>rd</sup> WHO.

**Principals/Methodology:** A total of 7737 new cases of diagnosed at 31 institutes between 2015 and 2016 were enrolled. Information including age, gender, pathologic diagnosis, site of involvement and immunophenotype were obtained. All possibly recurrent and duplicated cases were excluded through the mutual process of ID check.

**Results:** The relative frequency of non-Hodgkin lymphoma (NHL) and Hodgkin lymphoma (HL) was 94.8% and 5.2%, relatively. B-cell lymphomas accounted for 83.1% of all NHL, while T/natural killer (NK)-cell lymphomas accounted for 16.4%. Immunodeficiency associated LPD was occupied of the rest of NHL (0.5%). The most frequent subtypes of NHL were diffuse large B-cell lymphoma (41.5%), extranodal marginal zone lymphoma (MZL) (19.8%), follicular lymphoma (7.5%), NK/ T cell lymphoma (4.2%) and peripheral T cell lymphoma (PTCL), unclassified (3.4%), in decreasing order. The frequency of HL was nodular sclerositis (48.5%), mixed cellularity (28.7%), lymphocyte rich (6.8%), lymphocyte depletion (1.5%), lymphocyte predominant (2.8%), and unclassified HL (11.8%). Compared with a previous study of 2005-2006 data, an increase in B cell lymphomas (77.6 à 83.1%) and slightly decreased of NK/T-cell lymphomas and PTCL, U were observed. Especially, the incidence of follicular lymphoma was increasing more than 2.5 folds. (2.9 to 7.5%).

**Conclusion:** Korea had still lower rates of HL and higher rates of extranodal NHL, extranodal MZL, and NK/T-cell lymphoma of nasal type compared with Western countries. Changes in relative frequency of B cell lymphoma group are slightly enlarged rather than T cell group and quite increase of follicular lymphoma are likely ascribed to refined diagnostic criteria and westernized disease pattern.

**References:**

1. Kim JM, Ko YH, Lee SS, Huh J, Kang CS, Kim CW, Kang YK, Go JH, Kim MK, Kim WS: **WHO classification of malignant lymphomas in Korea: report of the third nationwide study.** Korean J Pathol 2011, **45**:254-260.
2. Ko YH, Kim CW, Park CS, Jang HK, Lee SS, Kim SH, Ree HJ, Lee JD, Kim SW: **REAL classification of malignant lymphomas in the Republic of Korea.** Cancer 1998, **83**:806-812.

LYS-P-40

## Hypoxia and the immune microenvironment of DLBCL: HIF1a, HIF2a, and PDL1 immunohistochemical expression and clinical outcome analysis

Vladislav Makarenko<sup>1</sup>, Karen Dresser<sup>1</sup>, Benjamin J. Chen<sup>\*1</sup>

<sup>1</sup>Pathology, University of Massachusetts Medical School, Worcester, United States

**Background:** Hypoxia inducible factor (HIF) is a transcription factor that regulates expression of genes involved in responses to hypoxia and can modulate the tumor microenvironment. HIF1a expression in diffuse large B-cell lymphoma (DLBCL) has previously been shown in some studies to be associated with inferior survival. Similarly, the immune checkpoint molecule programmed cell death ligand-1 (PDL1) can modulate the immune microenvironment by downregulating T cell activity. Expression of PDL1 on DLBCL has also been associated with inferior overall survival (OS). HIF-dependent transcriptional pathways increasing PDL1 expression have been proposed. In this study, we hypothesized that HIF1a and HIF2a expression would correlate with PDL1 expression in DLBCL and would be associated with inferior patient outcomes.

**Principals/Methodology:** We retrospectively identified 49 cases of DLBCL (including nodal and extranodal cases) and extracted relevant clinicopathologic data from these patients. HIF1a, HIF2a, and PDL1 immunohistochemical analysis was performed on FFPE sections and correlated with clinical outcome data. This study was approved by the UMass IRB.



**Results:** Extranodal DLBCL represented 76% of cases. Immunohistochemical staining was positive for HIF1a in 15 cases (31%) and for HIF2a in 23 cases (47%). HIF1a, but not HIF2a, expression showed strong correlation with PDL1 expression ( $p=0.011$ ). Patients with tumors expressing HIF1a, but not HIF2a, demonstrated inferior OS upon long term follow up ( $p=0.045$  and  $0.059$ , respectively).

**Conclusion:** HIF1a, but not HIF2a, immunohistochemical expression strongly correlated with PDL1 expression and was associated with inferior patient outcome. Further studies of association between HIF1a and PDL1 and possible clinical implications for DLBCL patients are warranted.

LYS-P-41

## Cutaneous B-Cell Lymphoma: A Retrospective Clinicopathological Evaluation of 92 Cases

Derya Demir<sup>1</sup>, Nazan Ozsan<sup>1</sup>, Banu Yaman<sup>1</sup>, Taner Akalin<sup>1</sup>, Mine Hekimgil<sup>1</sup>

<sup>1</sup>Department of Pathology, Ege University Faculty of Medicine, Izmir, Turkey

**Background:** The skin is the second most common extranodal site involved by non-Hodgkin lymphomas, following the gastrointestinal tract. Cutaneous B-cell lymphomas (CBCLs) make up 25% to 30% of all primary cutaneous lymphomas (PCL). PCL has characteristic clinical and histological features, and often has a much better prognosis compared with histologically similar nodal counterparts involving the skin secondarily. The aim of this study was to evaluate cases diagnosed in skin biopsies with their presenting features, the subtypes, clinical, morphological and immunophenotypic characteristics, in view of the literature.

**Principals/Methodology:** We reviewed the medical records of our department for the 92 cases diagnosed as CBCLs, between January 1999 and March 2018 retrospectively.

**Results:** Among the 92 cases, diffuse large B cell lymphoma (DLBCL) was the most common type; accounting for 32.6% of all (30 cases), followed by marginal zone lymphoma (MZL)(20.7%), primary cutaneous follicle center lymphomas (16.3%), DLBCL, leg type (12%), follicular lymphoma (6.5%), small lymphocytic lymphoma (4.3%), B-lymphoblastic lymphoma (4.3%), mantle cell lymphoma, plasmablastic lymphoma, and Hodgkin lymphoma. The mean age of onset was 55.6 years old. Except for B-ALL and HL; others were observed in 5th-7th decades. There was a male predominance. The most commonly involved site was trunk, followed by face, scalp, lower extremity, arm, neck, axilla, inguinal, meanwhile multifocal skin lesions was seen in 13 cases (14.1%). Of all the cases, 69 cases were identified as PCBCLs. MIB1 proliferation index was the highest in DLBCL, leg type (mean: 82%), and using the Hans algorithm all of them were non-germinal center origin; meanwhile 68.2% of DLBCLs were of germinal center origin. About 80% of MZLs were positive with CD23, besides the follicular dendritic cell meshwork positivity. The mean overall survival was 44.9 months (1-198); on follow-up period up to 18 years, 64 cases were alive, and the total mortality rate was 25.5%.

**Conclusion:** In general, PCBCLs have a more indolent clinical course and a more favorable prognosis compared to their nodal counterparts. Tumor type and degree of extra cutaneous involvement are the most important prognostic factors in our series, similar to literature. In our experience, PCMZLs express CD23 on neoplastic cells, and this finding not often seen in nodal MZLs, has not been reported in literature.

### References:

1. Wilcox RA. *Am J Hematol.* 2015;90:73-6
2. Stefoni V. *Clin Lymphoma Myeloma Leuk.* 2018;18:297-2992

LYS-P-42

## Frequency of high-grade B cell lymphomas with diffuse large B cell morphology detected by FISH study (MYC,BCL2,BCL6) with relevance of double-expressor or non double-expressor phenotype. A clinical-pathological correlation in 210 Mexican cases

Carmen Lome-Maldonado<sup>1</sup>, Paulina Elizabeth Santana-Vargas<sup>1</sup>, Deissy Roxana Quezada-López<sup>1</sup>, Renata Rivera-Juárez<sup>1</sup>, Dolores Nava-Espinal<sup>1</sup>, Diego Armando Zúñiga-Tamayo<sup>1</sup>, Silvia Rivas-Vera<sup>2</sup>, Hugo Arturo González-Martínez<sup>1</sup>, Martha Liliana Moreno-Martínez<sup>1</sup>, Darwin David Pérez-Rodríguez<sup>1</sup>, Víctor Hugo Olivera-Rodríguez<sup>1</sup>, Arturo Angeles-Angeles<sup>3</sup>, Ana Florencia Ramírez-Ibarguen<sup>1</sup>  
<sup>1</sup>Pathology, <sup>2</sup>Hematology, Instituto Nacional de Cancerología, <sup>3</sup>Pathology, Instituto Nacional de Ciencias Medicas y Nutricion Salvador Zubiran, Mexico D.F., Mexico

**Background:** Diffuse large B-cell lymphoma (DLBCL) is a heterogeneous disease in which 30-40% of the cases show partial response and tendency to progression. The prognostic value of specific biomarkers has taken relevance in the classification and diagnosis. Currently the classification by cellular origin is not enough, it is advisable to determine the double-expressor phenotype (DE) (MYC>40% and BCL2>50%), and FISH study for MYC, BCL2, BCL6 genes. High-grade B cell lymphoma (HGBCL) includes those cases with complex genetic alterations, double and triple hit (MYC+BCL2 rearrangement (R), MYC+BCL6 R and MYC+BCL2+BCL6 R).

**Principals/Methodology:** Paraffin-embedded samples of 210 DLBCL (2015-2016) were studied by morphology, immunohistochemistry (CD20, CD3, BCL6, BCL2, MUM1, CD10, Ki67, MYC) and FISH with break-apart probes for MYC, BCL2, BCL6 genes.

**Results:** 59% of the cases were of germinal center origin (GC), 41% of non-germinal center origin (NCG). 52 cases presented a DE, 158 non double-expressor (NDE) phenotype (Tab1). Cytogenetically the alteration most frequently found was the amplification of MYC (37%). The rearrangement of MYC was more frequent among DE cases (11%) than in the group of NDE (6%). In 75/210 cases it was possible to analyze the 3 genes by FISH (Tab2), 35/75 cases showed phenotype DE and 40/75 NDE. The frequency of HGBCL (double/triple Hit) was 10.6% similar to other studies, 6/8 showed a DE phenotype and GC origin. Interestingly 2/8 cases of HGBCL belongs to the NDE group with GC origin. Only 2/75 (2.6%) cases corresponded to the DLBCL group with exclusive R of MYC. The overall survival (OS) for the 210 cases was 75% at 2 years. The cases with amplification of MYC and those with R and amplification of BCL2 showed a trend towards a lower OS, but a longer-term follow-up is mandatory.

**Conclusion:** The frequency of HGBCL in these Mexican samples is similar to the one reported by other groups. The NDE phenotype does not exclude the possibility to find genetic alterations in the genes included in the study. The OS is similar to other series, though the follow-up period could be an influencing factor. The MYC-R/IG study by FISH is in progress and could provide additional information. Aligned with the 2016 WHO classification and the new therapeutic alternatives the use of FISH for the HGBCL diagnostic becomes a priority which entail an economic repercussion for developing countries. The criteria for selecting the cases for FISH study is not still very clear.



**Image:**

Tab 1. Distribution by origin and immunophenotype (DE/NDE) of the 210 cases of DLBCL

IMMUNOPHENOTYPE	CG	NGC	INDETERMINATE	Total
DE	29	20	3	52
NDE	96	49	13	158
<b>Total</b>	<b>125</b>	<b>69</b>	<b>16</b>	<b>210</b>

Tab 2. Results of 75 cases (35 DE y 40 NDE) with FISH performed for BCL-2, BCL-6 and MYC genes

FISH	DE	NDE	Total of cases
Without MYC-BCL2-BCL6 alterations	17	26	43
Double-Hit MYC + BCL2	3	1	4
Double-Hit MYC + BCL6	1	0	1
Triple-Hit	2	1	3
MYC- R' as unique alteration	2	0	2
MYC-Amp + R' in BCL2	3	5	8
MYC-Amp + R' in BCL6	2	1	3
BCL2 R' + BCL6 R'	5	6	11
<b>Total</b>	<b>35</b>	<b>40</b>	<b>75</b>

\* R: rearrangement

LYS-P-43

## Mutational analysis using NGS shows frequent targetable mutations in double-hit and triple-hit high grade B cell lymphoma (HGBL) and detects tnfaip3 mutations in transformed cases

Sarah Medane<sup>1</sup>, Cedric Pastoret<sup>2</sup>, Aline Moignet Autrel<sup>3</sup>, Marc-Antoine Belaud-Rotureau<sup>4</sup>, Thierry Fest<sup>5</sup>, Thierry Lamy de la Chapelle<sup>3</sup>, Roch Houot<sup>3</sup>, Francisco J. Llamas Gutierrez\*<sup>1</sup>

<sup>1</sup>Anatomie et Cytologie Pathologiques, <sup>2</sup>Laboratoire d'hématologie cellulaire, <sup>3</sup>Hématologie Clinique, <sup>4</sup>Service de cytogénétique et biologie cellulaire, <sup>5</sup>Université de Rennes 1, INSERM U917, hematobiologique CHU Pontchaillou, CHU de Rennes, Rennes, France

**Background:** Double-hit (DH) and triple-hit (TH) lymphomas are defined by the presence of rearrangements and breakpoints at MYC and BCL2 and/or BCL6. Approximately one half of these lymphomas have a prior or a synchronous follicular lymphoma (FL).

DH/TH HGBLs have a dismal prognosis. Recently, some recurrent overlapping mutations in DLBCL have been reported by several groups and will hopefully be used to guide treatment as new therapeutic options appear. Only few studies have addressed the molecular characteristics of DH/TH HGBL.

**Principals/Methodology:** Nine MYC/BCL2 DH HGBL, nine MYC/BCL6 DH HGBL and four TH lymphomas where retrospectively selected from the archives. Seven cases had a prior follicular lymphoma. Morphology was assessed by two pathologists according to the new 2016 WHO classification. Cases were classified using the Hans algorithm. NGS analysis was performed to detect mutations in 12 genes (CD79A, CD79B, CARD11, MYD88, TNFAIP3, NOTCH2, TP53, MYC, BCL2, BRAF, XPO1 and EZH2).

**Results:** Most patients presented with advanced clinical stage (90% III/IV), elevated LDH (41%) and extra nodal presentation (77%). Most cases (66.7%) had an intermediate DLBCL/BL morphology while 28.6% had a DLBCL and 4.7% a blastoid morphology. Interobserver kappa coefficient was moderate (0.60), indicating 80% concordance. All cases were classified as GC by the Hans algorithm.

Sixteen cases where analyzed on NGS, 15 had 1 to 5 mutations. Mutations concerned the following genes: BCL2 (11), CARD11 (9), NOTCH2 (7), MYC, TNFAIP3, TP53 (6), EZH2 (3) and CD79B (1). There was no significant difference between the three groups. We found that TNFAIP3 mutations were significantly more frequent in transformed cases ( $p=0.035$ ). Mutation frequencies from our series were compared with series addressing DLBCLs somatic mutations. Cases from our series showed more frequent CARD11, BCL2, MYC, NOTCH2, TNFAIP3 and TP53 mutations.

**Conclusion:** Our results suggest that double-hit and triple-hit HGBL have more frequent somatic mutations than DLBCL NOS, some of these mutations (MYC, EZH2, BCL2) represent potential therapeutic targets or could be used to guide treatment. Few studies separate de novo from transformed cases, we believe this could partially explain differences in therapeutic response and prognosis. In our study, TNFAIP3 mutations were significantly more frequent in transformed cases and could probably be used to identify them. Further studies with more patients are necessary to confirm these findings.

LYS-P-44

## Incidence of Hodgkin and non-Hodgkin lymphoma in HIV positive patients. High incidence of Epstein Barr virus coinfection in a Mexican population.

Diego Armando Zuñiga-Tamayo<sup>1</sup>, Dolores Nava-Espinal<sup>1</sup>, Brenda Acosta-Maldonado<sup>2</sup>, Ana Florencia Ramírez -Ibarguen<sup>2</sup>, Patricia Volkow-Fernández<sup>3</sup>, Ana Janeth Salazar-Vargas<sup>1</sup>, Deissy Roxana Quezada-López<sup>1</sup>, Hannali Quintero-Buenrostro<sup>1</sup>, Ingrid Karla Freeze-Gallardo<sup>1</sup>, Diana Karen Cante-Lima<sup>1</sup>, Arturo Angeles-Angeles<sup>4</sup>, Carmen Lome-Maldonado<sup>1</sup>

<sup>1</sup>Pathology, <sup>2</sup>Hematology, <sup>3</sup>Infectology, Instituto Nacional de Cancerología, <sup>4</sup>Pathology, Instituto Nacional de Ciencias Medicas y Nutricion Salvador Zubiran, Mexico D.F., Mexico

**Background:** The risk of developing non Hodgkin lymphoma (NHL) in HIV patients is 77 times higher compared to general HIV negative population. The increase in the incidence of coinfections by human herpes virus 8 (HHV8) and Epstein Barr virus (EBV) associated with HIV lymphomas (HIV-L) is well known, reaching up to 40% for EBV HIV-L in different series, though the frequency of infection by EBV is demographically variable and has not been documented in HIV lymphomas in Mexico. The 2016 WHO classification includes a variety of lymphoproliferative processes, predominantly aggressive B-cells-lymphomas. The correct diagnosis requires a morphological, immunohistochemical (IHC) and in some cases cytogenetic and molecular studies.

**Principals/Methodology:** We included 138 cases of HIV-L from 2011 to 2016. In order to determine the incidence of histological subtypes based on the WHO 2016 criteria and the incidence of co-infection by EBV and/or HHV8 in our population, an hematopathologic reclassification process was performed based on morphological, IHC and molecular studies.

**Results:** From 2011-2015 period 2056 cases of lymphoma were registered, and from these 138/2056 (6.7%) were HIV related. The reclassification process showed 25% of diagnostic discrepancies, then only 138 cases of HIV-L were included, 86% from these corresponded to NHL (115 B NHL and 3 T NHL) and 14% to cHL. DLBCL was the most frequent subtype (35%), followed by plasmablastic lymphoma (PBL) (28%) (Tab1). We found a male predominance (14.3:1) and most cases were in advanced clinical stage (85%)



(Tab1). The total incidence of EBV cases was 70.2% and 5.7% for HHV8 all of them with EBV coinfection, 30% of DLBCL and 63% of BL were EBV related. All cases of cHL, PBL, EC-PEL and CNS DLBCL were associated with EBV infection. Interestingly, in 3 cases it was not possible to classify them according to the WHO 2016 criteria since they presented atypical features and EBV/HHV8 coinfection. These cases were denominated as "atypical lymphoproliferative process HHV8"

**Conclusion:** In our series the incidence of HIV-L is 6.7%. We found 25% of discordant diagnoses probably due to a limited IHC studies, that could possibly influence the prognosis and demographic epidemiological data. The PBL showed a higher frequency in our population (28%) than in other series (3-12%). The incidence of association with EBV is notoriously higher than the one described in other series of developed countries (70% vs. 40%), whereas that of HHV8 is similar to that reported previously (5% vs. 3%).

**Image:**

Tab1. Clinical features in 138 HIV lymphomas by histological type.

Clinical Features	HL n=20 (14.5%)	Non-Hodgkin Lymphoma n=118 (85.5%)								T-cell n=2 (2.2%)
		DLBCL n=40	FDLBCL CNS n=5	PBL n=32	BL n=24	PTLD-like n=6	EC-PEL n=4	Atypical HHV8- LPD n=3	MCL n=1	
CD4+ T-cell median (CD4 T-cell/mm <sup>3</sup> )	190.6	158	125	157.5	177.6	276.9	129	211	63	231
Viral load (copies/ml)	77,293	614,422	555,393	209,714	244,743	7772,640	101,521	187,709	-	157,546
Clinical staging I/II	5	5	-	5	3	0	0	0	0	0
Clinical staging III/IV	15	26	-	26	21	2	4	3	1	3
Extranodal disease	9	27	5	27	20	1	2	3	1	3
B lymphoma	14	24	4	24	19	3	4	3	1	2
CNS infiltration	0	7	5	7	5	0	1	1	0	1
BM infiltration	2	7	0	7	10	0	0	0	1	1
Chemotherapy/ radiation therapy	17/9	32/13	3/2	26/9	21/7	3/1	4/0	4/1	1/0	2/1
Coital response	13	17	3	20	9	3	2	3	0	2
Disseminated progression/Satellitosis	13/2	6/6	0/0	5/10	5/5	0/0	1/0	0/0	0/0	0/0

Tab 2: Frequency of EBV and HHV8 coinfection in 138 cases of HIV lymphomas.

Lymphoid Neoplasms (138c)	EBER ISH+	HHV8+	Negative (EBER ISH-, HHV8-)
HL (20)	100% (20)	0%	0%
<b>Non-Hodgkin Lymphomas</b>			
DLBCL (40)	30% (12)	0%	47.5%(16)
FDLBCL CNS (5)	100% (5)	0%	0%
PBL (32)	100% (32)	0%	0%
BL (24)	63% (15)	0%	29%(7)
Extranodal PEL (4)	100% (4)	100%(4)	0%
Atypical HHV8-LPD (3)	100% (3)	100% (3)	0%
PTLD-like (6)	100% (6)	0%	0%
Mantle cell lymphoma (1)	0%	0%	100% (1)
Extranodal NK/T-cell lymphoma, nasal type (2)	100% (2)	0%	0%
Anaplastic large cell lymphoma, ALK- (1)	0%	0%	100%(1)

EBER ISH: in situ hybridization for Epstein-Barr virus- encoded small RNA. HHV8: human herpesvirus 8. DLBCL: Diffuse large B-cell lymphoma. FDLBCL CNS: Primary diffuse large B-cell lymphoma of the CNS. PBL: Plasmablastic lymphoma. BL: Burkitt lymphoma. Extranodal PEL: Extranodal primary effusion lymphoma. HHV8-LPD: HHV8-associated lymphoproliferative disorder. MCL: Mantle cell lymphoma. PTLD-like: lymphoid proliferations resembling post-transplant lymphoproliferative disorder.

LYS-P-45

## Diagnostic Utility of LMO2 and CD38 as an Immunohistochemical Panel in Distinguishing Burkitt lymphoma from other aggressive B cell lymphomas

Yifei Liu<sup>\*1,2</sup>, Tingting Bian<sup>2</sup>, Jianguo Zhang<sup>2</sup>, Jianlan Xie<sup>1</sup>, Yanlin Zhang<sup>1</sup>, Xiaoge Zhou<sup>1</sup><sup>1</sup>Pathology, Beijing Friendship Hospital, Capital Medical University, Beijing, <sup>2</sup>Pathology, Affiliated Hospital of Nantong University, Nantong, China

**Background:** The distinction between Burkitt (BL) or High-grade B-cell lymphoma, NOS (HGBL, NOS) and Burkitt-like lymphoma with 11q aberration can be difficult using standard morphologic and common immunohistochemical criteria. Recently, LMO2 and CD38 are expressed as nuclear markers in normal germinal-center (GC) B cell.

**Principals/Methodology:** A total of 58 BL, 12 HGBL, NOS and 3 Burkitt-like lymphoma with 11q aberration were enrolled in our cohort study. We analyzed the expressions of LMO2 and CD38 using immunohistochemistry. Furthermore, Staining intensity and percentage of positive-staining cells were recorded. Sensitivity and specificity values for immunostains, individually and in combination, were computed and compared.

**Results:** The sensitivity and specificity of LMO2- for detecting BL were 98.28% and 80%, those of CD38+ were 98.28% and 53.33%. The sensitivity and specificity of the both for detecting BL were 98.28% and 80%, respectively. In our study, the use of LMO2-/CD38+ had a higher area under the curve compared to LMO2- or CD38+.

**Conclusion:** The immunohistochemical of LMO2-/CD38+ is a potential ancillary diagnostic tool that provides strong support in distinguishing BL from other aggressive B cell lymphomas.

LYS-P-46

## Comparison of the Lymph2Cx assay and Hans algorithm in determining the Cell-Of-Origin of diffuse large B-cell lymphomas

Inju Cho<sup>\*1,2</sup>, Nara Yoon<sup>3</sup>, Jiyeon Hyeon<sup>2</sup>, Jongmin Sim<sup>2</sup>, Soomin Ahn<sup>4</sup>, Hae Yong Yoo<sup>5</sup>, Suk Jin Kim<sup>6</sup>, Won Seog Kim<sup>6</sup>, Young Hyeh Ko<sup>2</sup><sup>1</sup>Department of Hospital Pathology, Yeouido St. Mary's Hospital, <sup>2</sup>Department of Pathology and Translational Genomics, Samsung Medical Center, Seoul, <sup>3</sup>Incheon St Mary's hospital, Incheon,<sup>4</sup>Department of pathology, Seoul National University Bundang Hospital, Seongnam, <sup>5</sup>Department of Health Sciences and Technology, Samsung Advanced Institute for Health Sciences and Technology,<sup>6</sup>Division of Hematology and Oncology, Department of Medicine, Samsung Medical Center, Seoul, Korea, Republic Of

**Background:** In the era of precision medicine, accurate and reproducible assignment of cell-of-origin (COO) in diffuse large B-cell lymphoma (DLBCL) patients has become important. Lymph2Cx assay is accurately determining COO by analyzing RNA expression of 20 selected genes while Hans algorithm based on immunohistochemistry is the most popular method for routine diagnosis. However, there are discrepancies between the Hans algorithm and Lymph2Cx assay but the detailed characteristics of discordant cases and unclassified group of Lymph2Cx remain elusive, which need to be evaluated for better correlation.



**Principals/Methodology:** We prospectively analyzed 156 cases of DLBCL to explore the pattern and cause of discrepancy between COO determined by the Hans algorithm and Lymph2Cx assay. Lymph2Cx assay, NanoString-based multigene assay, and immunohistochemical staining of CD10, BCL6, and MUM1, was performed at the time of diagnosis.

**Results:** Hans algorithm classified 50 cases (32%) as germinal center B-cell-like (GCB) type and 106 cases (68%) as non-GCB type. Lymph2Cx assay assigned 43 cases (28%) as GCB type, 94 cases (60%) as activated B-cell-like (ABC) type, and 19 cases (12%) as intermediate/unclassified type. The overall agreement was 76% and after exclusion of unclassified type the agreement rate was 86%. In 19 cases of intermediate/unclassified type by Lymph2Cx assay, the proportion of extranodal lymphoma was significantly higher than nodal lymphoma ( $p=0.02$ ). By Hans algorithm, 8 cases (42%) of unclassified type were determined to be GCB type and 11 (58%) were non-GCB type. With regard to the clinicopathologic factors related with discrepancy between Hans algorithm and Lymph2Cx assay, endoscopic biopsy of gastrointestinal tract (36%) showed higher discrepancy rate than needle biopsy or incisional biopsy of other organs ( $p=0.052$ ). Immunophenotypically, CD10-/BCL6+/-MUM1- GCB type and CD10-/BCL6+/-MUM1+ (=30%, borderline expression) non-GCB type exhibited significantly higher discrepancy rate (6/13, 46% and 4/13, 31%) than CD10+ GCB type and MUM1+(>30%, definite expression) non-GCB type (3/29, 10% and 6/82, 7%) respectively.

**Conclusion:** These results suggest that assigning of COO by Hans algorithm for BCL6 only positive GCB type and non-GCB type with borderline MUM1 expression should be careful, especially if the MUM1 staining is weak and heterogeneous in the biopsied specimen.

LYS-P-47

## CD30-expression in neoplastic T cells of follicular T-cell lymphoma is a helpful diagnostic tool in the differential diagnosis to Hodgkin lymphoma

Sylvia Hartmann<sup>1</sup>, Olga Goncharova<sup>1</sup>, Anna Portyanko<sup>2</sup>, Elena Sabattini<sup>3</sup>, Jörn Meinel<sup>4</sup>, Ralf Küppers<sup>5</sup>, Claudio Agostinelli<sup>3</sup>, Stefano Pileri<sup>6</sup>, Martin-Leo Hansmann<sup>1</sup>

<sup>1</sup>Goethe Universität, Frankfurt, Germany, <sup>2</sup>National Cancer Center, Minsk, Belarus, <sup>3</sup>University of Bologna, Bologna, Italy, <sup>4</sup>Carl Gustav Carus University Dresden, Dresden, <sup>5</sup>University of Duisburg-Essen, Essen, Germany, <sup>6</sup>European Institute of Oncology, Milan, Italy

**Background:** Follicular T-cell lymphoma (FTCL) is derived from follicular T helper ( $T_{FH}$ ) cells. In many cases neoplastic T cells form rosettes around Hodgkin-Reed-Sternberg (HRS)-like cells, which can lead to the misdiagnosis of classical Hodgkin lymphoma (cHL). The aim of the present study was to obtain a better understanding of this rosetting phenomenon and to recognize features which are helpful in the differential diagnosis to cHL.

**Principals/Methodology:** Sixteen FTCL cases were analyzed for morphology, immunohistochemical and molecular features.

**Results:** Patients were usually elderly (mean 66 years). 15/16 FTCL presented with HRS-like cells, which were CD20-positive in 27% of the cases and Epstein-Barr virus-infected in almost all cases. Frequently, the immunophenotype of rosetting neoplastic T cells differed from the bulk neoplastic cells with less numerous  $T_{FH}$  markers expressed, suggesting a modulation of  $T_{FH}$  marker expression in the neoplastic T cells. In 75% of the cases a variable CD30-expression was encountered in the neoplastic T cells, probably reflecting an activation state of these cells. HRS-like cells were positive for CCL17, and FTCL tumor cells expressed its receptor CCR4 at variable intensity, thus potentially explaining the phenomenon of rosetting of the tumor cells around HRS-like cells.

**Conclusion:** In summary, this study confirms the presence of HRS-like cells in a high number of FTCL, suggesting that HRS-like cells may contribute to the development of this lymphoma. HRS-like cells in FTCL cannot reliably be differentiated by their immunophenotype from HRS cells of cHL. In contrast, demonstration of a T<sub>HH</sub> phenotype with CD10 and frequent CD30 expression in the neoplastic T-cell population can help to establish the diagnosis of FTCL and may even provide with CD30 a therapeutic target for these patients.

LYS-P-48

## Primary gastrointestinal lymphomas: A four year study of 152 cases from a tertiary cancer centre in South India

Rekha Appukuttan Nair<sup>1</sup>, Renu Sukumaran<sup>1</sup>, Priya M. Jacob<sup>1</sup>, Jayasudha Vasudevan<sup>1</sup>  
<sup>1</sup>Pathology, Regional Cancer Centre Trivandrum, Trivandrum, India

**Background:** Gastrointestinal lymphomas (GI lymphomas) are a heterogeneous group of neoplasms. Studies have demonstrated a wide variation in the sites of involvement and histological subtypes which are independent prognostic factors. Our aim is to study all cases of primary GI lymphomas presented to our center for a period of five years with reference to the pattern of distribution and histological subtypes and compare our data with the literature.

**Principals/Methodology:** In this retrospective study, all cases of primary GI lymphomas over a period of five years from 2010 to 2014 were analyzed. Nodal lymphomas with secondary involvement of the GI tract and recurrence of treated GI lymphomas were excluded. The diagnosis was based on the morphological findings on hematoxylin & eosin stained sections and the immunohistochemical profiles. The subtype classification was done according to the 2008 WHO classification of tumors of haematopoietic and lymphoid tissues.

**Results:** There were 152 cases of primary gastrointestinal lymphomas. Age ranged from three years to 83 years. There were 133 adult patients and 19 paediatric patients. Most common site of involvement was small intestine followed by stomach, large intestine and esophagus. Most common histologic subtype was diffuse large B- cell lymphoma (DLBCL), followed by Burkitt lymphoma, Extranodal marginal zone lymphoma of mucosa-associated lymphoid tissue ( MALT lymphoma), Follicular lymphoma, Mantle cell lymphoma , B cell lymphoma unclassifiable with features intermediate between DLBCL and Burkitt lymphoma and Plasmablastic lymphoma.

**Conclusion:** This retrospective study highlights the anatomic distribution and histological subtypes of primary GI lymphoma in a southern state of India. In this study, in all the anatomic sites, DLBCL was the most common histologic subtype. This finding was in concordance with other studies. The incidence of MALT lymphoma was low. There was a strikingly high incidence of Burkitt lymphoma. In contrast to other studies, small intestine was the commonest site of involvement of GI lymphoma in our study.

### References:

1. Koch P, del Valle F et al. Primary gastrointestinal non- Hodgkin's lymphoma: Anatomic and histologic distribution, clinical features, and survival data of 371 patients registered in the German Multicenter Study GIT NHL 01/92. *J Clin Oncol* 2001;19:3861-73.
2. Swerdlow SH, Campo E, Harris NL, Jaffe ES, Pileri SA, Stein H et al. WHO classification of tumours of haematopoietic and lymphoid tissues. 4<sup>th</sup> ed. Lyon, France: IARC; 2008.



LYS-P-49

## The Contribution and Role of Clonality Studies in the Diagnosis of Lymphoproliferative Disorders – A Tertiary-Centre’s Experience

Anna Paterson<sup>1</sup>, Hongxiang Liu<sup>2</sup>, Hesham Eldaly<sup>2,3</sup>

<sup>1</sup>Department of Histopathology, <sup>2</sup>Haematopathology and Oncology Diagnostics Service, Cambridge University Hospitals NHS Foundation Trust, Cambridge, United Kingdom, <sup>3</sup>Clinical Pathology Department, Cairo University, Cairo, Egypt

**Background:** The Royal College of Pathologists has recommended that all cases with suspected haematological malignancies should be reported in central specialist hubs to allow an accurate diagnosis and subclassification of lymphoproliferative disorders (LPDs). B and T cell clonality studies offer a valuable diagnostic adjunct in cases of possible LPDs where the findings are equivocal on morphology and immunophenotype. This study explored how clonality assays are employed in a Haematopathology diagnostics hub and in particular the (a) frequency of their use, (b) contexts in which they are used, (c) impact on the final diagnosis.

**Principals/Methodology:** All cases reviewed by the Haematopathology team over an 18 month period were identified and those which had B and/or T cell clonality studies undertaken were analysed further. The pathology report was reviewed for each case to determine why clonality assessment was undertaken and its subsequent impact on the final diagnosis.

**Results:** In total 4462 cases were reported in this time period and clonality studies were undertaken on 384 cases (8%). In 50% (193/384) the role of clonality assessment was to confirm the provisional diagnosis of a reactive process or a lymphoma, or to explore the clonal relationship between two different lymphomas; whilst in the remaining 50% (191/384) its role was to establish a diagnosis in the context of equivocal morphology and immunohistochemistry. Table 1 shows the subsequent impact of the clonality assays on the final diagnosis. In 1% (4/384) the clonality findings resulted in a significant change in the provisional diagnosis, three benign-malignant changes and one case where the diagnosis was revised from a T cell lymphoma to classical Hodgkin lymphoma.

Impact of clonality studies	No. of cases (n=384)
Aided final diagnosis	145/384 (38%)
Confirmed provisional diagnosis	155/384 (40%)
Remained equivocal following clonality studies	51/384 (13%)
No interpretable result from clonality studies	20/384 (5%)
Interpreted against clonality result	9/384 (2%)
Clonality result changed the final diagnosis	4/384 (1%)

Table 1: Impact of clonality assays in the diagnostic process

**Conclusion:** Clonality studies were used in a small but significant number of cases, 8%, with their role almost equally split between confirming a provisional diagnosis and aiding a diagnosis in equivocal cases; directly facilitating a final diagnosis being reached in 79% of the cohort.

LYS-P-50

## Leukemic presentation of small cell variant of ALK+ALCL with a novel partner PABPC1, responding to single-agent crizotinib treatment.

Dylan Graetz<sup>1</sup>, Kristine Crews<sup>2</sup>, Susana Raimondi<sup>3</sup>, John Mason<sup>3</sup>, Elizabeth Azzato<sup>3</sup>, Hiroto Inaba<sup>1</sup>, Vasiliki Leventaki<sup>3</sup>

<sup>1</sup>Oncology, <sup>2</sup>Pharmaceutical Sciences, <sup>3</sup>Pathology, St. Jude Children's Research Hospital, Memphis, United States

**Background:** Anaplastic large cell lymphoma (ALCL) is frequently associated with a t(2;5)(p23;q35) that results in the fusion of the nucleophosmin 1 (NPM1) gene at 5q35 to the anaplastic lymphoma kinase (ALK) gene at 2p23, and the nuclear and cytoplasmic localization of the 80kDa NPM1-ALK chimeric protein. A few case reports and a recent case series described the effectiveness of the ALK inhibitor crizotinib in relapsed/refractory pediatric ALK+ALCL. Here, we present a 16-month-old male with leukemic presentation of the small cell variant of ALCL, demonstrating cytoplasmic-only ALK localization, due to a novel fusion partner, the poly (A) binding protein C1 (PABPC1), treated with crizotinib.

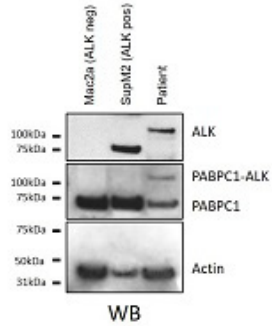
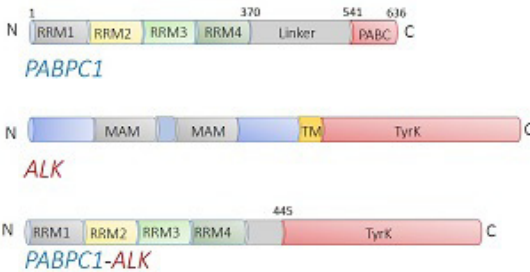
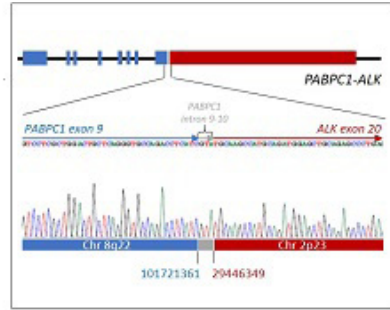
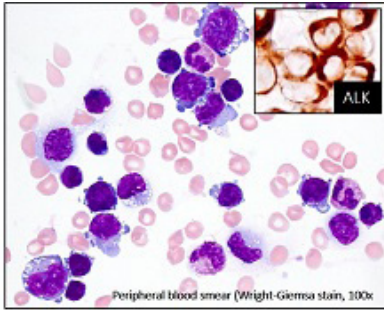
**Principals/Methodology:** Peripheral blood sample was evaluated by flow cytometry, immunohistochemistry, cytogenetics/FISH, and RNA-sequencing. The expression of the novel PABPC1-ALK fusion was verified by western blot analysis.

**Results:** A 16-month-old male presented with worsening lethargy, diarrhea, leukocytosis (235 x 10<sup>9</sup>/L), anemia (Hb 8.8g/dl), and increased LDH (439units/L). Flow cytometry and immunohistochemistry confirmed the diagnosis of the small cell variant of ALK+ALCL with cytoplasmic-only ALK localization. Cytogenetic studies showed t(2;8)(p23;q22) and RNA-seq analysis revealed a novel in frame fusion transcript spanning a junction breakpoint corresponding to PABPC1 (exon 9) and ALK (exon 20) genes, confirmed by Sanger sequencing. The novel PABPC1-ALK fusion comprises the N-terminal domain of PABPC1, including four RNA recognition motifs (RRM) and part of the Linker region, and the tyrosine kinase domain of ALK. The PABPC1 molecules are multimerized and bind the mRNA 3'-poly (A) that is critical for translation regulation and mRNA metabolism. Expression of the PABPC1-ALK fusion is predicted to give a 112kDa protein; this was confirmed by western blot analysis. The patient was initially treated on a modified ALCL99 protocol. He received three courses of conventional chemotherapy, and then due to persistent disease, he started on single agent crizotinib. He is currently in complete response following 6 months of crizotinib treatment without complications.

**Conclusion:** We describe a novel PABPC1-ALK fusion in a pediatric case of the small cell variant of ALCL with leukemic presentation. The patient's response to single agent crizotinib confirms the activity of ALK inhibitors in ALK+ALCL, and suggests a role of crizotinib treatment in ALK+ALCL as an option in patients with poor response to multiagent chemotherapy.



**Image:**



LYS-P-51

**Peripheral T-cell lymphoma, NOS: Prognostic value of the association with infection EBV in Peruvian Poblacion**

Daniela E. Dueñas<sup>1,2</sup>, Santiago Montes<sup>3</sup>, Sandro Casavilca<sup>2</sup>, Miguel Angel Piris<sup>4</sup>, Carlos Barrionuevo<sup>2</sup>  
<sup>1</sup>Translational Molecular Path, MD Anderson Cancer Center, Houston, <sup>2</sup>Instituto Nacional de Enfermedades Neoplásicas, Lima, Peru, <sup>3</sup>Universidad de Valdecilla, Santander, <sup>4</sup>Fundacion Jimenez Diaz, Madrid, Spain

**Background:** This neoplasm is of poor prognosis, and a series of factors that influence its course, evolution, and response to treatment have been described. It has been speculated whether infection with the Epstein-Barr virus (EBV) is a prognostic factor.

The main objective of this research was to evaluate if the association between PTCL-NOS and EBV infection is an independent prognostic factor in overall survival (OS) in patients with PTCL-NOS treated at the National Institute of Neoplastic Diseases (INEN).

**Principals/Methodology:** We reviewed 100 clinical histories of INEN with a diagnosis of PTCL-NOS, and the histopathological and immunophenotypic diagnosis determined with immunohistochemistry was re-evaluated. 65 cases were selected. The EBV determination was performed in the paraffinized samples with the in-situ hybridization technique (ISH-EBER).

**Results:** There were 45% of positive cases for ISH-EBER. The average age was 50 years, and 29% were women. The proportion of patients with B symptoms and without B symptoms was similar. The stages were usually advanced, with elevated dehydrogenase lactate (DHL). The international prognostic index (IPI) was intermediate-high or high in most cases. The response to treatment was generally poor. Histologically, all cases had a diffuse and polymorphic pattern of mature T cells, with variable atypia. 67% of cases had CD4 phenotype, and 23% cytotoxic phenotype.

**Conclusion:** Although positive EBV cases have a worse prognosis than negative EBV, the difference was not statistically significant. No differences were found between the presence of EBV and clinical parameters, except for B symptoms, which were more frequent in positive EBV cases. Significant differences were found in OS at three years between positive PTCL-NOS EBV with cytotoxic phenotype versus positive PTCL-NOS EBV without cytotoxic phenotype.

LYS-P-52

## PD-1 and PD-L1 expression in a small series of cases within the spectrum of CD30 positive cutaneous lymphoproliferative disorders

Aslihan Yavas<sup>1</sup>, Fadime G. Salman<sup>1</sup>, Aylin O. Heper<sup>1</sup>, Isinsu Kuzu<sup>1</sup>, Bengu N. Akay<sup>2</sup>, Hatice Sanli<sup>2</sup>, Sinem Bozdog<sup>3</sup>, Gulsah Kaygusuz<sup>1</sup>

<sup>1</sup>Department of Pathology, <sup>2</sup>Department of Dermatology, <sup>3</sup>Department of Hematology, Ankara University Faculty of Medicine, Ankara, Turkey

**Background:** Primary cutaneous CD30 positive lymphoproliferative disorders (LPDs) recognized in the WHO classification are primary cutaneous anaplastic large cell lymphoma (ALCL), lymphomatoid papulosis (LyP) and borderline lesions. These disorders have a good prognosis and usually show regression spontaneously. When recurrence or progression occurs, systemic therapies may be needed. Nowadays, targeted therapies against immune checkpoint inhibitory molecules, become increasingly important to variable malignancies. PD-1, an inhibitory member of the CD28 costimulatory receptor superfamily, is expressed on a subset of B-cells, NK/T cells, activated monocytes, and dendritic cells. The binding with PD-L1 or PD-L2 down-regulates the immune response and prevents autoimmunity. There are very limited studies concerning PD-1 and PD-L1 expressions in primary cutaneous CD30 positive LPDs. As a mechanism of immune evasion in CD30 positive LPDs, it is suggested that the follicular helper T-cells contribute the immune response against tumor cells by binding their ligands and thereby leading to down regulation of effector anti-tumor T-cell activity. In this study, we aimed to examine PD-1 and PD-L1 expressions in a small series of LyP and ALCL.

**Principals/Methodology:** Twelve cases of LyP and three cases of ALCL were included. Immunohistochemically, PD-1 (MRQ-22, Cellmarque) and PD-L1 (SP263, Ventana) were performed. The immunoreactivities were scored on both neoplastic cells and tumor microenvironment semiquantitatively, as score 0 (<5%), score 1 (6%>20%), score 2 (21%>50%) and score 3 (>50%). Fisher's exact and Mann-Whitney U tests were performed for statistical analyses. P value was considered as <0.05.

**Results:** Fifteen patients with CD30 positive LPD were investigated, of whom 5 were women (33.3%) and 10 were men (66.7%), with a median age of 47 years. PD-1 is highly expressed on all of LyP (100%) cases whereas ALCL cases exhibited various staining patterns (score 0, n=1, score 3, n=2). %58.3 cases of LyP showed PD-L1 expression with less than %50 of the cells (score 2), whereas patients with ALCL had heterogeneous staining as score 1 (n=1), score 2 (n=1) and score 3 (n=1). We could not find any correlation between PD1, PD-L1 and CD30 expressions.



**Conclusion:** The higher expression of PD-1 in LyP cases comparing to ALCL may reflect the role of immune checkpoint inhibitor proteins on controlling the disease progression. But our results need further investigation on larger case series and comparing with the other PD-1 ligands.

LYS-P-53

## Prognostic value of PD-L1 expression and EBV association in patients with primary intestinal diffuse large B-cell lymphoma

Eri Ishikawa<sup>\*1,2</sup>, Seiichi Kato<sup>3</sup>, Akira Satou<sup>4</sup>, Kei Kohno<sup>2</sup>, Kazuyuki Shimada<sup>5</sup>, Masanao Nakamura<sup>1</sup>, Yoshiki Hirooka<sup>6</sup>, Shigeo Nakamura<sup>2</sup>

<sup>1</sup>Gastroenterology and Hepatology, Nagoya University Graduate School of Medicine, <sup>2</sup>Pathology and Laboratory Medicine, Nagoya University Hospital, <sup>3</sup>Pathology and Molecular Diagnostics, Aichi Cancer Center Hospital, <sup>4</sup>Surgical Pathology, Aichi Medical University, <sup>5</sup>Hematology and Oncology, Nagoya University Graduate School of Medicine, <sup>6</sup>Endoscopy, Nagoya University Hospital, Nagoya, Japan

**Background:** Small and large intestinal lymphoma behaves differently than gastric lymphoma with comparatively lower survival. Blocking the interaction between programmed cell death (PD)-1 with its ligands, PD-L1 and PD-L2, leads to impressive antitumor responses and clinical benefit in a subset of patients, including relapsed and refractory diffuse large B-cell lymphoma (DLBCL), and the frequent up-regulation of PD-L1 in Epstein-Barr virus-positive (EBV<sup>+</sup>) lymphoma patients have been paid attention.

**Principals/Methodology:** Tumor specimens from 62 patients with primary iDLBCL were analyzed for EBV-encoded small RNA (EBER) by in situ hybridization and PD-L1 by immunohistochemistry.

**Results:** In 10 (16%) cases, tumor cells harbored EBV including seven treated for lymphoma-associated and iatrogenic immunodeficiency. Two EBV<sup>+</sup> cases were positive for PD-L1 on tumor cells, whereas the remaining eight were positive for PD-L1 on microenvironment immune cells. Three (5%) of 59 iDLBCL cases demonstrated PD-L1 expression on tumor cells and relapsed at 5, 6, or 22 months. Both EBER positivity and neoplastic PD-L1 expression were associated with worse overall survival (OS) in iDLBCL patients receiving rituximab-containing chemotherapy (P=0.0354 and P=0.0092, respectively). Multivariate analyses identified PD-L1 positivity on tumor cells (P=0.0106), PD-L1 negativity on microenvironment immune cells (P=0.0193), and EBER positivity (P=0.0324) as adverse independent prognostic factors for OS. Among iDLBCL cases without any EBV association, CD5 positivity, or neoplastic PD-L1 expression, high PD-L1 expression (≥ 40%) on microenvironment immune cells predicted extremely favorable outcomes.

**Conclusion:** EBV<sup>+</sup> iDLBCL featured an aggressive clinical course in patients with immunodeficiency, who were most likely to express PD-L1 on tumor cells or microenvironment immune cells. PD-L1 expression on iDLBCL cells predicted poor outcome, but PD-L1 expression on either tumor cells or microenvironment immune cells had adverse prognostic impacts in iDLBCL. These findings may be useful for selecting patients in the immune-oncology era.

### References:

Chen BJ, Chapuy B, Jing OY, et al. PD-L1 Expression Is Characteristic of a Subset of Aggressive B-cell Lymphomas and Virus-Associated Malignancies. *Clinical Cancer Research* 2013;19(13):3462-73.  
Taube JM, Klein A, Brahmer JR, et al. Association of PD-1, PD-1 Ligands, and Other Features of the Tumor Immune Microenvironment with Response to Anti-PD-1 Therapy. *Clinical Cancer Research* 2014;20(19):5064-74

LYS-P-54

## The role of activated stromal cells in onset of inflammation associated lymphoma: a case report

Rodothea Amerikanou<sup>\*1</sup>, Richard Burt<sup>2</sup>, Sabine Pomplun<sup>3</sup>

<sup>1</sup>Haematology Department, Royal Free Hospital, <sup>2</sup>Haematology Department, University College London,

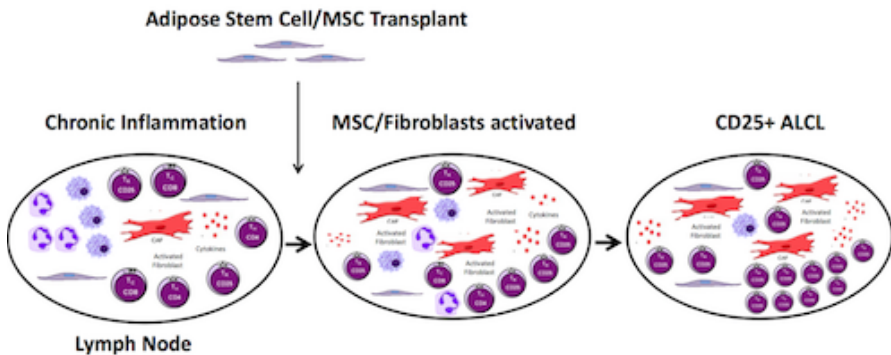
<sup>3</sup>Pathology Department, University College London Hospitals, London, United Kingdom

**Background:** Breast implant related anaplastic large cell lymphoma (BI-ALCL) arises from a fibrous capsule, rich in fibroblasts, which forms around the implant or in a peri-implant seroma. Its pathogenesis is linked to chronic inflammation induced by the foreign material. The transformation of quiescent fibroblasts or mesenchymal stromal cells (MSC) into 'activated' or cancer associated fibroblasts (CAF) has been recognised in many solid organ malignancies and recently in haematological malignancies as important in tumour progression and resistance and even as a potential driver of pre-malignant lesions into full-blown malignancy.

**Principals/Methodology:** The association between lymphoma and chronic inflammatory diseases such as coeliac disease and helicobacter pylori infection is well described. The chronic inflammatory milieu consists of a mix of different cell types, including lymphocytes, macrophages and fibroblasts. In such inflammatory conditions, fibroblasts become activated and synthetic analogous to CAFs. Their secretome induces T-cells to revert to the immunosuppressive phenotype of regulatory T cells (Tregs) while simultaneously suppressing the production of cytotoxic T cells, preventing clearance of abnormal malignant cells. The well-characterised BI-ALCL cell line TLBR-1 shares many features with Tregs, including CD25 positivity and high FoxP3 expression.

**Results:** We present the case of a 39 year-old female with a background of lichen sclerosis, a chronic inflammatory condition leading to loss of adipose tissue in the genital and groin area, who underwent a fat transplant from her buttock to the right groin and vulval area for cosmetic reasons. A fat transplant involves the transfer of adipose stem cells, which are analogous to MSC, to the affected region for regeneration of adipose tissue. One year following the procedure she presented with discomfort in the area and weight loss. A subsequent PET-CT showed localised uptake in the right groin lymph nodes. A biopsy and subsequent immunohistochemistry revealed ALK-negative ALCL, with the tumour cells expressing CD25 in keeping with a phenotype similar to BI-ALCL.

**Image:**



Proposed Development Of Inflammation Associated Anaplastic Large Cell Lymphoma



**Conclusion:** We describe for the first time lymphoma following an autologous fat transplant. Given the lymphoma was localised to the inflammatory site where cells analogous to MSC were injected, we propose that activation of such stromal cells may play a vital role in the onset of inflammation associated lymphoma including BL-ALCL, potentially by skewing local T-cells to a Treg phenotype.

LYS-P-55

## **Adaptation to hypoxia is marked by carbonic anhydrase IX expression in Hodgkin-Reed-Sternberg-cells and is associated with unfavourable response to therapy in classical Hodgkin's lymphoma**

Gábor Méhes<sup>1</sup>, Orsolya Matolay<sup>1</sup>, Marianna Czenke<sup>1</sup>, Lívía Beke<sup>1</sup>, Arpad Illés<sup>2</sup>, Judit Bedekovics<sup>1</sup>

<sup>1</sup>Department of Pathology, <sup>2</sup>Institute of Internal Medicine, Department of Hematology, University of Debrecen, Debrecen, Hungary

**Background:** Hypoperfusion and tissue necrosis is a frequent feature of classical Hodgkin's lymphoma (cHL) the clinical role of which was not intensively studied in the past. Hypoxia related expression of cell membrane carbonic anhydrases (CA) is a basic adaptive mechanism to neutralize intracellular acidosis in cancer cells. The aim of the present study was to evaluate CAIX and CAXII expression related features in primary and relapsed cHL.

**Principals/Methodology:** 65 primary lymph node biopsies diagnosed with cHL were evaluated using CAIX and CAXII immunohistochemistry and CAIX/Ki-67 double IHC to compare histological, functional and survival features.

**Results:** CAIX expression could be demonstrated in individual Hodgkin-Reed-Sternberg (HRS) cells in a highly selective fashion in 31/65 samples (47.7%) while virtually no staining presented in their micro-environment. CAXII expression was observed in both the HRS-cells and the reactive infiltrate. Necrotic foci were associated with CAIX+ HRS cells in 89.5% of the samples. CAIX phenotype was strongly associated with lymphocyte depletion (3/3, 100%) and nodular sclerosis (24/39, 62.8%) subtypes. Double IHC demonstrated suppressed cell proliferation in CAIX+ compared to CAIX- HRS-cells (mean Ki-67 labeling was  $29.72 \pm 13.07$  vs  $69.38 \pm 10.79$ , respectively) ( $p < 0.001$ ). 72 months progression free survival (PFS) was significantly lower for the CAIX+ group (0.16) compared with the CAIX- group (0.83) ( $p < 0.001$ ) while the overall survival (OS) did not differ.

**Conclusion:** CAIX and CAXII are dynamically upregulated in cHL. CAIX but not CAXII expression highlights foci of sub-lethal hypoxic injury of neoplastic HRS-cells. Hypoxic stress related adaptive changes potentially contribute to the short term failure of the standard chemotherapy observed in CAIX positive cHL.

LYS-P-56

## Cytokeratin-positive fibroblastic reticular cell tumor with focal follicular dendritic cell features: A case report

Ji Yun Jeong<sup>\*1</sup>, Jeong Ju Lee<sup>2</sup>, Tae-In Park<sup>3</sup>, Young-Hyeh Ko<sup>4</sup>

<sup>1</sup>Pathology, <sup>2</sup>Surgery, Kyungpook National University Chilgok Hospital, Kyungpook National University, School of Medicine, <sup>3</sup>Pathology, Kyungpook National University Hospital, Kyungpook National University, School of Medicine, Daegu, <sup>4</sup>Pathology, Samsung Medical Center, Sungkyunkwan University School of Medicine, Seoul, Korea, Republic Of

**Background:** Histiocytic tumors of lymph node are rare. Fibroblastic reticular cell (FRC) tumors, a subset of histiocytic tumors, are even. FRCs are stromal support cells located in parafollicular and deep cortex areas. Of FRCs, cytokeratin(CK)-positive interstitial reticular cells (CIRC) were described and a few cases of CIRC tumor have been reported.

**Principals/Methodology:** An 83-year-old woman presented with abdominal pain for 1 week. A 5.3cm sized mass at portocaval space and a 4.2cm sized mass at aortocaval space were identified on abdominal computed tomography (CT). She has lost 5 kg in a month. On neck CT and chest CT, additional mass-like lesions with low density were found at right supraclavicular, paratracheal, mediastinal, cardiophrenic angle, paraaortic areas. The masses showed high <sup>18</sup>F-fluorodeoxy glucose (FDG) uptake (SUVmax 25.1) on <sup>18</sup>F-fluorodeoxy glucose positron emission tomography (FDG-PET). She underwent mediastinal lymph node excision. Pathologic analyses including histologic and immunohistochemical analyses were performed.

**Results:** On microscopic evaluation, the excised mediastinal lymph node showed total effacement of the normal architecture by infiltration of tumor cells. Tumor cells formed nodular sheet-like aggregations or arranged in loosely cohesive vague nodular fashion. The tumor cells were round or polygonal, and had oval and large nuclei containing central nucleoli. The cytoplasm of tumor cells was abundant and has inconspicuous cell borders. Numerous and various inflammatory cells were intermixed with the tumor cells. Immunohistochemically, tumor cells were positive for CK, and EMA, but negative for LCA, CD3, CD20, CD79a, PAX5, CD138, CD68, and MPO. Tumor cells were focally positive for CD21 which suggested for follicular dendritic cell (FDC) features. Tumor cells revealed focal positivity for CD30 and CD100 also.

**Conclusion:** FRC tumors are extremely rare and the clinical courses of FRC tumors are variable and have not been fully understood. CK-positive FRC tumors, that is CIRC tumor, have been reported only about 10 cases, and tumors with characteristics of both FRC and FDC have been reported only about 2 cases. Only 1 case of a CIRC tumor with FDC features has been reported so far. Herein, we report another case, 2<sup>nd</sup> case, of CK-positive FRC tumor with focal FDC features.

LYS-P-57

## Primary extranodal lymphomas in Kerala, South India

Jayasudha A. Vasudevan<sup>\*1</sup>, Rekha A. Nair<sup>1</sup>, Renu Sukumaran<sup>1</sup>, Priya M. Jacob<sup>1</sup>, Sreejith G. Nair<sup>2</sup>

<sup>1</sup>Pathology, <sup>2</sup>Medical Oncology, Regional Cancer Centre, Thiruvananthapuram, India

**Background:** Primary extranodal lymphomas are defined as lymphomas with clinically dominant involvement of extranodal site with no or minor lymphnode involvement after routine staging procedures. The aim of our study was to analyse the frequency and distribution of primary extranodal lymphomas diagnosed in a tertiary care cancer centre in Kerala, South India.



**Principals/Methodology:** This was a retrospective study done in the Division of Pathology, Regional cancer Centre, Thiruvananthapuram, Kerala, India for a period of 2 years from 1st January 2016 to 31st December 2017. All the primary extranodal lymphomas diagnosed during this 2 year period were reviewed and classified according to the revised 4th edition WHO classification of Tumours of Haematopoietic and Lymphoid tissues.

**Results:** Among the total of 1416 cases of lymphomas diagnosed at our Centre, non-Hodgkin lymphomas (NHL) constituted 1065 cases (75.21%). Primary extranodal lymphomas (n=280) constituted 26.29% of NHL. Among these Diffuse large B-cell lymphoma (DLBCL) was the most common subtype (107 cases, 38.21%) followed by MALT lymphoma (29 cases, 10.36%) Primary diffuse large B-cell lymphoma of the CNS (26 cases, 9.29%), Mycosis fungoides (24 cases, 8.57%), Burkitt lymphoma (19 cases, 6.79%), Primary mediastinal large B-cell lymphoma (13 cases, 4.64%), Mantle cell lymphoma (13 cases, 4.64%). Most common site of presentation was head and neck region (84 cases, 30%) followed by gastrointestinal tract (60 cases, 21.43%).

**Conclusion:** We document that the frequency of primary extranodal lymphomas is comparable to western studies and a few Indian studies. Majority of primary extranodal lymphomas occurred in immunocompetent patients. DLBCL is the most common subtype and head and neck region is the most common site of primary extranodal lymphomas in our study.

#### References:

1. Krol AD, le Cessie S, Snijder S, Kluin-Nelemans JC, Kluin PM, Noordijk EM. Primary extranodal non-Hodgkin's lymphoma (NHL): The impact of alternative definitions tested in the Comprehensive Cancer Centre West population-based NHL registry. *Ann Oncol* 2003;14:131-9.
2. Padhi S, Paul TR, Challa S, Prayaga AK, Rajappa S, Raghunadharao D, et al. Primary extra nodal non Hodgkin lymphoma: A 5 year retrospective analysis. *Asian Pac J Cancer Prev* 2012;13:4889-95.
3. Mishra P, Das S, Kar R, Jacob SE, Basu D. Primary extranodal non-Hodgkin lymphoma: A 3-year record-based descriptive study from a tertiary care center in Southern India. *Indian J Pathol Microbiol* 2015;58:296-300.

LYS-P-58

## Lymphomas of the gut: 18 years' experience on 103 cases

Mine Hekimgil<sup>1</sup>, Derya Demir<sup>1</sup>, Nazan Özsan<sup>1</sup>, Hafize Ozdemir<sup>1</sup>, Murat Sezak<sup>1</sup>, Basak Doganavsargil<sup>1</sup>  
<sup>1</sup>Department of Pathology, Ege University Faculty of Medicine, Izmir, Turkey

**Background:** The incidence of small intestinal and colorectal lymphomas are low, 20% > 30% and 6% > 23%, respectively, thus primary gastrointestinal lymphoma (PGL) is an uncommon disease of the gut, with geographic variation of frequency, displaying a broad histological spectrum and clinical presentation, that may lead to bowel obstruction and perforation.

**Principals/Methodology:** We reviewed endoscopic biopsies (n=59) and/or resection specimens (n=54) of 103 primary and secondary intestinal lymphomas (ILs) with available data, diagnosed between January 2000 and March 2018 and correlated the clinicopathological features by nonparametric tests.

**Results:** Most common subtypes were diffuse large B-cell lymphoma (DLBCL) (n=47; 45.7%), and Burkitt lymphoma (BL) (n=19; 18.5%), followed by MALT lymphoma, mantle cell lymphoma (MCL), high-grade B-cell lymphoma (HGBL), peripheral T-cell lymphoma, NOS (PTL), enteropathy associated T-cell lymphoma (EATL), and follicular lymphoma (FL). Using the Hans algorithm 28.2% of DLBCLs were of germinal center origin. The median age of onset was 52 (range 3-89) years old. HGBL, BL, and DLBCL had the widest age distribution, while MCL, PTL, EATL, and FL were observed in 4th-7th decade. There was no gender

predominance (M:F ratio = 2.02). The most commonly involved site was small intestine (n=57; 55.3%), followed by colorectum (n=31; 30.1%), meanwhile multifocal involvement was seen in 15 cases (14.6%). Using Dawson's criteria for labeling PGIL, 63 cases were identified as PGIL and in 37 cases the involvement was secondary. The most common complications were perforation (n=10; 9.8%), obstructing bulky masses (n=5; 4.9%), and invagination (n=4; 3.9%); meanwhile coeliac disease-like enteropathic changes accompanied EATL (n=2; 66.6%). The mean overall survival was 35 months (0-167 months); on follow-up period up to 18 years, 52 cases were alive, and the total mortality rate was 43.5% (n=40).

**Conclusion:** It has been concluded that two thirds of the gut lymphomas are primary, most lymphomas of the lower gastrointestinal tract are located to small intestine, and most common complications were perforation, obstructing bulky masses, and invagination; meanwhile coeliac disease-like enteropathic changes accompanied EATL.

**References:**

1. Dawson IM, Cornes JS, Morson BC. *Br J Surg* 1961;49:80–9.
2. Ghimire P, Wu G-Y, Zhu L. *World J Gastroenterol* 2011 February 14; 17(6): 697-707.
3. Bautista-Quach MA, Ake CD, Chen M, Wang J. *J Gastrointest Oncol* 2012;3(3):209-25.

LYS-P-59

## Myc expression in primary central nervous system lymphoma

Joanna Reszec<sup>1</sup>, Janusz Dzięcio<sup>2</sup>, Zofia D. Anikiej<sup>2</sup>, Robert Rutkowski<sup>3</sup>

<sup>1</sup>Dep. of Medical Pathology, <sup>2</sup>Dep. of Human Anatomy, <sup>3</sup>Dep. of Neurosurgery, Uniwersytet Medyczny w Białymstoku, Białystok, Poland

**Background: Background:** Primary brain lymphoma accounts for almost 2-5% of all primary CS tumors. There are two major biologically distinct molecular subtypes of DLBCL: germinal center B-cell (GCB) and activated B-cell (ABC). Double-hit lymphomas and double-expressor lymphomas, which overexpress MYC and BCL2 protein, are aggressive DLBCLs and are also associated with a poor prognosis. The aim of the study was to compare the prognosis of DLBCL ABC and GCB type with coexpression of Myc.

**Principals/Methodology: Principles/Methodology:** 45 patients with primary CNS Diffuse large B Cell Lymphoma was included in the study. The immunohistochemistry reactions were done to determinate the type of the DLBCL and to evaluate the Myc expression (antibodies for DAKO Omnis: CD20 Dako Omnis, Clone L26, Bcl-2, Clone: 124, Monoclonal Mouse Anti-Human, Bcl-6 Clone: PG-B6p, Monoclonal Mouse Anti-Human, CD10 Clone: 56C6 Monoclonal Mouse Anti-Human) and Myc (Ventana Roche anti-c-MYC (Y69) Rabbit Monoclonal Primary Antibody).

**Results: Results:** 45 cases were included in the study. The age range: 21-79 years, 33 female and 12 male patients. All cases were negative for HIF. All of the tumors were supratentorial- 23 of them were situated in the frontal lobe, the rest in the temporal, parietal and occipital regions. All cases were diagnosed as diffuse large B-cell lymphomas based on morphology and immunohistochemistry. A panel of markers were used to classify as ABC or GCB type. Among 45 cases 32 were positive for MUM1, and 9 cases were positive for CD10. Ki-67 expression ranged from 40% to 90% of cells. Bcl-2 expression was observed in all of the cases, while Bcl-6 in 11 cases. Myc expression was observed in 18 out of 45 cases, while the coexpression of Myc and Bcl-2 in 18 cases and coexpression of Myc, Bcl-2 and Bcl-6 only in 6 cases. The Ki-67 expression in Myc positive cases was high and ranged from 80 to 90% of cells. The patients with Myc, Bcl-2 and Myc, Bcl-2, Bcl-6 co-expression had significantly shorter overall survival after high-dose chemotherapy.

**Conclusion: Conclusion:** Myc, Bcl-2 and Bcl-6 co-expression is a significant prognostic marker for primary DLBCL of the CNS.



## References:

1. S. Low, T.T. Batchelor et al. Primary Central Nervous System Lymphoma Seminars in Neurology Vol. 38 No. 1/2018 pages 86-94
2. Shi QY, Feng X, Bao W et al. MYC/BCL2 Co-Expression Is a Stronger Prognostic Factor Compared With the Cell-of-Origin Classification in Primary CNS DLBCL. *J Neuropathol Exp Neurol.* 2017 Nov 1;76(11):942-948

LYS-P-60

## Clinicopathologic comparison of initial versus secondary hematolymphoid malignant diagnosis made on effusion samples

Atif Saleem<sup>\*1</sup>, Dita Gratzinger<sup>2</sup>

<sup>1</sup>Pathology, <sup>2</sup>Stanford, Stanford, United States

**Background:** A paucity of data exists regarding the clinicopathologic features of primary lymphoproliferations compared to secondary ones diagnosed in body fluid samples. The aim of this study is to analyze clinicopathologic features in cases of initial hematolymphoid diagnosis by body fluid and compare them to cases of secondary/recurrent involvement so as to gain better insight into the pathogenesis of the lymphoproliferations which present as effusions and determine potential clinical associations or predictors of outcome. Cerebrospinal fluids (CSF) were excluded as these represent a very frequent specimen type in the management of known leukemia/lymphoma.

**Principals/Methodology:** A total of 5,785 consecutive non-CSF body fluids were queried over 5 years (2013-2018) in a single institution, 60 (approximately 1%) of which underwent a workup for hematolymphoid malignancy. The cases were separated into two groups, namely 1) Initial diagnoses of neoplastic lymphoproliferations by body fluid (n=10), and 2) Recurrent/staging diagnoses of neoplastic lymphoproliferations by body fluid in patients with a known pertinent past medical contributing history (n=50).

**Results:** In the ten primary cases the mean age at presentation was 47.5 years, the male to female ratio was 1:1, and the body fluids by decreasing frequency were pleural effusions (n = 5, 50%), ascites (n = 2, 20%), vitreous effusion (n = 2, 20%) and breast implant capsular fluid (n = 1, 10%). The diagnoses included large B-cell lymphoma (n = 7, 70%), T-lymphoblastic leukemia/lymphoma (n = 1, 10%), Burkitt lymphoma (n = 1, 10%) and breast implant-associated anaplastic large cell lymphoma (n = 1, 10%). In the second cohort, the mean age at which the secondary diagnosis of a hematolymphoid neoplasm was made on body fluid was 56.5 years, and the body fluids by decreasing frequency were pleural effusions/BAL (n = 35, 70%), ascites (n = 5, 10%), vitreous (n = 5, 10%), pericardial effusions (n = 4, 8%) and breast implant capsular fluid (n = 1, 2%). The most common diagnoses for this second cohort included DLBCL (n = 18, 36%), CLL/SLL (n = 6, 12%), and mantle cell lymphoma (n = 4, 8%).

**Conclusion:** Patients in whom the diagnosis of a hematolymphoid malignancy was initially made by body fluid were younger at mean age of presentation (47.5 years) as compared to the second cohort (56.5 years). The diagnostic entities that were represented in the first group were all aggressive hematolymphoid malignancies which is also reflected in the overall survival in this cohort.

LYS-P-61

## Identifying the nature of Perforation in patients diagnosed with Gastrointestinal Lymphoma. Do we need early interventions?

Arooj Fatima<sup>\*1</sup>, Syed Sammar Abbas Zaidi<sup>2</sup><sup>1</sup>SKMC & RC, <sup>2</sup>wecare medical centre, lahore, Pakistan

**Background:** Intestinal Perforation and Peritonitis are the leading complications of Gastro Intestinal Lymphomas which can occur either at the time of diagnosis or after the initiation of chemotherapy. Such uncommon perforations can contribute towards the high morbidity and mortality rates.

**Principals/Methodology:** Our study aims to find and address the location and timing of perforation in patients diagnosed with Gastrointestinal Lymphomas. The study also aims to highlight the importance of early identification signs of perforation which may permit early surgical intervention. Thus, preventing the morbidity and mortality of patients diagnosed with GI Lymphomas.

**Results:** 48 out of 400 patients developed perforation. Most of the perforation was developed after chemotherapy 68%. After the initiation of chemotherapy, the median day of perforation was 42 days while the 32% of the perforation occur during the first 3 week of chemotherapy. The most common lymphoma associated with perforation was Diffuse Large B Cell Lymphoma DLBCL and MALT Lymphoma. Cyclophosphamide, doxorubicin, vincristine and prednisone (CHOP) was the most frequent regimen .A hazard ratio of 7.49 was associated with aggressive B cell lymphomas compared to T cell lymphoma HR=6.42. The most common site of perforation was small intestine 66% followed by large intestine 18% and gastric 16%

**Conclusion:** Perforation of GI Lymphomas leads to critical complications. However a delay in diagnosis and early intervention may lead to significant increase in the morbidity and mortality of the patients

LYS-P-62

## Primary classical Hodgkin lymphoma of the skin, a case report

Barbara Gazic<sup>\*1</sup>, Gorana Gasljevic<sup>1</sup>, Biljana Grcar Kuzmanov<sup>1</sup>, Mojca Gjidera<sup>1</sup><sup>1</sup>Pathology, Institute of oncology Ljubljana, Ljubljana, Slovenia

**Background:** Primary cutaneous classical Hodgkin lymphoma without systemic disease is rare and less than 10 cases have been reported to date in the literature (1, 2). It shows indistinguishable morphologic and immunophenotypic features compare to its nodal counterpart and it has been suggested that this patients may have more indolent course (1).

**Principals/Methodology:** A 50-year old patient presented with non-ulcerated skin lesion on a left shoulder that measured 5 cm. A small punch biopsy was performed. The tissue was insufficient for definitive diagnosis and differential diagnosis of anaplastic large cell lymphoma, lymphomatoid papulosis and EBV positive ulcer was rendered. He received local irradiation and clinical remission was achieved. A few month after, a new 3 cm large non-ulcerated lesion on the right buttock appeared. A PET scan did not show any other lesions or enlarged lymph nodes and his blood tests were normal. An excision of the new lesion was performed.

**Results:** On H&E an atypical nodular lymphoid infiltrate is extending from the superficial dermis to the dermal/subcutis junction. The infiltrate is composed of scattered large atypical cells admixed with many small mature lymphocytes, histiocytes, plasma cells and rare eosinophils. The large cells have irregular nuclear contours, large cherry red nucleoli, and ample eosinophilic cytoplasm. They are positive for CD30,

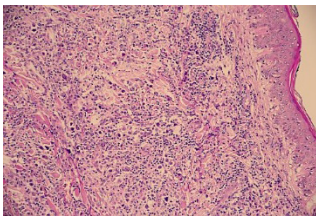


CD15 and PAX5, rarely positive for CD20 and negative for T cell markers. According to histological and clinical features the diagnosis of primary cutaneous Hodgkin lymphoma was made.

**Conclusion:** Primary cutaneous Hodgkin lymphoma is extremely rare. There is no standard of care treatment and the prognosis is variable with some of the patients developing progressive systemic disease (1, 2). In our case the patient presented with two consecutive skin lesions and no systemic disease. He is in complete remission four years after local irradiation of both lesions.

**References:**

1. Sioutos N, Kerl H, Murphy SB, Kadin ME. Primary cutaneous Hodgkin's disease. Unique clinical, morphologic, and immunophenotypic findings. *Am J Dermatopathol.* 1994; 16:2-8.
2. Koch K, Patel M, Pather S and Modi D. Primary cutaneous Hodgkin lymphoma: A rare disease variant and review of the literature. *J Case Rep Stud.* .2016; 4:1-4.



LYS-P-63

## Primary extranodal non-Hodgkin lymphoma in the North-Western region of Romania: clinicopathological features and survival.

Bogdan Fetica<sup>1</sup>, Bogdan Pop<sup>1</sup>, Mihaiela L. Blaga<sup>1</sup>, Ovidiu Coza<sup>1</sup>, Mihnea Zdrengeha<sup>2</sup>, Ciprian Tomuleasa<sup>2</sup>, Daniela Coza<sup>1</sup>, Alexandru Irimie<sup>2</sup>

<sup>1</sup>The "Prof. Dr. Ion Chiricuta" Institute of Oncology, <sup>2</sup>University of Medicine and Pharmacy "Iuliu Hatieganu", Cluj-Napoca, Romania

**Background:** Figures of non-Hodgkin lymphoma (NHL) varies significantly around the world, but there are very few epidemiologic studies of NHL in Eastern Europe. Our aim is to evaluate clinicopathological features and survival of primary extranodal NHL as compared to nodal NHL in the North-Western region of Romania.

**Principals/Methodology:** Population-based data on NHL for the period 2008 - 2013 was obtained from the North-Western Regional Cancer Registry (RRCNV), hosted by the Oncology Institute from Cluj-Napoca, that covers a total of 2573358 inhabitants (1st of July 2016) in six Romanian counties accounting for 14% of surface and 12.7% of population of Romania. For the survival study we have included cases from 2008 to 2011, only from Cluj County where complete follow-up data until December 31, 2016 was available. Pohar-Perme estimator was used to examine the 5-year net survival by nodal involvement. NHL cases were reviewed and reclassified according to the WHO classification (2008), to determine primary location and histology.

**Results:** During the study period a total of newly diagnosed 1616 primary NHL cases have been recorded accounting for 2.8 % of all malignant cases. Primary extranodal involvement was recorded in 21.5% of patients. In the extranodal group, the male to female ratio was 1.1:1, and the mean age was 58.5 years (SD=21.8). In the nodal group, the male to female ratio was 1.13:1, and the mean age was 59.8 years

(SD=16.6). Diffuse large B-cell lymphoma (DLBCL) was the most common type of NHL observed in both primary extranodal and nodal involvement. Gastrointestinal tract (33.8%), tonsil and parotid gland (14%), skin (13.4%) and spleen (12.8%) were the more frequent extranodal sites. The net survival at 5 years was 63.5% (53.4 - 71.9 95% CI) for primary extranodal NHL compared to 61.0% (54.4 - 67.0 95%CI) for nodal NHL.

**Conclusion:** We note a relatively low frequency of primary extranodal involvement in NHL in the north-western region of Romania. DLBCL was the most common morphological type observed and the gastrointestinal tract was the most common anatomical site for primary extranodal involvement. There was no statistically significant difference between extranodal and nodal NHL in terms of sex and age distribution and overall survival. A specialised lymphoma registry is needed for in-depth analysis.

**References:**

Zucca E, Cavalli F: Extranodal lymphomas. *Ann Oncol* 11,2000-S222.

North-Western Cancer Registry. *Cancer Report in North-Western Region of Romania*, 2013.

LYS-P-64

## Clinicopathologic analysis of splenic lymphoma: Three year experience

Miljan Krstić<sup>1,2</sup>, Maja Peruničić Jovanović<sup>3</sup>, Slavica Stojnev<sup>4</sup>, Petar Jovanović<sup>5</sup>, Ivan Petković<sup>6,7</sup>, Darko Antić<sup>8,9</sup>

<sup>1</sup>Department of Pathology, Faculty of Medicine, University of Nis, <sup>2</sup>Centre for Pathology, Clinical Centre Nis, Niš, <sup>3</sup>Department of Pathology, Clinical Centre of Serbia, Belgrade, <sup>4</sup>Department of Pathology, Medical Faculty, University of Nis, Niš, <sup>5</sup>Faculty of Medicine, University of Priština, Kosovska Mitrovica, <sup>6</sup>Department of oncology, Faculty of Medicine, University of Nis, <sup>7</sup>Clinic for oncology, Clinical Centre Nis, Niš, <sup>8</sup>Faculty of Medicine, University of Belgrade, <sup>9</sup>Clinic for Haematology, Clinical Centre of Serbia, Belgrade, Serbia

**Background:** Splenic lymphomas comprise a wide array of diseases, whose clinical behavior spans from indolent to highly aggressive. This is paralleled by the high degree of heterogeneity in the lymphoid populations of their origin. However, the presenting clinical and pathologic features of these diseases often display significant overlaps. The present study is a retrospective review of splenic lymphomas diagnosed in two tertiary referral Clinical Centers in Serbia during a three year period, from January 2015 to January 2017.

**Principals/Methodology:** A 43 cases of splenic lymphomas were selected from the pathologic files and archives. The retrospective study included slides and blocks of all cases. Detailed morphological and immunophenotypic examination using a wide panel of antibodies was performed, combined with the bone marrow biopsy, and clinical examination. Classification was made based on the results of the complete tests of all selected splenic lymphoma specimens in accordance to WHO classification of tumors of haematopoietic and lymphoid tissues (2016).

**Results:** In 43 analyzed cases, the male to female ratio was 1.2:1, and the mean age was 59.6 years (range 21-77 years). All patients presented with variable degree of splenomegaly. Laboratory examination showed increased percentage of lymphocytes in peripheral blood in 17 cases (39.5%). The clinical symptoms included abdominal pain or distension, fatigue, fever, and weight loss. By histopathologic classification, diffuse large B cell lymphoma (DLBCL) was detected in 37.2%, (16/43), splenic marginal zone lymphoma (SMZL) in 34.9% (15/43), splenic diffuse red pulp small B-cell lymphoma (SDRPL) in 9.3% (4/43), mantle cell lymphoma (MCL) in 7% (3/43), follicular lymphoma (FL) in 7% (3/43); one case was small lymphocytic lymphoma (SLL), and one hairy cell leukemia (HCL), 2.3% (1/43), respectively. Bone marrow biopsy was performed in all cases, and the involvement by tumor was found in 22 cases (51.2%). Elevated



LDH level was significantly associated with aggressive histological type ( $p < 0.01$ ), but not with bone marrow involvement.

**Conclusion:** Precise pathologic diagnosis of splenic lymphoma requires tight conjunction of clinical and haematological scrutiny, and gross features, however the principal and decisive parameters are cell morphology, immunohistochemistry, sometimes supplemented by molecular findings.

**References:**

Bairey O, et al. *Cancer* 2015;121(17):2909-16.  
 Shimono J, et al. *Br J Haematol* 2017;178(5):719-27.  
 Arcaini L, et al. *Blood* 2016;127(17):2072-81.

LYS-P-65

## Primary classic Hodgkin Lymphoma in unusual sites

Howayda S. Abd El All<sup>1,2</sup>

<sup>1</sup>Pathology, Suez Canal University, Faculty of Medicine, Ismailiya, <sup>2</sup>IHC lab, Nasser Institute, Cairo, Egypt

**Background:** Classic Hodgkin lymphoma (CHL) primarily involves nodes while extranodal CHL (ENCHL) is extremely rare.

**Principals/Methodology:** ENCHL cases diagnosed between June 2004 and March 2018 were retrieved. Exclusion criteria were previous history of CHL, presence of nodal or splenic lesions and immunosuppression. Diagnosis was based on Revised 2016 WHO lymphoma classification. Immunohistochemistry (IHC) was done for pancytokeratin, CD30, CD15, CD20, CD3, EMA and ALK-1.

**Results:** ENCHL represented 0.4% of all CHL. The average age is 32.8 years compared to 43.7 for CHL. There is no sex predilection. The main histologic finding is the presence of fibrosis associated with scattered elongated atypical cells with hyperchromatic nuclei and inflammatory cells, entering in the differential diagnosis of non hematolymphoid neoplasms. Table 1 illustrates the study findings.

# cases	Clinical presentation	Subtype
2 cases	Vertebral osteolytic lesions	MC
2 cases	Vertebral osteolytic lesions and extraosseous masses	MC
3 cases	Paravertebral masses	MC
1 case	Thymectomy	NS
3 cases	Breast masses	2 MC, 1LR
1 case	Left orbital mass	LR
2 cases	Hepatic focal lesions	MC
1 case	Left laryngeal wall mass	MC

-/+ 5% positive, \* 25% positive MC: mixed cellularity, NS: nodular sclerosis, LR: lymphocyte rich

Table 1: Clinico-pathologic findings

**Conclusion:** two important points are concluded; first, the importance of suspecting CHL in extranodal sites and second, what are the common factors favoring CHL cells proliferation in these unusual sites and their relation to the nodal microenvironment? An important question needing further studies.

**References:**

1. Doweiko et al. *J. Clin. Oncol.* 22 : 4227-4228, 2004
2. Van Bydenstein et al. *Clin. Case Rep.* 2: 88-92, 2014
3. Luo et al. *Oncol Lett.* 9: 677-680, 2015

LYS-P-66

## Risk of malignant neoplasms of blood and lymphatic system of liquidators of the Chernobyl accident in Belarus

Ilya Veyalkin<sup>1</sup>, Andrei Cheshyk<sup>2</sup>

<sup>1</sup>Laboratory Epidemiology, <sup>2</sup>Chernobyl Registry, Research Center for Radiation Medicine and Human Ecology, Gomel, Belarus

**Background:** The accident at the Chernobyl nuclear power plant was the most huge radiation and ecological catastrophe. About 100,000 Belarusian citizens took part in the liquidation of the Chernobyl accident. During the first years after the accident, the growth of incidence of malignant neoplasms of blood of the affected population was predicted. But till now, there is no clear conclusion about the contribution of the radiation factor to the incidence of leucosis and lymphomas. The purpose of the study was to analyze the features of forming the incidence of malignant neoplasms of the blood and lymphatic system of the liquidators of the Chernobyl accident in the Republic of Belarus.

**Principals/Methodology:** The data of the Chernobyl State Register of persons exposed to radiation following the Chernobyl catastrophe for the period from 1987 to 2015 were used (99 498 liquidators). The epidemiological analysis of the incidence of leukemias, lymphomas and multiple myeloma was made using the standardized incidence ratio (SIR). Liquidators were analysed by sex, age at time of the disaster, year of work, duration of staying in contaminated area, density of radiation contamination and individualized dose in bone marrow.

**Results:** The excess of incidence of leukemias in the cohort of liquidators of the Chernobyl accident was noted. The excess fraction of leukemias was about 20–40 % (SIR = 1.3 (1.2–1.46)). It was shown that the high risk of leukemia was formed due to chronic lymphocytic (SIR = 1.3 (1.14–1.53)) and myelocytic (SIR = 1.7 (1.35–2.03)) leukemias regardless of the status of a liquidator. There was also no clear dependence between the risk of hemoblastosis and the density of contamination, as well as the individualized absorbed dose on the blood marrow. However, it can be stated that a large proportion of cases of multiple myeloma (32 %) was found in the liquidators who performed their work in the territory with the Cs137 pollution density of more than 40 Ku/km<sup>2</sup> (SIR = 1.8 (1.16–2.8)).

**Conclusion:** The conducted research allowed to characterize the risks of development of various forms of hemoblastosis in liquidators and to show trends in the distribution of incidence of certain their forms.



LYS-P-67

## Identifying the types of Non-hodgkin Lymphoma

Arooj Fatima<sup>1</sup>, syed sammar abbas Zaidi<sup>2</sup>

<sup>1</sup>SKMC & RC, <sup>2</sup>wecare medical centre, Lahore, Pakistan

**Background:** Our study aims to assess the treatment and outcome of children with biopsy proven Hodgkin Lymphoma and discuss various factors which leads to the poor outcome as compared to developed countries.

**Principals/Methodology:** A retrospective study was done in Shaukat Khanum Research Hospital, Lahore from December 2015 to December 2016. Data regarding age, stage, histopathology, treatment, outcome and impact of delayed presentation were collected and analyzed. Patients were treated ABVD Regimen.

**Results:** Total 150 patients were analyzed with age ranging from 2 to 15 (80% < 12yrs) were included. M: F Ratio was 8:1. 86% patients presented with advanced stage and only 21/150 (14%) had stage II at presentation. The histopathological examination showed Mixed Cellularity in 76 /150, Nodular Sclerosis in 32/150, Lymphocytic Predominance in 15 (10%) and Lymphocytic Depletion in 4/150 cases. Whereas 23/150 reports did not specify the subtype. Bone marrow was involved in 90 (60%) patients. Total 49/150 have completed treatment, 52/150 are on treatment, 25/150 left against medical advice (LAMA) and 24/150 expired due to sepsis and progressive disease.

**Conclusion:** Survival is not fair as 24/150 expired. Mortality of 36% can be reduced by early diagnosis and aggressive infection- control strategies to combat complications. In developing countries, late referrals are strongly associated with metastatic disease. The prognosis can significantly be improved by public awareness to seek early treatment and establishing safe and effective shared care oncology pathways, multidisciplinary team approach. By providing strong social support, intense psychosocial counselling and efficiently run Day Care Oncology, patients compliance can be improved significantly.

LYS-P-68

## NFATc1 and tumor micro environment in diffuse large B cell lymphoma

Krisna Murti<sup>1</sup>, Muslina Muslina<sup>1</sup>

<sup>1</sup>Anatomic Pathology, Faculty of Medicine University of Sriwijaya, Palembang, Indonesia

**Background:** Diffuse large B cell lymphomas (DLBCL) ranks at first among malignancy of B cell lymphomas. Interaction of tumor cells with tumor microenvironment (TME) leads to progressivity of malignancy. M2 macrophages (CD163+) and PDL-1 are known as components of TME. Nuclear factor of activated T cell (NFATc1) is an important transcription factor in physiologic mechanisms of several cell types and in pathogenesis of certain diseases including malignant transformation and progression. Therapeutic strategies were fast developed, yet, still preventive attempts and efforts to decrease its morbidity and mortality is unsatisfied, therefore, new markers for prognosis of the patients is necessary. This study was aimed to investigate NFATc1 roles in progressivity of DLBCL through the modulation of tumor microenvironment.

**Principals/Methodology:** Thirty-two paraffin blocks were selected then immunostained for expression of NFATc1, MYC, PDL-1 and CD163. Clinopathologic data i.e. ages, gender, and proliferation index Ki-67 were obtained. Data was analysed with hierarchical cluster analysis by using SPSS version 16.

**Results:** Male patients (59%) were slightly more than women (41%). Subjects were mostly under 60 years (66%) with nodal location was slightly higher (56%). All DLBCL cases in this study were non-GCB type. MYC overexpression was more among younger patients (69%). Patients with Ki 67 expression more than

70% were among 59% DLBCL. MYC overexpression was confirmed in 55% of DLBCL. Positive expression of CD163 and NFATc1 were among 55% and 45% of cases respectively. PDL-1 expression was not found in all cases. Positive expression of NFATc1 was higher in younger patient (69%). Positive expression of CD163 was detected higher in males (69%) and in younger patients (63%). Clustering analysis demonstrated that CD163 and PDL-1 were clustered together with ages, gender and locations. This may imply density of CD163 and PDL-1 in this malignancy was influenced by ages, gender and location. These findings may indicate that NFATc1 might facilitate progressivity of DLBCL non-GC type through modulation of M2 macrophages among younger male patients. It may suggest markers for DLBCL non-GC type classified into 3 groups which may become panels for prognosis of DLBCL, i.e. CD163 and PDL-1, Ki-67 and MYC, and NFATc1 alone.

**Conclusion:** NFATc1 alone may not be used for prognosis factor of DLBCL. However, it may be a useful marker among certain variants of DLBCL or may be included in a panel together with other markers.

LYS-P-69

## Presence of Epstein-Barr Virus and Lack of Existence of Simian Virus 40 Deoxyribonucleic Acid Sequences in Paraffin Embedded Tissue of Diffuse Large B cell Lymphoma Cases in Yogyakarta Indonesia

Nungki Anggorowati<sup>1</sup>, Wahyu T. Widayati<sup>1</sup>, Nugira Dinantia<sup>1</sup>, Restanti A. Novitasari<sup>1</sup>, Dewajani Purnomosari<sup>2</sup>, Kartika Widayati<sup>3</sup>, Indrawati FNU<sup>1</sup>

<sup>1</sup>Anatomical Pathology, Faculty of Medicine, Universitas Gadjah Mada/Sardjito Hospital, <sup>2</sup>Histology and Cell Biology, Faculty of Medicine, Universitas Gadjah Mada, <sup>3</sup>Internal Medicine, Faculty of Medicine, Universitas Gadjah Mada/Sardjito Hospital, Sleman, Indonesia

**Background:** Epstein-Barr Virus (EBV) oncogenesis mechanism in Diffuse Large B cell Lymphoma (DLBCL) is not fully clarified. However, several studies have shown that the expression of EBV-encoded latent genes contributed to the malignancy. Simian Virus 40 (SV 40) is known to induce malignancies, especially Non-Hodgkin Lymphoma through the role of large T-antigen (L-Tag). The study of EBV and SV40 in Indonesian lymphoma cases is still limited. Thus, the aim of this study was to detect the presence of EBV and SV 40 genomes in paraffin embedded DLBCL tissue in Yogyakarta Indonesia.

**Principals/Methodology:** A total of 102 DLBCL formaline-fixed, paraffin-embedded (FFPE) tissue specimens available were collected from cases classified as DLBCL confirmed by CD20 immunohistochemistry. Epstein Barr Nuclear Antigen 1 (EBNA1), Epstein Barr Nuclear Antigen 2 (EBNA2) and Latent Membrane Protein 1 (LMP1) genes of EBV and Large T antigen (L-tag) of SV40 were examined by polymerase chain reaction (PCR) techniques.

**Results:** DNA was successfully obtained in 62 (60.8 %) of 102 specimens. The total frequency of EBNA1, EBNA2, and LMP1 DNA sequences positive were 8 (12.9%), 4 (6.5%), and 2 (3.2%) respectively. Of those, two samples were positive for both EBNA1 and EBNA2, and only one sample was positive for those three EBV genomes examined. There were no association between EBV genome positivity and clinical data such as age, gender, stage and site. No evidence was detected in SV 40 L-tag genomes.

**Conclusion:** EBV genomes were detected in low to moderate rate in paraffin embedded tissue DLBCL specimens in Yogyakarta Indonesia. SV 40 might not play a role in the oncogenesis of DLBCL in Yogyakarta Indonesia.



LYS-P-70

## Gluteal-implant associated anaplastic large cell lymphoma: a case report and proposal for a new terminology

Flávia Zacchi<sup>1</sup>, Jussara Castelli<sup>1</sup>, Mônica Stiepcich<sup>1</sup>, José Mendes Jr<sup>2</sup>, Vinícius Maykeh<sup>2</sup>  
<sup>1</sup>Pathology, Fleury Group, São Paulo, <sup>2</sup>Brazilian Society of Plastic Surgery, Sorocaba, Brazil

**Background:** We report a case of a 63 yo woman with bilateral buttock cosmetic augmentation with oval texturized silicone implants 12 years before. She noticed a progressive left-buttock volume increase in the past 2 years, after receiving an intramuscular injection.

**Principals/Methodology:** The ultrasound revealed a large seroma in the left buttock. The right buttock was preserved. Both implants were surgically removed and, on the left side, a capsulectomy was performed. Additionally, 800mL of a serous yellowish liquid containing abundant grumes was collected.

**Results:** Cytological preparations showed atypical intermediate and large lymphoid cells, with pleomorphic nuclei, sometimes multilobulated or in a horseshoe form with abundant cytoplasm. The intra-capsular grumes and the capsulectomy were processed. The capsule sections exposed dense connective tissue bands dissociated by a moderate lymphoplasmacytic inflammatory infiltrate, with frequent histiocytes, fibroblastic proliferation and areas. The inner surface was irregularly covered by fibrin deposits, permeated by large and atypical lymphoid cells, without infiltration of the capsule in multiple sections evaluated. These atypical cells showed the morphologic feature similar to the cytologic preparation, with large nucleoli. There were also atypical lymphoid cells in the yellowish fibrinoid clumps. The immunophenotyping of the atypical cells showed positivity for CD30 (strong membranous expression and dot pattern), CD4, Granzyme B, TIA-1 and negativity for ALK-1, CD20, CD2, CD3, CD5, CD7, CD8, AE1AE3, CD68 and S100. Therefore, the diagnosis of anaplastic large cell lymphoma (ALCL) based upon the feature of CD30 positive "hallmark cells" was reported. The patient was referred to a hematologist evaluation. CT was performed, with no nodal or any other extranodal site found.

**Conclusion:** Up to present, this seems to be the first description of peri-implant-associated ALCL located in the gluteal region. However, according to the WHO classification, this provisory entity arises primarily in association with breast implants, apparently not including the possibility of its occurrence in other sites. Considering the increasing number of silicone implants in sites other than that in breasts, peri-implant-associated ALCL is suggested as a more comprehensive terminology to be used to identify/classify this entity.

### References:

1. WHO Classification of Tumours of Haematopoietic and Lymphoid Tissues. Swerdlow SH, et al. 2017
2. Ferrufino-Schmidt M, et al. Am J Surg Pathol 2018;42:293–305

LYS-P-71

## Cyclin D1 expression in lymphoproliferative neoplasms by flow cytometry and immunohistochemistry

Shano Naseem<sup>\*1</sup>, Alaknanda Walia<sup>1</sup>, Man U. Sachdeva<sup>1</sup>, Neelam Varma<sup>1</sup><sup>1</sup>Hematology, Pgimer, Chandigarh, India

**Background:** Cyclin D1 is a protein which regulates cell cycle progression and among lymphoproliferative neoplasms (LPN)- mantle cell lymphoma (MCL) have been reported to express cyclin D1. In this study we investigated the incidence of cyclin D1 expression in LPN and multiple myeloma (MM) cases. The cyclin D1 expression was studied and compared by two separate techniques immunohistochemistry (IHC) and flow cytometry (FCM).

**Principals/Methodology:** A total of 52 patients were studied, which included 40 cases of LPN and 12 cases of MM. For IHC- cyclin D1, was studied using- clone EP12, from Dako, Denmark and for FCM- cyclin D1, was studied using -clone G124-326, FITC labelled, from BD Biosciences, USA.

**Results:** Of 52 patients studied there were 37 (69%) males and 16 (31%) females. The study consisted of 20 cases of chronic lymphocytic leukemia (CLL), 4 cases of MCL, 2 cases of follicular lymphoma (FL), 6 cases of hairy cell leukemia (HCL) and 8 cases of other LPN; and 12 cases of MM.

Expression of cyclin D1 was seen in 3/4 (75%) cases of MCL and in 2/12 (17%) cases of MM - by both IHC and FCM. In HCL cases, IHC showed positivity for cyclin D1 in 2/6 (33%) cases, however, the FCM was negative (this could be due to diluted sample for FCM). None of the other LPN showed positivity for cyclin D1 by both the techniques.

**Conclusion:** This study showed that amongst the LPN, expression of cyclin D1 was most frequent in MCL. Cyclin D1 expression was also seen in few cases of HCL and MM. These findings are concordant with previous reports. IHC showed better results for cyclin D1 staining than FCM. IHC has an advantage over FCM, in terms of a more representative biopsy sample and also that it can be done in retrospective cases.

LYS-P-72

## Evaluation of the Role of Interleukin-6 and Hepcidin in Anemia in Patients with Lymphoma

Alauldeen M. Z. Alqasim<sup>\*1</sup>, Yusur F. Bdaiwi<sup>2</sup><sup>1</sup>Pathology, University of Mustansiriyah / Faculty of Medicine, <sup>2</sup>Teaching Laboratories, Medical City, Baghdad, Iraq

**Background:** Anemia is a common feature in lymphoma. IL-6 is shown to induce hepcidin synthesis by liver. Its overproduction will lead to iron limited erythropoiesis by decreasing intestinal iron absorption and decrease iron release from macrophage.

Hepcidin bind to the cell membrane iron exporter ferroportin and induce its internalization and degradation, thus decreasing iron release from macrophage, and enterocyte.

**Principals/Methodology:** Forty patients with newly diagnosed lymphoma were selected from the haematology outpatient clinic at the medical city, during the period from July 2016 to December 2016. Diagnosis based on morphology and immunophenotyping by either flowcytometry or immunohistochemistry Ann - Arbor staging system was used for clinical staging. Peripheral blood sample of 5ml was withdrawn from each patient and transferred to EDTA tube. Complete blood count was done by automated analyser. The concentration of hepcidin and IL-6 were investigated by ELISA assay.



**Results:** The mean age of lymphoma patients in this study was  $43.6 \pm 20.2$  years with range of (14-79) years. Twenty four of them were males and 16 were females. M:F ratio was 1.5:1

29 patients were anemic with Hb less than 12(g /dL).

21 patients had stage IV disease (52.5%)

7 patients had stage III disease (17.5%)

12 patients had stage II disease, (30%)

IL-6 and hepcidin level were much higher in lymphoma Patients than control group. There was significant inverse relationship between IL-6 and hepcidin with Hb level. There was significant +ve correlation between IL-6 with B-symptom, Bulky disease and stage of the disease. There was significant positive relationship between hepcidin level with the presence of B-symptoms and stage of the disease.

**Conclusion:** IL-6 and hepcidin level were much high in lymphoma patients compare to healthy control. IL-6 and hepcidin level were significantly higher in lymphoma patient with anemia than not anemic patients. The adverse impact of elevated IL-6 is consistent with demonstration of higher level of IL-6 in patients with advanced stage of disease, bulky disease, and B-Symptoms. The adverse impact of elevated hepcidin is consistent with demonstration of higher level of hepcidin in patients with advanced stage and B-symptoms.

**References:**

Marcus R, Sweetenham JW, Williams ME, editors. Lymphoma: pathology, diagnosis and treatment. 1st ed. UK:Cambridge 2007;3-37. Gantz T. Hepcidin, a key regulator of iron metabolism and mediator of anemia of inflammation. Blood. 2003; 102(3):783-788.

LYS-P-73

## The expression of Human Telomerase Reverse Transcriptase gene and its activity in patients with B-Cell chronic lymphocytic leukemia and its impact on clinical staging.

Ali Aljabban<sup>1</sup>, Jaffar Alalsaidissa<sup>1</sup>

<sup>1</sup>Department of Pathology, Baghdad College of Medicine, Baghdad, Iraq

**Background:** The B-Cell chronic lymphocytic leukemia is a commonest leukemia in elderly individuals characterized by progressive accumulation of mature lymphocyte in bone marrow and peripheral blood that tend to be immortal. Due to the disease heterogeneous, we are still in need for markers to predict the disease behavior in patients. The identification of human telomerase reverse transcriptase (hTERT) has been correlated with disease aggressiveness in malignancies.

**Principals/Methodology:** we used the TRAP assay to assess the hTERT gene expression in mononuclear blood cells from 43 B-CLL patients

**Results:** The hTERT gene expression was detected in 79.1% of B-CLL patients and no positive expression in control group (P=0.001). The hTERT gene expression tends to be significantly higher in advanced B-CLL stage (P=0.0001). Also, the expression was higher among elderly patients, patients with lower hematological parameters, patients with splenomegaly or hepatomegaly, patients with a history of hypertension or diabetes mellitus, and patients with high immunophenotype score.

**Conclusion:** our research suggests that the hTERT expression could serve as a prognostic marker for B-CLL patients.

LYS-P-74

## Enhancer of zeste homolog 2 (EZH2) expression and its association with MYC regulation in follicular lymphoma as a prognostic biomarker.

Anna Szumera-Cieckiewicz<sup>1,2</sup>, Kamil Sokoł<sup>1,2</sup>, Maria Chraszczewska<sup>1,2</sup>, Anita Jastrzebska<sup>3</sup>, Grzegorz Rymkiewicz<sup>3</sup>, Urszula Wojciechowska<sup>3</sup>, Joanna Didkowska<sup>3</sup>, Ewa Paszkiewicz-Kozik<sup>3</sup>, Jan Walewski<sup>3</sup>, Monika Prochorec-Sobieszek<sup>1,2</sup>

<sup>1</sup>*Diagnostic Hematology Department, Institute of Hematology and Transfusion Medicine*, <sup>2</sup>*Department of Pathology and Laboratory Medicine, Maria Skłodowska-Curie Memorial Cancer Center and Institute of Oncology*, <sup>3</sup>*Maria Skłodowska-Curie Memorial Cancer Center and Institute of Oncology, Warsaw, Poland*

**Background:** Enhancer of Zeste Homolog 2 (EZH2) which is a catalytic subunit of polycomb repressive complex 2 is a silencer of the target genes in tumorigenesis. EZH2 inhibitors are one of the most studied histone-modifying enzymes for the personalized treatment of hematological malignancies. EZH2 overexpression and hyperactivity have been found in the pathogenesis i.e. breast, prostate, endometrial, diffuse large B-cell lymphomas. It has been depicted that EZH2 overexpression correlates with more aggressive clinical behavior and poor overall outcome. EZH2 mutational load in follicular lymphoma has been analyzed recently but EZH2 protein expression is still not fully described. The aim of the study was characteristics of EZH2 and MYC protein status in follicular lymphoma in contexture of surveillance.

**Principals/Methodology:** FL cases from 1999 to 2017 were reevaluated according to WHO 2017 diagnostic recommendations including histological grading and immunohistochemical (IHC) panel. From formalin fixed paraffin embedded lymphoma samples the tissue microarrays were constructed (1 mm cylinders from three different and representative areas). Immunohistochemical assessment of EZH2 (Ventana, SP129, RTU) and MYC (Abcam, 32072, 1:100, pH 9.0) was performed. The scoring methods included only strong nuclear reaction with cut-off points: EZH2  $\geq 70\%$  and MYC  $\geq 5\%$ , as described previously. Correlation with EZH2 and MYC status with overall survival and initial clinical data characteristics were evaluated.

**Results:** Group of 88 FL was enrolled into study with male to female ratio 30:58 and median age 61.5 years (range: 28-93 years, SD=15.7). Distribution of histological grade was: 68 (77.3%) low (1/2) vs. 20 (22.7%) high grade (3a/3b). EZH2 was expressed in 34.1% of all FL cases with strong predilection to the high-grade cases [3a/3b FL in EZH2(+) vs. EZH2(-) group were 36.7% vs. 15.5% respectively]; over 70% of EZH2(+) cases were also MYC(+). EZH2 overexpression was significantly associated with reduced overall survival rate ( $p=.001$ ) and MYC expression ( $p=.003$ ).

**Conclusion:** EZH2 protein is overexpressed in 34.1% of FL and strongly correlates with higher histological grade, MYC expression and poor overall survival. The presence of an EZH2 overexpression may be used as a surrogate of EZH2 mutational status and may be considered as a first line selection of patients for targeted EZH2 inhibitor therapies.

## Plasmablastic lymphoma, a single center experience on 22 cases

Nazan Özsan<sup>1</sup>, Derya Demir<sup>1</sup>, Ayse Uysal<sup>2</sup>, Mahmut Tobu<sup>2</sup>, Mine Hekimgil<sup>1</sup>

<sup>1</sup>Department of Pathology, <sup>2</sup>Department of Hematology, Ege University Faculty of Medicine, Izmir, Turkey

**Background:** Plasmablastic lymphoma (PBL) is a rare and aggressive non-Hodgkin lymphoma often associated with Epstein Barr virus (EBV) infection. The diagnosis can be challenging because the neoplastic cells are negative for the commonly used B and T cell specific antigens. The aim of this study was to evaluate the clinical, morphological, immunohistochemical features and prognosis of PBL cases diagnosed in our institution, in view of the literature.

**Principals/Methodology:** We retrieved all the cases diagnosed as PBL between 2006-2018 in our center. All cases were reviewed and 22 cases with fulfilling the diagnosis were studied thoroughly.

**Results:** Among 22 cases 17 were male (77%), 5 (23%) were female. Mean age was 60.3 years (range:19-76); the youngest patient, 19 years old, was a posttransplant lymphoma case; except for this young case, the age range was between 41-76. Two of the cases were liver transplant receivers, 10 of the cases had been assessed for HIV serologically, none had HIV infection. The most commonly involved sites were nasal cavity and paranasal sinuses (n=7), lymph nodes (n=3), gastrointestinal tractus (n=3) and bone (n=3), spleen (n=2), tonsil, soft tissue, skin and testis. 62% of cases were EBV (EBER) positive. 90% of cases had no determined cause of immunodeficiency. Two (9%) of the patients were transplant recipients and alive with 98 and 125 months' follow up periods. 67% of cases were found to have positivity immunohistochemically in more than 50% of the neoplastic cells. The mean overall survival was 41 months (0-125); on follow-up period up to 12 years, 14 cases were alive, and the total mortality rate was 36.3%.

**Conclusion:** The mean overall survival was longer in our series, compared to literature; posttransplant 2 cases had better survival time. Myc and EBV status have been linked to prognosis in some studies, but we had not found a significant difference. PBL is a rare and hard to diagnose type of lymphoma. For the correct diagnosis, a wide spectrum of immunohistochemistry and correlation with laboratory and clinical findings are necessary. Because of its rarity, more studies are needed worldwide in order to define the standard treatment options and criteria for prognosis appropriately.

### References:

1. Morscio J, et al. Clinicopathologic comparison of plasmablastic lymphoma... Am J Surg Pathol. 2014;38:875-86.
2. Castillo JJ, et al. The biology and treatment of plasmablastic lymphoma. Blood. 2015;125:2323-30.
3. Harmon CM, et al. Plasmablastic Lymphoma... Arch Pathol Lab Med. 2016;140:1074-8.

LYS-P-76

## A case of primary central nervous system histiocytic sarcoma with prominent proliferation of histiocytic cells between the trabeculae of reactive glial cells

Emiko Takahashi<sup>1</sup>, Shigeo Nakamura<sup>2</sup><sup>1</sup>Department of Surgical Pathology, Aichi Medical University Hospital, Nagakute, <sup>2</sup>Department of pathology, Nagoya University Hospital, Nagoya, Japan

**Background:** Histiocytic sarcoma (HS) is an extremely rare malignant neoplasm that exhibits morphologic and immunophenotypic evidence of histiocytic differentiation. The disease most commonly involves the lymph node, gastrointestinal tract, skin, and soft tissue, with presentation in the central nervous system (CNS) being relatively rare. Here we report a unique case of primary CNS HS with unusual histological characteristics, namely the prominent proliferation of histiocytic cells between the trabeculae of reactive glial cells.

**Principals/Methodology:** To clarify the nature of this case, the histological, immunophenotypic, molecular features of the case were investigated.

**Results:** A 65-year-old woman presented with CNS HS in the left frontal region, showing two distinct histological patterns. Approximately half of the lesion displayed histological characteristics typical of HS, including diffuse infiltration of large round-to-ovoid pleomorphic cells, with mitotic figures (Ki67 labelling index: 30%) and coagulative necrotic foci. The other half exhibited prominent proliferation histiocytic cells proliferation between the trabeculae of reactive glial cells, with rare mitotic figures (Ki67 labelling index: <1%) and no necrotic foci. There were transitions between two morphologies. The HS tumour cells and the histiocytic cells between the trabeculae of reactive glial cells possessed nearly identical histomorphologic and immunophenotypic features, although the HS tumour cells showed a more pronounced degree of cytologic atypia and mitotic activity. PCR analysis did not reveal IgH or TCRy rearrangement. FISH detected no translocation involving the BCL2 locus. Direct sequencing did not show any BRAF<sup>V600E</sup> mutations or PIK3CA mutations, and PCR-rSSO results showed no RAS mutations.

**Conclusion:** To our knowledge, this is the first reported case of HS with prominent proliferation of the histiocytic cells between the trabeculae of reactive glial cells. Although the relationship between these two histological patterns is unclear, the histiocytic cell proliferation might be a low-grade or a precursor lesion. Investigating cases of HS may provide insight into the pathogenesis of this disease.

LYS-P-77

## The brain and the lymphoma – not so uncommon friendship

Tihomir Dikov<sup>1</sup>, Milan Jagurinoski<sup>1</sup>, Yavor Topalov<sup>1</sup>, Branimir Spassov<sup>2</sup>, Gueorgui Balatzenko<sup>3</sup>, Margarita Guenova<sup>1</sup><sup>1</sup>Laboratory of Hematopathology and Immunology, <sup>2</sup>Hematology Clinic, <sup>3</sup>Laboratory of Cytogenetics and Molecular Biology, National Specialised Hospital for Active Treatment of Hematological Diseases, Sofia, Bulgaria

**Background:** Central nervous system (CNS) lymphoma accounts for less than 1% of all non-Hodgkin lymphomas and around 2-3 % of all brain tumors. Although clinically diverse in presentation, they all tend to share similar dismal prognosis, can affect any age and current therapy options are less than adequate to cope with the disease. This could be attributed to heterogeneous tumor biology and genetic make-up.



**Principals/Methodology:** Archival data were retrieved from our hospital's database. A five-year (2013-2018) retrospective analysis was conducted based on all cases recovered. We could identify a total of 37 patients either only diagnosed or diagnosed and treated in our institution.

**Results:** Demographics disclosed an almost 4:3 female:male ratio (n=21 females; n=16 males). Age range varied from 49 to 80 years, with a median age of 63,5. Thirty-three cases were signed out as Diffuse large B-cell lymphoma (89.2%), two were initially described as Marginal-zone lymphomas (5,4%) and two – small cell non-Hodgkin lymphomas without further clarification (5,4%).

Out of the 33 DLBCLs, 15 received treatment in our hospital making them eligible for additional analysis. According to the CNS International Prognostic Index 7 patients were classified low risk, 7 patients were intermediate- and 1 was high risk. In only 2 patients additional extranodal sites were involved (lung in 1 patient and spleen in 1 patient). Blood cell counts were within reference ranges for hemoglobin and platelets except 1 with anemia and 1 with mild thrombocytopenia, while 4 patients showed moderate leukocytosis up to  $16.5 \times 10^9/l$ ; mean  $\beta_2$ -microglobuline values were 3.3 mg/l (range 1.2-11.0 mg/l).

Immunohistochemistry (IHC) revealed CD20 positivity in all cases as well as bcl2 and MUM1/IRF4, while bcl6 was found in 12 cases. Bcl2/bcl6/MUM1 triple positivity represented the majority of CD10 negative cases. CD10 was found in 3 cases, CD5 in 4, CD30 in one. Ki-67 immunolabeling varied from 30-95% (mean 65%).

**Conclusion:** CNS lymphomas are rare, diverse in terms of cell of origin/microenvironment/clinical presentation, but still some traits can be readily identified by using simple everyday IHC algorithms. Recent studies suggest MYD88/CD79b molecular testing as predictive assay to clarify intrinsic cell signaling abnormalities but still should be compared head to head with morphology and conventional IHC.

LYS-P-78

## Prognostic role of MAPK/ERK signal pathway alterations in patients with Langerhans Cell Histiocytosis: Update results

Olga Novosad<sup>1</sup>, Tetiana Skrypets<sup>1</sup>, Ian Pastushenko<sup>1</sup>, Oksana Skachkova<sup>2</sup>, Mariia Inomistova<sup>2</sup>, Olexandr Gorbach<sup>2</sup>, Nataliia Khranovska<sup>2</sup>, Irina Kryachok<sup>1</sup>

<sup>1</sup>Oncohematology, <sup>2</sup>Experimental Oncology, National cancer Istitute, Kiev, Ukraine

**Background:** Langerhans Cell Histiocytosis (LCH) presents as a rare myeloid neoplasm with quite different clinical ranges from multisystem involvement and aggressive forms to early stages or even spontaneous regression. A great breakthrough in molecular landscape have been made by BRAF V600E mutation validation in nearly 60% cases. Although, due to possible activation of MAPK/ERK pathways we need more independent investigations to understand a universal LCH pathology.

**Principals/Methodology:** Detection of 23 mutations in BRAF (V600E), KRAS (12, 13, 61, 146 codons) and NRAS (12, 13, 61 codons) genes were performed by real time PCR analysis using TaqMan Probe-Based Assays (Applied Biosystems, USA). Tissue specimens, obtained in LCH patients before treatment, were selected. This material included >10% tumor infiltrate to avoid technical limitations of PCR method for detecting low abundance single-nucleotide mutations. [Office1] [Office1] DNA was extracted from FFPE tissue samples using Recover All Total Nucleic Acid Isolation Kit (Life Technology, USA).

**Results:** 10 pts (range 21-55, median age 29) were treated in Oncohematology department of NCI (Kyiv, Ukraine). 6 and 4 patients received chemo plus radiation therapy and only chemotherapy, respectively (p<0.05). 8 patients received LCH-I study protocol, six cycles in average and 2 patients were treated by Ara-C.

A BRAF c.1799T>A, p.V600E mutation was detected in 20% (3/10) cases: 1 patient had an early relapse in 6 months and 2 patient - stable disease. We didn't find any of BRAF, KRAS or NRAS mutations in three pts with late relapses (in 15, 24 and 46 months). Notable, that KRAS mutations were not revealed in any LCH samples. The NRAS c.182A>G, p. Q61R mutation was found in two cases: one patient had LCH transformed to Hodgkin's lymphoma; one patient had a refractory disease. Time-to-relapse (TTR) rate in patients with and without BRAF V600E gene mutation was 13 vs 28 months respectively,  $p < 0.05$ . TTR was 31.3 vs 6.41 months in pts with absence and presence NRAS mutation,  $p < 0.05$ . Multivariate analysis showed the presence of NRAS Q61R mutation was association with poor event-free survival in LCH pts with HR of 6.1 [95% (CI) 0.2-12.6,  $p = 0.008$ ].

**Conclusion:** BRAF and NRAS mutations in LCH suggest a possibility of disease occurrence by the activation of the MAPK/ERK pathway. These oncogenic mutations provide new opportunities in understanding LCH pathogenesis and potential target therapy.

LYS-P-79

## Unusual presentation of indolent T-cell lymphoproliferative disorder of the gastrointestinal tract involving full thickness of the colon

Ji Yun Jeong<sup>1</sup>, Jeong Ju Lee<sup>2</sup>, Tae-In Park<sup>3</sup>, Young-Hyeh Ko<sup>4</sup>

<sup>1</sup>Pathology, <sup>2</sup>Surgery, Kyungpook National University Chilgok Hospital, Kyungpook National University, School of Medicine, <sup>3</sup>Pathology, Kyungpook National University Hospital, Kyungpook National University, School of Medicine, Daegu, <sup>4</sup>Pathology, Samsung Medical Center, Sungkyunkwan University School of Medicine, Seoul, Korea, Republic Of

**Background:** Indolent T-cell lymphoproliferative disease (LPD) of the gastrointestinal tract (GIT) is a rare, newly proposed disease entity. This is differentiated from aggressive intestinal lymphoma by its characteristic histologic, immunohistochemical, and molecular findings. It is important to recognize this condition to avoid misdiagnosis and unnecessary treatment.

**Principals/Methodology:** A 63-year-old man presented with thickened wall of the transverse colon with unremarkable mucosa on colonoscopy. A 4 cm wall-thickening lesion was found on computed tomography. The lesion was totally removed by segmental resection of the colon. Histologic examination, immunohistochemical stain, and evaluation for TCR- $\gamma$  chain gene rearrangement were performed.

**Results:** Histologically, dense lymphoid infiltrate nearly all over full thickness of the colon was noted. The lymphoid infiltrate was diffuse but characteristically nondestructive, so normal structures of the colon were preserved. The infiltrates were composed of small, monotonous, mature-looking lymphoid cells and no intraepithelial lymphocytosis was identified. Immunohistochemically, the lymphoid cells were positive for CD3 and majority of the cells were positive for CD8 with a few CD4 positive cells. CD56 was negative and Ki-67 proliferation index revealed very low (<5%). A clonal rearrangement was identified by a study for TCR- $\gamma$  chain gene rearrangement.

**Conclusion:** We report the first case of indolent T-cell LPD of the GIT exceptionally involving nearly full thickness of the colon. The patient has been staying healthy without relapse for the last 5 years.



LYS-P-80

## A case of primary pulmonary extranodal marginal zone lymphoma of mucosa-associated lymphoid tissue with amyloidosis

Toko Miyazaki<sup>1</sup>, Satoshi Ota<sup>2</sup>, Emiko Sakaida<sup>3</sup>

<sup>1</sup>Medicine, <sup>2</sup>Pathology, <sup>3</sup>Hematology, Chiba University, Chiba-ken, Japan

**Background:** Primary pulmonary lymphomas may contain amyloid deposits, but this finding is rare. And there is a little report of this kind of cases. Amyloid more often deposits in the lung independent of lymphoplasmacytic neoplasms, usually in the form of nodular amyloidosis with multiple nodules. We report a case that showed pathological feature of lymphoma and amyloidosis in the lung.

**Principals/Methodology:** A 69-year-old woman has been followed for Sjogren syndrome for 24 years. Multiple bilateral pulmonary nodules were pointed out in chest CT 6 years ago and several nodules increased in size for last 5 years. By FDG-PET, the SUV max was 8.22. There is no obvious lymphadenopathies.

**Results:** For the purpose of pathological diagnosis, partial resection of left upper lobe. In macroscopic findings, two pulmonary white nodules were located just below the pleura. As pathological findings, subpleural and peribronchiolar amyloid deposition was prominent with lymphocytes and plasma cell infiltration. Kappa dominant light chain restriction by ISH was observed in infiltrated plasma cells.

**Conclusion:** Based on the above, pulmonary nodules were diagnosed as the extranodal marginal zone lymphoma of mucosa-associated lymphoid tissue with amyloid deposition. Then treatment with RTX was started. In the literature, primary pulmonary B-cell lymphomas with amyloid nodules was extremely rare.

### References:

Kalpadakis C, Ahamad A, et al. Non-gastric extra-nodal marginal zone lymphomas - a single center experience on 76 patients. *Leuk Lymphoma*. 2008; 49: 2308-15

M.M. Picken et al. Amyloid and Related Disorders. *Current Clinical Pathology*. 2015.

Sanja Dacic et al. Nodular Amyloidoma and Primary Pulmonary Lymphoma with Amyloid Production: A Differential Diagnostic Problem. *Mod Pathol*. 2000;13: 934-940

LYS-P-81

## Transfusion associated complications during bone marrow transplantation in Diffuse Large B – Cell Lymphoma patients

Ambreen Sheikh<sup>1</sup>, Syed A. Ali<sup>2</sup>

<sup>1</sup>Pathology, DUHS, <sup>2</sup>A and E, Dr Ziauddin Hospital, Karachi, Pakistan

**Background:** Lymphoma represents one of the major health problems all over the world. The most common and the most aggressive type of Non Hodgkins lymphoma (NHL) is Diffuse Large B cell Lymphoma (DLBCL). The incidence of DLBCL in Asia has increased in the last few decades, being the 4th most common cancer in males, about 6.1%.

**Principals/Methodology:** DLBCL patients were recruited from outpatient department of cancer hospital from Malir a suburb area of Karachi. Most of the patients among them are the candidates for BMT. Out of them 24 were previously transfused patients (A) and 21 newly diagnosed patients (B). Blood also collected from healthy blood donors for leukodepletion and stored for 41 days for testing the additive solutions. pRBC of each donor were divided equally into 4 bags containing a different AS. Bags were stored for 41 days at 4°C and evaluated every 10 days. Variables analyzed included pH, PCV, and% he-

molysis, and lactate, glucose, potassium, sodium, ATP, and 2,3- diphosphoglycerate (2,3-DPG) concentrations. Blood samples (500ml) from group A and B were collected into 70 mL of citrate-phosphate-dextrose (CPD) solution each. Detection of platelet specific IgG antibodies were performed with solid phase red cell adherence assay (SPRCA) on both groups. In order to have 80% power we demonstrated with 95% confidence ( $P < .05$ ) with 5% chances of error. Statistical analysis was performed with a two- tailed Fisher's exact test. For screening of CMV specific IgG antibodies. We compared the obtained value with the cutoff value 0.543. Pearson Chi-Square test was used for statistical analysis

**Results:** We found 20 positive from group A (83.3%) and 3 from group B (14.2%). While, during the storage of leukodepleted blood, pH, and glucose, 2, 3-DPG, and ATP concentrations decreased, and hemolysis, and lactate, sodium, and potassium concentrations increased ( $P < .05$ ). Significant differences between AS were seen in the glucose and sodium concentrations. Also, the pH maintained by PAGGGM at day 21 was significantly higher than that seen with SAGM or Adsol.

#### Prevalence of platelet alloimmunization in DLBCL patients

group	positive	total	%age	p value <0.1
A	14	24	58.33	
B	1	21	4.76	

#### Prevalence of CMV igG>0.543 in transfused DLBCL patients

group	positive	total	%age	p value <0.01
A	20	24	83.3	
B	3	21	14.2	

**Conclusion:** Leucodepletion is suggested to prevent PR for future candidates for BMT to reduce their complications. We suggested SAGM to use an AS with leukodepleted blood because of its easy availability and low cost comparatively.

#### Image:

	SAGM					ADSOL					OPTISOL					PAGGGM				
Days	1	12	22	32	42	1	12	22	32	42	1	12	22	32	42	1	12	22	32	42
pH	7.27	7.33	7.08	7.02	7.09	7.28	7.31	7.10	6.9	7.10	7.30	7.34	7.15	7.0	7.05	7.22	7.39	7.1	7.0	7.1
Hemolysis(%)	0.30	0.64	0.67	1.13	1.31	0.31	0.59	0.74	0.9	1.19	0.25	0.63	0.69	0.0	1.42	0.27	0.66	0.6	0.1	1.2
Lactate (mmol/L)	6.06	13.7	22.4	26.0	26.9	6.22	13.6	20.4	27.	29.4	6.26	12.7	20.7	23.	25.7	6.50	13.5	20.	26.	28.
Glucose (mg/dl)	520	371	441.7	410.7	372.5	1176.	145	130	126	122	532.3	397.	449.	41	389.	491.	350.	39	33	30
ATP (mmol/g Hb)	3.08	3.03	2.00	1.02	0.50	3.26	3.62	1.93	1.1	0.53	2.45	2.77	1.96	0.7	0.29	3.31	4.06	2.4	0.9	0.3
2,3DPG (μmol/g Hb)	19.8	16.9	13.7	8.43	4.25	20.0	19.0	13.6	10.	6.21	16.81	16.7	13.3	6.9	3.66	18.0	17.0	15.	10.	7.7
Na <sup>+</sup> (μmol/L)	144.	148.	145.8	150.0	150.5	143.1	152.	153.	153	153.	145.3	150.	147.	15	151.	115.	114.	12	11	11
K <sup>+</sup> (mmol/L)	3.13	4.45	3.96	4.09	4.15	3.04	4.23	4.00	4.0	4.13	3.16	4.26	4.05	4.1	4.20	2.79	3.74	3.8	3.8	3.9



LYS-P-82

## Prolonged clinical remission after rituximab treatment in cases of acquired angioedema

Petros Fessas<sup>1</sup>, Sanja Ugrinovic<sup>2</sup>, Ariharan Anantharachagan<sup>2</sup>, Dinakantha S. Kumararatne<sup>2</sup>

<sup>1</sup>*School of Clinical Medicine, University of Cambridge,* <sup>2</sup>*Department of Clinical Biochemistry, University of Cambridge, Cambridge, United Kingdom*

**Background:** Acquired angioedema (AAE) is caused by secondary complement C1 inhibitor (C1INH) deficiency, and is characterised by recurrent swelling affecting any tissue, and often leading to abdominal pain. AAE may be a consequence of autoantibodies to C1INH produced by a B cell clone associated with a lymphoproliferative disorder (LPD). Supporting this are described cases that have been treated with the anti-CD20 monoclonal antibody rituximab, which depletes B-cell populations, although clinical response is not always directly reflected in the immunological response. We report 5 cases of rituximab-treated acquired angioedema in patients with LPD, focusing on our ability to monitor clinical response with biochemical parameters.

**Principals/Methodology:** We report 5 unselected cases (mean age = 64.2) of AAE treated with rituximab from 2013 to 2016, and discuss our ability to monitor AAE through the immunological parameters typically assessed: paraprotein, C4 levels, C1INH levels. The LPD diagnoses were Waldenström's macroglobulinaemia (n=2), diffuse large B-cell lymphoma (n=2), and splenic marginal zone lymphoma. Mean biochemical follow up was 29.6 months, and mean clinical follow up was 34 months. The rituximab regimen and the concomitant use of danazol was not controlled across the cases. All patients were prescribed icatibant as a rescue medication.

**Results:** 2 of our cases showed clinical response to rituximab while C4 and C1INH levels remained below normal, and 3 of our cases showed clinical response and improvement in C1 INH levels, while C4 levels remained below normal.

**Conclusion:** In 4 cases, paraprotein is maintained below the detectable limit after rituximab; an undetectable amount may still be able to lower C1INH levels and produce abnormalities in C4 levels without clinical symptoms. In 1 case, paraprotein levels remain abnormal - rituximab may suppress the autoantibody-producing clone of plasma cells but still permit a detectable level of paraprotein secretion that keeps C4 and/or C1 INH levels below normal; however, acute reductions in C1 INH levels are avoided, leading to a reduction of angioedema attack frequency.

Our small sample cannot comment on the significance of clinical response to rituximab in AAE, but adds to the published literature. However, our cases are characterized by a discordance between clinical and laboratory observations. This is an area that would benefit from further research with larger cohorts and prospective study design.

LYS-P-83

## Extranodal NK/T-cell lymphoma of the small intestine in a pediatric patient

Xiayuan Liang<sup>1</sup>, Adam C. Wilberger<sup>2</sup> and University of Colorado School of Medicine, Children's Hospital Colorado

<sup>1</sup>Pathology, University of Colorado School of Medicine, Children's Hospital Colorado, <sup>2</sup>Pathology, University of Colorado School of Medicine, Aurora, United States

**Background:** Extranodal NK/T-cell lymphoma (EN-NKTL), nasal type is more prevalent in Asians and the indigenous populations of Mexico, Central and South America. It occurs most often in adults, frequently involves the upper aerodigestive tract, and is strongly associated with EBV. EN-NKTL is uncommon in Western countries, the pediatric population, and the lower gastrointestinal system. We present a pediatric case to illustrate an uncommon manifestation of this rare neoplasm.

**Principals/Methodology:** Histologic review with immunophenotypic and genetic studies and clinicopathologic correlation.

**Results:** A 14-year-old Native American male presented with fever and constant abdominal pain for 2 months. He had a 2-year history of recurrent bacterial and EBV infections, decreased energy, and episodic fevers after tonsillectomy due to streptococcus infection. He was pale and had a 10-pound weight loss over 2 months. Laboratory tests showed elevated LFTs and low Hb and platelets. A CT scan revealed multiple small renal masses and small bowel wall thickening. A segmental resection of the small bowel was performed and showed focal mucosal ulceration with diffuse infiltrate of submucosa, lamina propria, and muscular layer by a population of polymorphic neoplastic lymphoid cells ranging from small to intermediate to large in size. Mitosis were seen. Tumor cells were positive for CD2, CD3, CD5, CD7, CD8, granzyme B, and EBER. FISH analysis demonstrated gain of 2p23 (ALK) DNA sequence. PCR revealed  $\gamma$ -TCR gene rearrangement. Bone marrow and CSF were negative. The patient received chemotherapy and achieved complete remission for 12 years.

**Conclusion:** 1. EN-NKTL is more frequent in but not limited to the Native American population in the United States. 2. Occurrence of EN-NKTL in a lower gastrointestinal (GI) location is uncommon and should be included in differential diagnosis of GI lymphomas. 3. EN-NKTL is generally highly aggressive with poor outcome, but it appears to carry better prognosis in pediatric patients than adults.

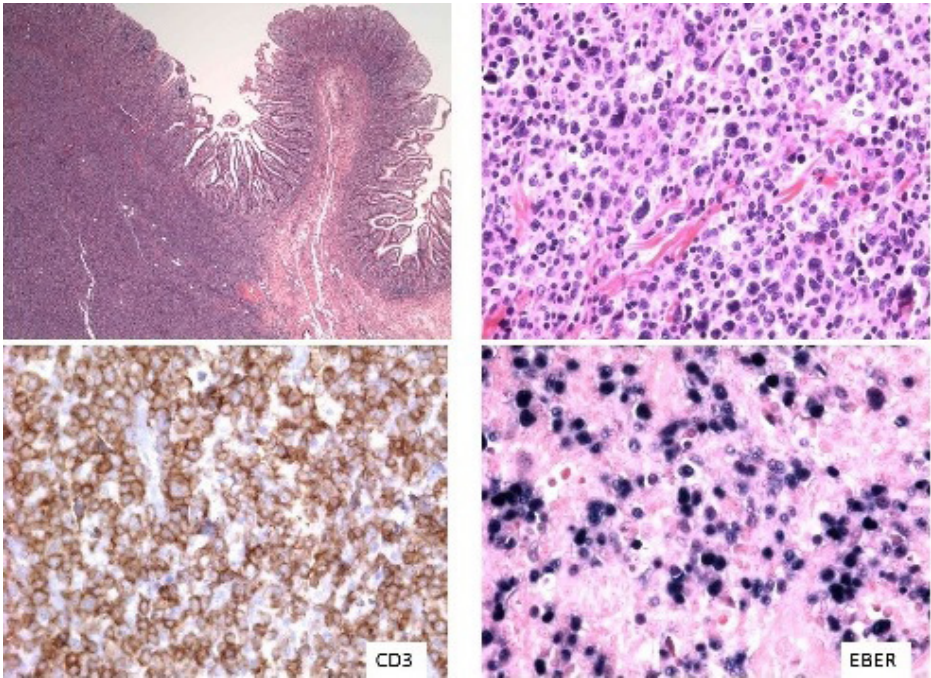
### References:

1. Frank MC1, Bono E, Sun T. An unusual case of peripheral T-cell lymphoma with CD56 positivity and angiocentric, angiodestructive morphology arising in the ileum. Arch Pathol Lab Med. 2005 Apr;129(4):527-30.

2. Swerdlow SH, Campo E, Harris NL, et al, editors. WHO Classification of Tumours of Hematopoietic and Lymphoid Tissues. Revised 4th ed. Lyon, France: IARC; 2017.



**Image:**



LYS-P-84

**Leukemic presentation of Anaplastic large cell lymphoma, ALK-positive: report of a case and brief review of literature.**

Jussara B. Castelli<sup>1,2</sup>, Flavia Zacchi<sup>2</sup>, Matheus Gonçalves<sup>3</sup>, Alex Sandes<sup>3</sup>, Yana Novis<sup>4</sup>, Maria de Lourdes Chauffaille<sup>3</sup>

<sup>1</sup>Pathology, Hospital das Clínicas - FMUSP, <sup>2</sup>Pathology, <sup>3</sup>Hematology, Grupo Fleury, <sup>4</sup>Hematology, Hospital Sírio-Libanês, Sao Paulo, Brazil

**Background:** The Anaplastic large cell lymphoma (ALCL), both ALK-positive and ALK-negative, is a lymphoproliferative disorder with usual dissemination and extranodal involvement. WHO recognizes some histologic patterns of ALCL. However, only rare cases of the small variant are reported with markedly atypical lymphocytes at peripheral blood smears.

**Principals/Methodology:** We report a 25-yo male presented a 15-day history of fever and rapidly progressive lymphocytosis in peripheral blood (almost  $77 \times 10^9/L$ ) with atypical small to medium sized lymphoid cell and marked irregular chromatin, whose immunophenotyping by flow cytometry indicated 18% of small to intermedite cells expressing CD30, CD45 and CD7, suggesting a leukemic anaplastic large cell

lymphoma. He also showed a rapid growing and painful inguinal lymph node (2.5 cm). The PET scan presented high capture in multiple intrabdominal, mediastinal and tonsillar lymph nodes as well as in the spleen, in addition to less intense uptake in the axial skeleton.

**Results:** The histology of the inguinal lymph node shows almost total substitution by large lymphoid cells, exhibiting increased and irregular nuclei, with irregular contours, rare of them with kidney-shape aspect and abundant cytoplasm and frequent mitosis. These cells occupy the sinuses and the paracortical region diffusely. The immunohistochemistry analysis showed positivity for CD30 (strong expression in the membranes and dot pattern), ALK-1, CD43, CD4, EMA, TIA-1 and Granzyme B, weak positivity for CD45 and CD7, leading to diagnosis of ALCL-ALK positive.

The bone marrow biopsy showed about 15% interstitial infiltrate of isolated atypical lymphoid cells, CD30 and ALK-1 positive. The cytogenetic study revealed 45,X,-Y,t(2;5)(p23;q35),add(4)(p16),-14,+mar[12]/46,XY[8]. Genomic alterations found at FoundationOne<sup>®</sup> were ALK NPM1-ALK fusion, CUX1 splice site 64-1G>A, FANCA F1263del, NPM1 truncation intron 4 e SDHA R554Q. Despite partial response to chemotherapy at first, disease progressed and he died three months after diagnosis.

**Conclusion:** The leukemic presentation of ALCL is aggressive and quite uncommon - we found only 29 patients reported. This presentation has been considered of unfavorable prognosis. Because of its rarity, the diagnosis can be difficult and delayed, and it should be based on immunofenotyping features through immunohistochemistry and flow cytometry.

**References:**

1. WHO Classification Tumours of Haematopoietic and Lymphoid Tissues. Swerdlow SH, et al. 2017.
2. Grewal JS, et al. *Ann Hematol* (2007) 86:499–508.

LYS-P-85

## Non-Hodgkin lymphoma secondary to Hodgkin lymphoma in an Adult Patient with Nijmegen Breakage Syndrome

Julia Slotta-Huspenina<sup>\*1</sup>, Krischan Braitsch<sup>2</sup>, Tibor Vag<sup>3</sup>, Ulrich Keller<sup>2</sup>

<sup>1</sup>Institute of Pathology, <sup>2</sup>Internal Medicine III, School of Medicine, <sup>3</sup>Department of Nuclear Medicine, School of Medicine, Technical University of Munich, Munich, Germany

**Background:** Nijmegen Breakage Syndrome (NBS) is a rare autosomal recessive DNA repair disorder characterized by microcephaly, growth and mental retardation, immunodeficiency, radiation hypersensitivity and increased incidence of hematologic malignancies. NBS is described by a 5-bp deletion on exon 6 in the NBN gene, leading to expression of an insufficiently functioning protein nibrin. Nibrin forms a complex with MRE11 and RAD50 that is involved in processing DNA double strand breaks. Thus, dysfunctional nibrin leads to impaired cellular DNA damage response. Consequently, NBS patients harbor an increased risk of developing malignancies and are extremely vulnerable to ionizing radiation. So far, mostly pediatric patients have been described since NBS is often fatal before adulthood.

**Principals/Methodology:** Combined (F-18)-Fluorodeoxyglucose PET/MRI was used for staging as conventional PET/CT was contraindicated due to the underlying DNA repair disorder. FDG-uptaking tumor tissue was extirpated for histopathological examination.

**Results:** We here describe a 29-year-old male patient who had been diagnosed with NBS at birth and registered in the NBS registry (patient No. 45). In 2011 the patient was diagnosed with stage IV classical Hodgkin Lymphoma (cHL) and treated with a tailored regimen of chemotherapy resulting in complete remission (CR). In 2016 the patient was admitted to our hospital with cervical and supraclavicular lymphadenopathy, dyspnoe, fever and weight loss of 15 kg in six month. PET/MRI showed masses in the left



hemithorax, the mediastinum and supraclavicular lymph node bulks. Biopsy revealed a diffuse large B-cell lymphoma (DLBCL). The patient's history of severe infectious complications and organ failure during previous treatment for cHL in addition to the highly increased risk of subsequent secondary malignancies due to genotoxic chemotherapy, led us to decide on an attenuated R-CHOP regimen. After 6 cycles of chemotherapy, PET/MRI showed CR according to the Lugano criteria. Follow-up after 3, 6, 9 and 12 months continued to show the patient in CR. Under extended antibiotic, antiviral and antifungal prophylaxis, no major complications occurred.

**Conclusion:** To our best knowledge we here describe the first adult NBS patient with a NHL secondary to a successfully treated cHL. We demonstrate that PET-MRI in addition to application of an individualized regimen of chemotherapy under extended prophylaxis can help to achieve CR in lymphoma patients with a DNA repair disorder.

LYS-P-86

## Clinico-histomorphological correlation of Epstein Barr Virus in Hodgkin's Lymphoma

Preeti Rani<sup>1</sup>, Mili Jain<sup>2</sup>, A.K. Tripathi<sup>3</sup>, Ashutosh Kumar<sup>4</sup>

<sup>1</sup>Junior resident, Department of Pathology, <sup>2</sup>Assistant professor, Department of Pathology, <sup>3</sup>Professor, Department of Clinical haematology, <sup>4</sup>Professor, Department of Pathology, King George Medical University, Lucknow, India

**Background:** Association of Hodgkin's lymphoma (HL) and Epstein Barr Virus (EBV) has been evaluated by several studies. But the effect of EBV on various clinico-histomorphological factors and treatment outcomes of HL has not been well evaluated.

**Principals/Methodology:** The objective of this study was to evaluate the prevalence of EBV in HL and to correlate it's presence with various clinico-histomorphological parameters and treatment response.

88 histopathological and immunohistochemistry (IHC) (CD15, CD30) proven cases of HL were enrolled in the study. Presence of EBV was confirmed by IHC for EBV Latent Membrane Protein 1 (LMP1) and polymerase chain reaction (PCR) analysis. EBV presence and its association with various clinico-histomorphological factors (age, gender, clinical stage, extra-nodal involvement, bone marrow involvement, capsule thickness, nodule formation, residual follicle, sclerotic bands, stromal sclerosis, coagulative necrosis, granuloma, Reed Sternberg cell's atypia & clusters and inflammatory infiltrates) and the treatment response (by In-POG protocol) were evaluated.

**Results:** EBV positivity was seen in 87.14% and 100% in patients of NS and MC respectively on either IHC or PCR or both. A higher proportion of EBV negative cases presented at an earlier clinical stage but the association was not statistically significant. No significant association was found between EBV status and various clinico-histomorphological parameters and treatment response.

**Conclusion:** A high proportion of EBV positivity indicates pathogenic role in HL. No significant association of Epstein Barr Virus status was seen with various clinico-histomorphological parameters and treatment response.

### References:

- von Wasielewski S, Franklin J, Fischer R, Hübner K, Hansmann ML, Diehl V, Georgii A, von Wasielewski R. Nodular sclerosing Hodgkin disease: new grading predicts prognosis in intermediate and advanced stages. *Blood*. 2003 May 15;101(10):4063-9.
- Mahajan A, Kalra M, Dinand V, Arora R, Jain S, Chandra J. A Collaborative Protocol For Newly Diagnosed Indian Childhood Hodgkin Lymphoma Patients. *Pediatric Blood & Cancer*. 2015 Nov 1;62:S312-3.

LYS-P-87

## EBV-positive NK/T-cell lymphoma, associated with chronic active EBV infection: A case report

Ji Yun Jeong<sup>1</sup>, Jeong Ju Lee<sup>2</sup>, Tae-In Park<sup>3</sup>, Young-Hyeh Ko<sup>4</sup>

<sup>1</sup>Pathology, <sup>2</sup>Surgery, Kyungpook National University Chilgok Hospital, Kyungpook National University, School of Medicine, <sup>3</sup>Pathology, Kyungpook National University Hospital, Kyungpook National University, School of Medicine, Daegu, <sup>4</sup>Pathology, Samsung Medical Center, Sungkyunkwan University School of Medicine, Seoul, Korea, Republic Of

**Background:** Chronic active Epstein-Barr virus (EBV) infection (CAEBV) of T-cell or NK-cell type is a rare and strongly racial predisposed systemic EBV-positive lymphoproliferative disorder which shows systemic symptoms of varying degrees. The prognosis of CAEBV is variable, with some cases following an indolent clinical course and others showing rapid progression and aggressive course. A subset of aggressive cases can progress to NK/T-cell lymphoma.

**Principals/Methodology:** A 16-year-old boy has shown skin symptoms including fever, skin bullae, necrotic change, and scar formation after insect or mosquito bite since childhood. A year ago, he presented abrupt and transient right sided paresthesia. Multiple cystic lesions throughout thoracic spines were found on MRI. The boy presented a mass accompanied by skin necrosis and swelling on his right upper arm recently. Excision of the mass was performed. Additional neurologic symptoms including left facial palsy and both horizontal nystagmus were appeared during the evaluation for the skin symptom with suspicions for viral infection or vasculitis, and pons infarction was identified on a brain MRI. Serologic tests, histologic examination, immunohistochemical stain, EBV in situ hybridization, and study for TCR chain gene rearrangement were performed.

**Results:** Serum total IgE was highly elevated by 18520 IU/mL. EBV IgM was negative, but IgG to viral capsid antigen of EBV were elevated by 556 U/mL and EBV viral load were  $8.27 \times 10^5$  copies/mL. Histologically, biopsy from the mass on his arm showed polymorphic atypical lymphoid infiltration located mainly in peri-vascular area and peri-adnexal area with extensive necrosis. Immunohistochemically, the atypical lymphoid cells were positive for CD3, TIA1, and granzyme B, but negative for CD20 and CD56. Numerous EBV-positive cells were identified on the EBV in situ hybridization. TCR $\gamma$ , TCR $\delta$ , TCR $\beta$  gene rearrangement showed polyclonal pattern.

**Conclusion:** We report a case of EBV-positive NK/T-cell lymphoma in an Asian boy with a long history associated with CAEBV. CAEBV is easy to miss in case which shows mild degree of initial clinical symptoms. A close examination with in-depth history taking and strong suspicion for CAEBV is important to diagnose and treat this disorder on time.



LYS-P-88

## A Case Report of Myeloproliferative Neoplasms Following Treatment of Myeloid Sarcoma Presenting as Spleen and Splenic lymph node tumors.

Megumi Nakanishi<sup>1</sup>\*, Satoshi Ota<sup>2</sup>, Masahiro Takeuchi<sup>3</sup>, Yuri Kawashima<sup>4</sup>, Nobuyuki Aotsuka<sup>4</sup>, Emiko Sakaida<sup>3</sup>, Yukio Nakatani<sup>2</sup>

<sup>1</sup>Chiba Univ., Chiba prefecture, Japan, <sup>2</sup>Dept. Pathol., <sup>3</sup>Dept. Hematol., Chiba Univ., <sup>4</sup>Dept. Hematol., Japanese Red Cross Society Hosp., Chiba prefecture, Japan

**Background:** Myeloid sarcoma (MS) is defined as a myeloproliferative disorder that forms an extramedullary mass composed of myeloblasts or immature granulocytic cells. It is also known to be discovered prior to the onset of acute myelogenous leukemia (AML) or constitute acute blastic transformation of MDSs, myelodysplastic/myeloproliferative neoplasms (MDS/MPNs), or myeloproliferative neoplasms (MPNs). Although it is reported that MS is observed at almost any site in the body, it is difficult to diagnose unless it is not kept in mind at the time of pathological diagnosis. Also, it is unusual to track the progress of MPN after MS treatment. We report a case of an atypical example of MPN following MS treatment.

**Principals/Methodology:** A 66-year-old male presented with abdominal mass. Computed tomography (CT) scans revealed hepatosplenomegaly and abdominal lymph node enlargement.

Fluorodeoxyglucose-Positron Emission Tomography(FDG-PET) showed no superficial lymph node enlargement but it showed standardized uptake value(SUV)-max 3.7 accumulation in spleen and intraperitoneal lymph node and bone marrow.

Physical examination showed high peripheral blood eosinophils(21%) and increase of eosinophils in ascites. Splenectomy and lymphoidectomy were performed for diagnostic purposes. Myeloblasts in the bone marrow were below 4% and bone marrow infiltration was not observed.

**Results:** In the spleen and splenic hilar lymph node, diffuse proliferated blastoid cells was observed in the white pulp region of spleen and interfollicular lesion. As a result of immunohistochemical examination, CD117, CD68, CD13, CD33 were positive, Ki-67 index was higher than 50%, and it was diagnosed as myeloid sarcoma.

At bone marrow biopsy performed after remission induction therapy, fibrosis of bone marrow and increase of megakaryocytes were observed.

**Conclusion:** Based on the pathological diagnosis, 2 times remission induction therapies were performed. Unexpectedly, an increased myoblasts was observed by peripheral blood examination, leading to hematological non-remission. Additional bone marrow biopsy was diagnosed as prefibrotic primary myelofibrosis by frequent dense immature megakaryocyte clusters.

JAK2, CALR, MPL mutation were not detected. In this case study, we experienced the case that prefibrotic PMF became remarkable after treatment of MS in spleen.

### Reference:

Swerdlow SH, et al. eds.WHO Classification of Tumours of Haematopoietic and Lymphoid Tissues. Lyon, IARC ; 2008.

LYS-P-89

## Non-Hodgkin lymphoma simulating carcinoma of the vulvar region: Report of two cases

Daniela E. Dueñas<sup>1,2</sup>, Daniel Enriquez<sup>3</sup>, Luis Taxa<sup>3</sup>, Patricia Webb<sup>3</sup>, Jaime Montes<sup>2</sup>, Carlos Barrionuevo<sup>2</sup>

<sup>1</sup>*Translational Molecular Path, MD Anderson Cancer Center, Houston, United States*, <sup>2</sup>*Instituto de Enfermedades Neoplásicas*, <sup>3</sup>*Instituto de Enfermedades Neoplásicas, Lima, Peru*

**Background:** Two cases of primary non-Hodgkin lymphoma of the vulva are reported. The first corresponded to 82-year old woman who showed a 6-cm vulvar injury, whose pathological diagnosis was diffuse large-cell lymphoma B, germinal center B-cell type. She received R-MiniCHOP with partial response. The second case corresponded to 35-year old woman showing an extensive vulvar ulcerated injury of 10 cm with pathological diagnosis of extranodal NK/T-cell lymphoma, nasal type with T-cell cytotoxic phenotype (EBER+), with CD56 expression and loss of CD8 expression. The T phenotype was determined by the study of genetic rearrangements for the T-cell receptor, which was monoclonal. The patient received the SMILE and GELOX treatments with low response and disease progression.

**Principals/Methodology:** Immunoperoxidase staining was in an automated immunohistochemistry (IHC) equipment (Autostainer Link48, Dako). In addition, Epstein-Barr-virus-encoded RNA in situ hybridization was performed, EBER.

**Molecular analysis:** The TCR products were analyzed in a capillary electrophoresis instrument (Genetic Analyzer 3500, Applied Biosystems, Carlsbad, California, USA).

### Results:

Case 1: The immunophenotype was CD20+, BCL-2+, CD10+, C-MYC+, BCL-6-, MUM1-, with Ki67 around 90%.

Case 2: The immunophenotypic was CD3+, CD56+, CD30+, TIA1+, GRANZYME-B+, CD4-, CD8-, with Ki67 around 80% and EBER+. TCR study showed a monoclonal peak.

**Conclusion:** This report's purpose is to highlight two unusual and extremely rare NHL cases in the female genital tract. Since they are quite infrequent on this localization, it is often a diagnosis challenge if this possibility is not considered. These cases should always be assessed by a multi-disciplinary team with specific experience on NHL assessment and management.

LYS-P-90

## Solitary extramedullary plasmacytoma of the liver in a 26-years old woman

Tihomir Dikov<sup>1</sup>, Valentina Madzharova<sup>1</sup>, Gueorgui Balatzenko<sup>2</sup>, Branimir Spassov<sup>3</sup>, Margarita Guenova<sup>1</sup>

<sup>1</sup>*Laboratory of Hematopathology and Immunology*, <sup>2</sup>*Laboratory of Cytogenetics and Molecular Biology*,

<sup>3</sup>*Hematology Clinic, National Specialised Hospital for Active Treatment of Hematological Diseases, Sofia, Bulgaria*

**Background:** Solitary extramedullary plasmacytomas represent approximately 3% of all plasma cell neoplasms. Although a few cases of plasmacytoma of the liver have been reported, a truly localized extramedullary plasmacytoma of the liver are exceptionally rare in the literature affecting mostly elderly patients.

**Principals/Methodology:** We report an unusual case of liver plasmacytoma without systemic disease in a 26-years old woman who presented with jaundice and pain in the right hypochondrium.



**Results:** On admission, the physical exam revealed only palpable hepatosplenomegaly. The initial laboratory tests showed WBC of  $6.1 \times 10^9/l$ , Hb level 111 g/l and PLT  $83 \times 10^9/l$ , total bilirubin 72  $\mu\text{mol/l}$  due to the direct, GGT 288 U/l, LDH 205 U/l, AP 200 U/l, AST 509 U/l, ALT 330 U/l, total protein 112 g/l,  $\beta_2$ -microglobulin 3.5 mg/l. On immunohematological testing, IgG membrane fixed auto anti-erythrocyte antibodies were detected. Monoclonal IgG kappa + free light chain (FLC) kappa were found to be 33,4 g/l. Plasma viscosity was 3.5 mP/s. Lysosomal enzymes ( $\beta$ -glucosidase, acid sphingomyelinase and  $\beta$ -galactosidase) were within reference ranges. CT and MRI imaging did not find any other organ or bone lesions except diffuse hepatic infiltration without well-defined masses. A needle liver biopsy was performed. The histological examination with immunohistochemistry disclosed a diffuse solid monotonous proliferation of monoclonal CD138(+) plasmacytes, which were kappa light chain mRNA (+) on in situ hybridization (ISH), with a few admixed T-lymphocytes. On aspirate smear, the bone marrow was normocellular and less than 10% of plasma cells, polyclonal by light chain mRNA ISH. Flow cytometry did not detect any measurable aberrant population, cytogenetics detected a normal female karyotype 46, XX [17]. Due to the diffuse hepatic infiltration surgical intervention and radiotherapy were not taken into consideration. Four cycles of cyclophosphamide-bortezomib regimen without the corticosteroid component due to hyperreactivity were applied. The follow up 3 years after diagnosis showed stable disease without bone marrow involvement.

**Conclusion:** Only a few cases of primary hepatic extramedullary plasmacytoma have been reported. Up to our knowledge the present case is the youngest patient reported so far. The diagnosis requires the demonstration of a monoclonal plasma cell infiltrate without evidence of multiple myeloma elsewhere.

LYS-P-91

## Sex privileged or site privileged lymphomas, a gender comparison

Tihomir Dikov<sup>1</sup>, Milan Jagurinoski<sup>1</sup>, Yavor Topalov<sup>1</sup>, Branimir Spassov<sup>2</sup>, Gueorgui Balatzenko<sup>3</sup>, Margarita Guenova<sup>1</sup>

<sup>1</sup>Laboratory of Hematopathology and Immunology, <sup>2</sup>Hematology Clinic, <sup>3</sup>Laboratory of Cytogenetics and Molecular Biology, National Specialised Hospital for Active Treatment of Hematological Diseases, Sofia, Bulgaria

**Background:** A variety of lymphomas tend to occur at sites typically defined as privileged, including the male and female gonads. Substantial part of these lymphomas are Diffuse large B-cell lymphomas (DLBCL) with few exceptions.

**Principals/Methodology:** Archival data were retrieved from our hospital database. A five-year (2013-2018) retrospective analysis was conducted based on all cases recovered. We could identify a total of 27 patients with site privileged lymphomas either only diagnosed or diagnosed and treated in our institution.

**Results:** Fifteen female patients underwent surgery for tumor indication in true low pelvis who stood outside of the adenocarcinoma box and were subsequently referred to our institution to rule out lymphoma. Four cases out of all referred were classified as lymphomas – one DLBCL, one Marginal-zone lymphoma and two Follicular lymphomas. Age at diagnosis ranged from 39 to 65 years. Each diagnostic entity was thoroughly supported by generous immunohistochemistry combined with full body imaging. Secondary ovarian dissemination was excluded in 3 cases and only the DLBCL case had diffuse spread over lymph nodes and organs. The two Follicular lymphomas each showed bcl2 positivity that did not correlate with stage and grade.

Twenty-one male patients were diagnosed during the period with primary DLBCL of the testis. Thirteen of them (61,9%) showed CD10 negativity. Bcl2 was positive in 10 cases (47,6%) and bcl6 – in 14 cases (66,6%). Double positivity for bcl2/bcl6 was present in 10 cases (47,6%). MUM1/IRF4 was positive in all cases.

**Conclusion:** The five year analysis showed male predominance in gonad based lymphomas with 84% of cases being males. DLBCL was the most common diagnosis as far as extranodal sites are concerned, though rarely other lymphomas are encountered with diverse phenotypes in regard to GC/non-GC subtypes.

LYS-P-92

## A potential pitfall in lymph node biopsy and cytology: CD30+ ALK- large B-cell “sticky” lymphoma mimicking metastatic carcinoma

Masaru Hosone\*<sup>1</sup>, Satoru Arai<sup>1</sup>, Hironori Katayama<sup>1</sup>, Yumi Yanagida<sup>1</sup>, Norio Yumoto<sup>1</sup>, Zenya Naito<sup>1</sup>  
<sup>1</sup>Pathology, Nippon Medical School, Tokyo, Japan

**Background:** In lymph node biopsy and cytology, atypical cohesive cellular aggregates are basically considered a metastatic lesion, such as poorly differentiated adenocarcinoma. Rare exceptional cases of lymphoma, however, can also demonstrate a “sticky” morphology indistinguishable from metastatic carcinoma, which often misleads the pathologist into an incorrect diagnosis. We report herein a rare case of large B-cell lymphoma showing a confusing morphology mimicking metastatic carcinoma in touch-imprint cytology and histology.

**Principals/Methodology: Case:** A 54-year-old man visited our hospital with a chief complaint of right inguinal lymphadenopathy. Under a preliminary clinical diagnosis of malignant lymphoma, he underwent excisional biopsy of the lymph node and the touch-imprint cytology was also performed.

**Cytological and histological findings:** Papanicolaou staining revealed many cohesive aggregates of large polygonal cells with medium to large atypical lymphocytes distributed in the background. Giemsa staining demonstrated the aggregates with dense and deep basophilic cytoplasm indicating a potential diagnosis of metastatic carcinoma rather than a nodal large/pleomorphic cell lymphoma. In histology, the basic structure of the lymph node was completely effaced and replaced mainly by atypical large polygonal/pleomorphic cells. In the marginal sinuses, sheet-like cell aggregates were easily detected and our primary impression was a metastatic undifferentiated carcinoma. With further multidisciplinary approaches including flow cytometry, immunohistochemistry, chromosomal analysis and electron microscopy, our final diagnosis was a rare variant of diffuse large B-cell lymphoma: CD30+/ALK- pleomorphic large B-cell lymphoma.

**Results:** This case is considered a subtype of diffuse large B-cell lymphoma previously called anaplastic large cell lymphoma of B-cell type (B-ALCL) or B pleomorphic lymphoma. This subtype often shows epithelioid cohesive aggregates of tumor cells in the marginal sinuses of lymph node typically observed in cases of metastatic carcinoma. Conventional ALCL of T/null cell type and rare ALK+ large B-cell lymphoma (WHO 2008) are also known to demonstrate the similar findings and can even show cytokeratin positivity.

**Conclusion:** Although our case is a rare subtype, it is a potential pitfall, however, in a daily pathology practice and this variant should be also included in a list of differential diagnoses of “metastatic carcinoma” in lymph node cytology.



LYS-P-93

## Autoimmune Lymphoproliferative Syndrome: suspected diagnosis from the lymph node biopsy of a child with generalized lymphadenopathy

Flávia Zacchi<sup>1</sup>, Jussara Castelli<sup>1</sup>, Vaneska Jardini<sup>2</sup>, Matheus Gonçalves<sup>3</sup>

<sup>1</sup>Pathology, Fleury Group, São Paulo, <sup>2</sup>Hematology, CTFM/GACC, São José dos Campos, <sup>3</sup>Hematology, Fleury Group, São Paulo, Brazil

**Background:** We report a case of a 2 years old Japanese's descendent boy with chronic generalized lymphadenopathy, splenomegaly and thrombocytopenia.

**Principals/Methodology:** CBC showed anemia and thrombocytopenia (WBC:  $10.3 \times 10^9/L$ , lymphocyte 47%). Serological tests for HIV, HBsAg, HCV, CMV, EBV, Toxoplasmosis and Rubella were negative. A cervical chain with 22 lymph nodes was resected (largest lymph node – 1,6 cm).

**Results:** Lymph node sections revealed preserved architecture with spaced B follicles and prominent paracortical expansion characterized by intermediate T cells proliferation positive for CD3, CD5, CD7, CD43, double negative (DNT) for CD4 and CD8, 70-80% proliferative index, interspersed tingible body macrophages and discrete plasmacytosis. TdT, CD30, CD15, ISH-EBV, CD10, CD34, CD1a, ALK1, TIA-1 and Granzyme B were negative. Therefore, a suspected diagnosis of Autoimmune Lymphoproliferative Syndrome (ALPS) was reported, with recommendation for further clinical investigation. Hypergammaglobulinemia and elevated vitamin B12 were found. Peripheral blood immunophenotyping showed 6,8% of CD3-positive CD4/CD8 DNT lymphocytes expressing TCR-alpha-beta. A probable diagnosis of ALPS was rendered, and the patient remains well under treatment with continuous corticotherapy, until nowadays. Subsequent evaluation of two lymph nodes were performed and, in both, the immunohistologic findings presented the same characteristics as the first biopsy.

**Conclusion:** ALPS is a rare genetic disorder of lymphocyte apoptosis leading to accumulation of CD4/CD8 DNT cells, that causes childhood onset chronic lymphadenopathy, splenomegaly, cytopenias, and increased risk of B-cell lymphoma. It is related to mutations in FAS (most frequently), FASLG or CASP10. As the typical immunohistologic findings are considered as secondary criteria for its diagnosis, pathologists should be aware of this possibility, avoiding misinterpretation of the cases, considering the most frequent differential diagnosis, including T cell lymphomas in some cases, with massive infiltration of lymph nodes, spleen and bone marrow by DNT cells.

### References:

1. Bleesing JJH, et al. Autoimmune Lymphoproliferative Syndrome. 2006. In: Adam MP, et al., editors. GeneReviews [Internet]. Seattle (WA): University of Washington, Seattle; 1993-2018.
2. Oliveira, JB et al. Revised diagnostic criteria and classification for the autoimmune lymphoproliferative syndrome (ALPS): report from the 2009 NIH International Workshop. Blood 2010; 116(14), e35-e40.

LYS-P-94

## Nodular lymphocyte predominance Hodgkin lymphoma (NLPHL) or T cell rich B cell lymphoma (TCRBCL), a diagnostic challenge.

Howayda S. Abd El All<sup>1,2</sup><sup>1</sup>Pathology, Suez Canal University, Faculty of Medicine, Ismailiya, <sup>2</sup>IHC lab, Nasser Institute, Cairo, Egypt

**Background:** The 2016 revised lymphoma classification is based on combination of clinical and radiologic data/ morphology/ immunohistochemistry (IHC) and molecular studies. However, some difficult cases show overlapping features, a challenging approach especially in countries where the facilities of molecular studies are sometimes unavailable.

**Principals/Methodology:** This case is a male, 27 years old, presenting with constitutional symptoms, weight loss, fever, and generalized lymphadenopathy. Cervical lymph nodes and bone marrow trephine biopsies were performed. Patient died shortly after the diagnosis.

**Results:** One node showed effaced architecture by vague nodules formed of scattered Hodgkin cells positive for CD20 and EMA and negative for CD30 and CD15 in a lymphoid background formed of an equal number of reactive B and T cells (photo 1). The second node showed proliferation of a larger number of CD20 cells and the background is mainly formed of T cells (photo 2). In the third node, all the background cells are of T cells, surrounding neoplastic CD20 lymphocytes (photo 3). The bone marrow had two populations, T cell rich like population (photo 4a) and sheets of diffuse large B cell lymphoma (photo 4b).

**Conclusion:** This case represents the progression of a NLPHL (classic type A)\* into nodular with T-cell rich background (type D)\*, TCRBCL like pattern (type E)\*, to diffuse large B cell lymphoma in the bone marrow. Does this case is a truly NLPHL or is a TCRBCL presenting initially as NLPHL like disease? This hypothesis is based on the clinical presentation and the rapid evolution of the disease.

### Reference:

\*Fan et al., Am J Surg Pathol 2003

LYS-P-95

## Flow cytometric Immunophenotyping of Peripheral T cell Neoplasms in Yemen

Saleh Abuhadi<sup>1</sup>, Wendy Erber<sup>2</sup><sup>1</sup>Flow cytometry, National Oncology Center, Sana'a, Yemen, <sup>2</sup>Faculty of medicine, The University of Western Australia, Perth, Australia

**Background:** Flow cytometric immunophenotyping plays an important role for diagnosis and classifications of postthymic T cell neoplasms in leukemic phase.

**Principals/Methodology:** We assessed the immunophenotypic profile of 4 cases of PTCNs that presented over three years using a single laser FACSCaliber flow cytometry. CD45/side scatter gating was used to identify the leukemic cells. Antibodies used were to surface and intracellular antigens including CD45, CD34, CD19, CD10, CD20, CD25, CD1a, CD2, CD3, CD4, CD5, CD7, CD8, TdT and CD56. Antibodies were conjugated with FITC, PE and PerCP fluorophores.

**Results:** Of 100 cases chronic lymphoproliferative disorders, 4 cases (4%) were diagnosed as peripheral T cell neoplasms; two cases were Sezary cell leukemia (CD2, CD3 and restricted CD4); one case T-large granular leukemia (CD2, CD3, CD5 with restricted CD8); one case hepatosplenic T cell lymphoma (CD2 and CD3 with dual negative CD4 and CD8)



The median age was 57 years (range 22 to 65) with a male: female ratio of 3:1.

**Conclusion:** Peripheral T cell neoplasms are a rare neoplasm in Yemen. The panel of antibodies used was successful for the classification of PTCNs.

LYS-P-96

## Intravascular large B-cell lymphoma with relapsing postchemotherapy, treated by stem cell transplant

Ayumu Tsubosaka<sup>1</sup>, Satoshi Ota<sup>2</sup>, Tatsuzo Mishina<sup>3</sup>, Chikako Ohwada<sup>3</sup>, Yusuke Takeda<sup>3</sup>, Emiko Sakaida<sup>3</sup>, Yukio Nakatani<sup>1,2</sup>

<sup>1</sup>Dep. of Diagnostic Pathol., Chiba Univ. Grad. Sch. of Med., <sup>2</sup>Dep. of Pathol., <sup>3</sup>Dep. of Hematol., Chiba Univ. Hosp., Chiba, Japan

**Background:** Intravascular large B-cell lymphoma (IVLBCL) is a relatively rare type of diffuse LBCL characterized by the selective growth of neoplastic cells only within the lumen of capillaries, and with the exception of larger arteries and veins. Diagnosis is often difficult, and the prognosis is poor. Patients may present with various symptoms, with any tissue potentially being infiltrated.

**Principals/Methodology:** The case is 57-year-old man who developed abdominal distension and fatigue. The examination showed the elevation of LDH, sIL-2R, the decrease of platelet, liver injury, splenohepatomegaly, ascites. No enlargement of lymph node was observed. In bone marrow aspiration and random skin biopsy including senile angioma, atypical lymphocytes were found in capillaries and diagnosed as IVLBCL, stage IVA. After chemotherapy, remission was achieved. 1.3 years later, the same symptoms occurred, and the relapse was confirmed in the bone marrow biopsy. Treated with peripheral blood stem cell transplant (PBSCT) and the patient has achieved remission without recurrence so far.

**Results:** In the skin and bone marrow specimen, large atypical lymphocytes were observed in capillaries. Immunohistochemically, CD20, CD5 were positive, CD10 were slightly positive, and CD3, Cyclin D1, CD23, EBER-ISH were negative. Ki-67 are highly positive.

**Conclusion:** The stem cell transplant was performed only in limited conditions, but in those cases, the prognosis is better according to some case reports and series. In this particular case, after PBSCT, the recurrence has not occurred so far. We examined pathologically this case and other 8 IVLBCL cases in Chiba University Hospital with literature.

### References:

Dennis E et al. Intravascular Large B-Cell Lymphoma. Arch Pathol Lab Med -Vol 136, March 2012. 333-338  
Maurilio P et al. Definition, Diagnosis, and Management of Intravascular Large B-Cell Lymphoma: Proposals and Perspectives From an International Consensus Meeting. J Clin Oncol 25: 3168-3173.  
Murse T et al. Intravascular large B-cell lymphoma (IVLBCL): a clinicopathologic study of 96 cases with special reference to the immunophenotypic heterogeneity of CD5. Blood, 15 January 2007 109: 478-485.  
J Meissner et al. Autologous hemtopoietic stem cell transplantation for intravascular large B-cell lymphoma: the European Society for Blood and Marrow Transplantation experience. Bone Marrow Transplantation (2017) 52, 650-652: doi: 10.1038

LYS-P-97

## Primary CD5-positive diffuse large B-cell lymphoma of the brain: case report

Daniela E. Dueñas<sup>1,2</sup>, Carlos Pachas<sup>3</sup>, Sandro Casavilca<sup>2</sup>, Enrique Orrego<sup>2</sup>, Carlos Barrionuevo<sup>2</sup>

<sup>1</sup>MD Anderson Cancer Center, Houston, United States, <sup>2</sup>Instituto Nacional de Enfermedades Neoplásicas,

<sup>3</sup>Hospital Central Policia Nacional del Peru, Lima, Peru

**Background:** Most central nervous system lymphomas are associated with the spread of a systemic lymphoma to the CNS. The primary central nervous system lymphoma is an extranodal non-Hodgkin lymphoma (NHL), usually diffuse large B-cell lymphoma (DLBCL); it confines to the brain, leptomeninges, eyes, spinal cord, with no evidence of spreading outside the CNS. Most cases are sporadic, and incidence increases with age. In a subgroup of patients, disease progression is caused by a state of immunosuppression, including HIV infection. Approximately, 5%–10% of nodal and extranodal DLBCL are CD5 positive. CD5+ DLBCL is a clinicopathological variant of DLBCL with an aggressive clinical course and a poor prognosis; it mostly affects elderly patients who present B symptoms, elevated LDH level, extranodal involvement, higher incidence of CNS involvement and advanced clinical stage. Below, we present a case of an immunocompetent patient diagnosed with CD5+ PCNS DLBCL; and describe the histopathological and immunophenotypic clinical findings

**Principals/Methodology:** The brain tissue sample was fixed with 10% buffered formalin. The paraffin blocks were stained with H&E. The immunohistochemical analysis was performed with a DAKO Autostainer Link48 machine.

**Results:** The immunophenotype of the neoplastic cells was CD20+, CD5+, BCL2+, MUM1+, C-MYC+, LMP1 (EBV)-, CD10-, with Ki67 70%.

**Conclusion:** This case would demonstrate the multiple pathways that are altered in these neoplasms, not being exclusive of any specific type. The identification of certain molecular pathways in DLBCL could be used more frequently in the future as a therapeutic target. CD5 determination should be part of the DLBCL diagnosis panel.

LYS-P-98

## Grey zone lymphoma

Chihiro Matsunaga<sup>\*1</sup>, Satoshi Ota<sup>1</sup>, Tatsuzou Mishina<sup>1</sup>, Yusuke Takeda<sup>1</sup>, Chikako Owada<sup>1</sup>, Emiko Sakaida<sup>1</sup>

<sup>1</sup>Chiba university, Chiba-shi, Japan

**Background:** “Grey zone lymphoma” was equivalent to B-cell lymphoma, unclassifiable, with features intermediated between diffuse large B-cell lymphoma and classic Hodgkin lymphoma. Patients have aggressive clinical course and poorer outcome than patients with either CHL or DLBCL. However, there are no consensus on optimum treatment protocol.

**Principals/Methodology:** 20-year-old man who has nothing special as for medical history visited near hospital because he had the main complaint of left supraclavicular lymph node swelling.

On chest CT the anterior mediastinum mass and left supraclavicular lymph node swelling were found therefore he was referred to our hospital.

Left supraclavicular lymph node biopsy was underwent by neck dissection.

**Results:** In dissected 1 cm-sized lymph nodes, prominent fibrosis with lymphoid cell proliferation were observed. Scattered atypical large lymphoid cell with prominent nucleoli resembling Hodgkin cell ad-



mixed with Reed-Sternberg like cells. Immunohistochemistry, CD20, PAX5, CD30, CD15, MUM-1, Bcl-6 were heterologous positive expression. And also CD3, CD5, EBER-ISH were negative.

Both morphology and immunohistochemistry, this tissue presented intermediate between Classical Hodgkin lymphoma and Primary mediastinal large B-cell lymphoma.

**Conclusion:** DA-EPOCH-R therapy have failed to respond completely therefore switched to CHASER therapy. Although lymph node involvement was shrinking tendency, CR was judged to be difficult. For that reason now we are trying BV therapy and autologous peripheral blood stem cell transplantation.